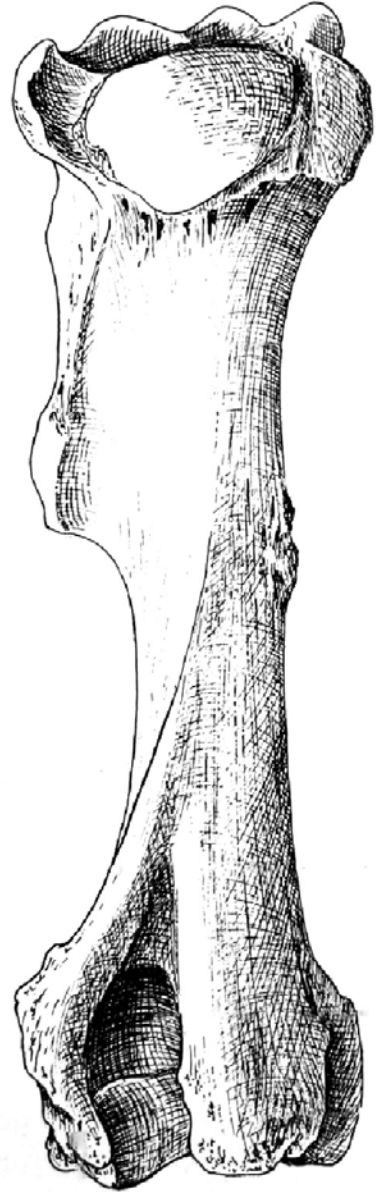
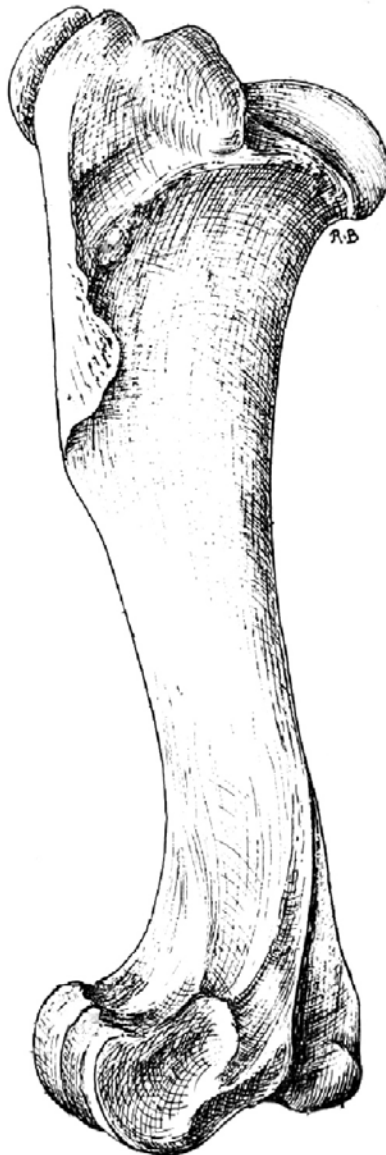
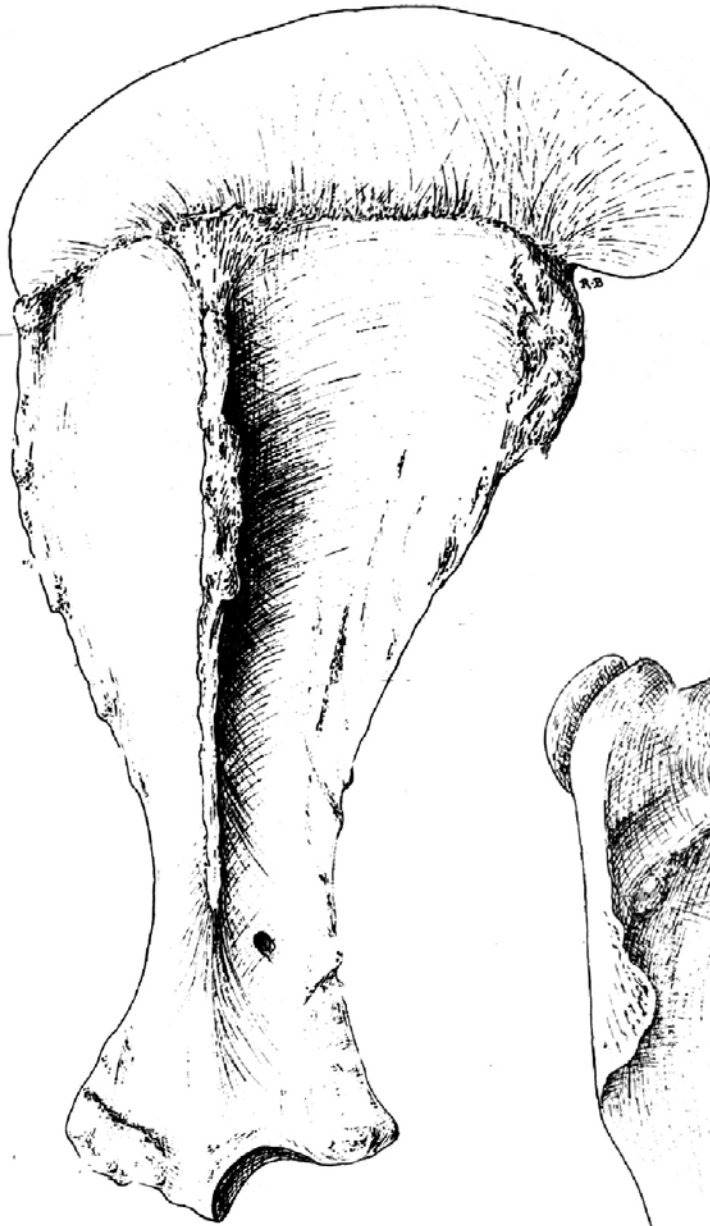
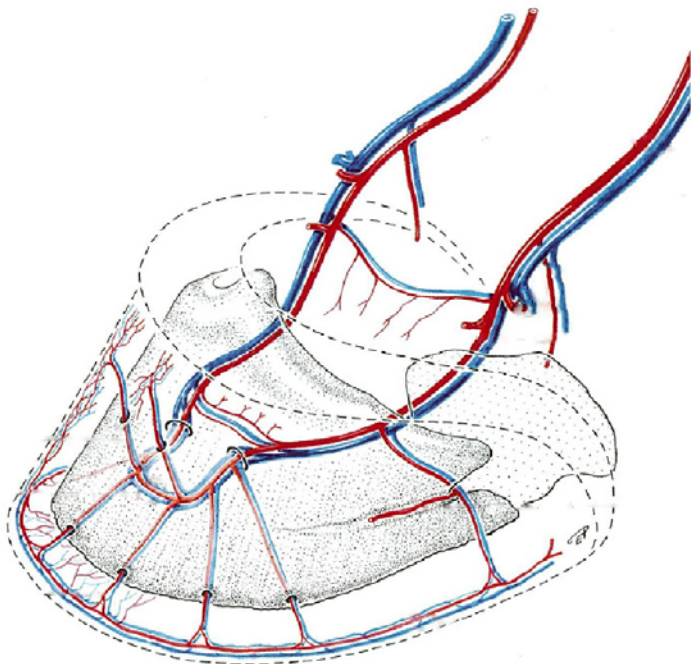
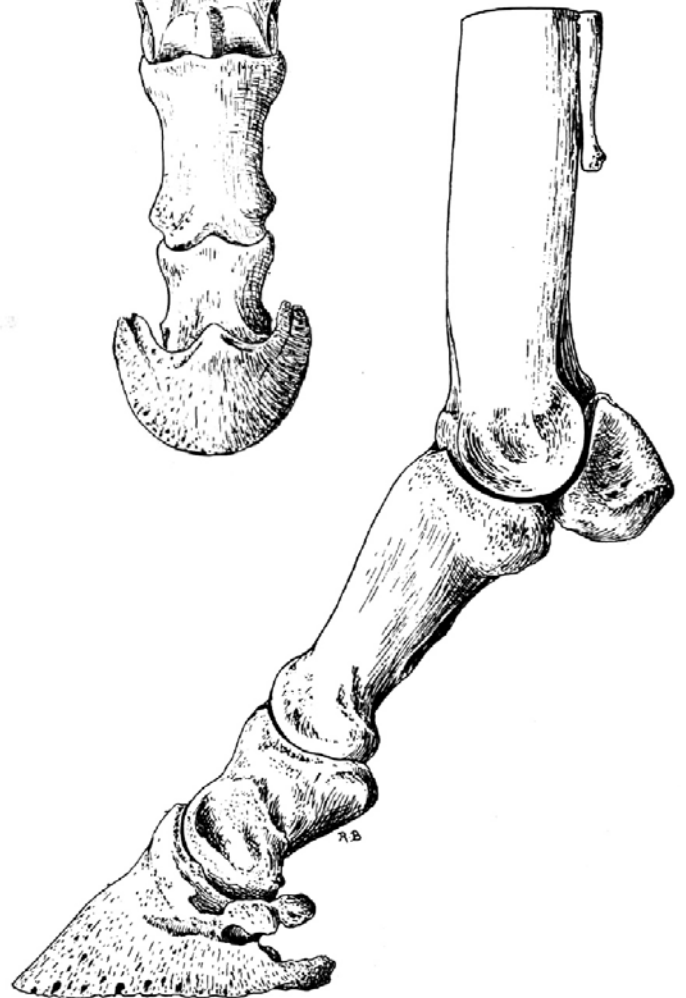
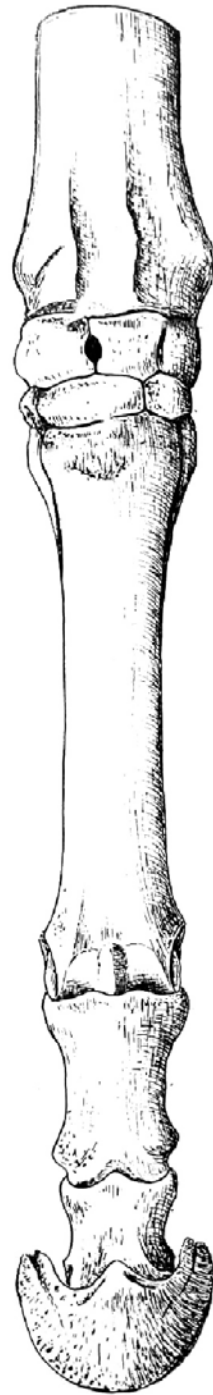
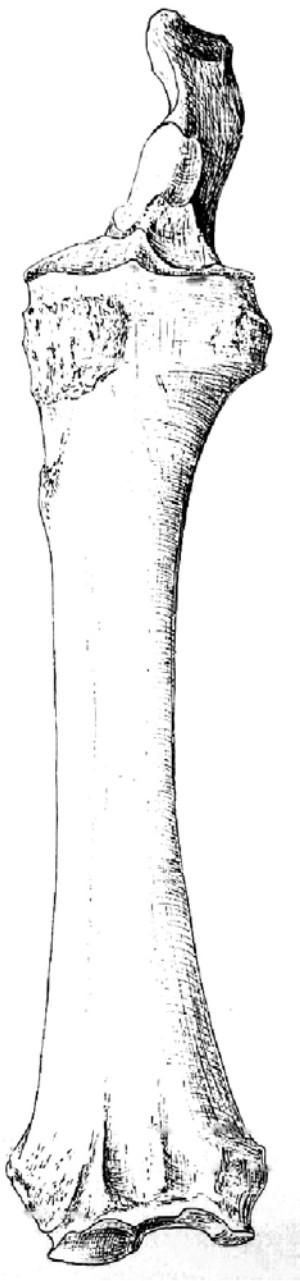


Ossa membri thoracici

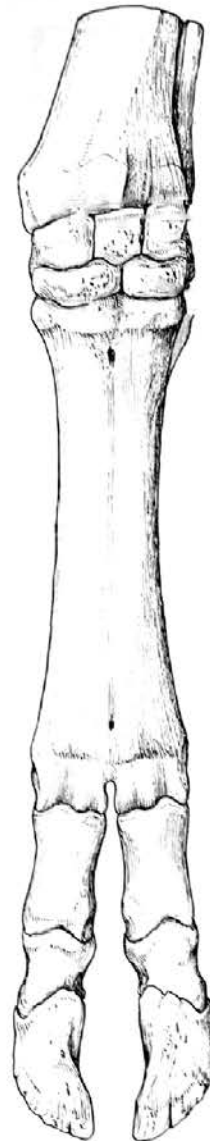
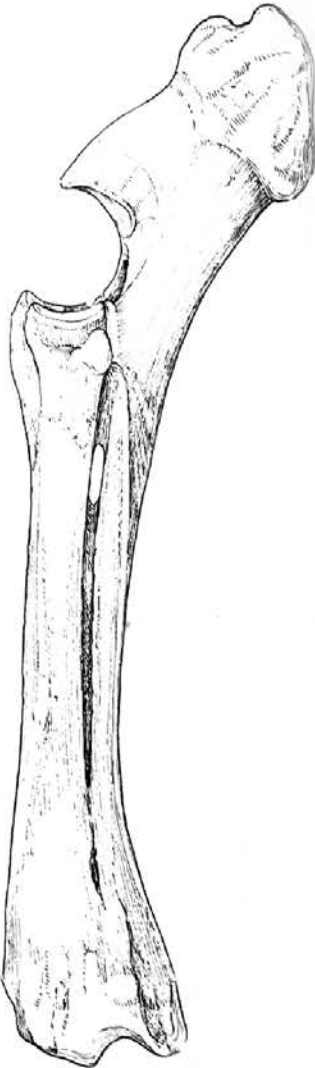
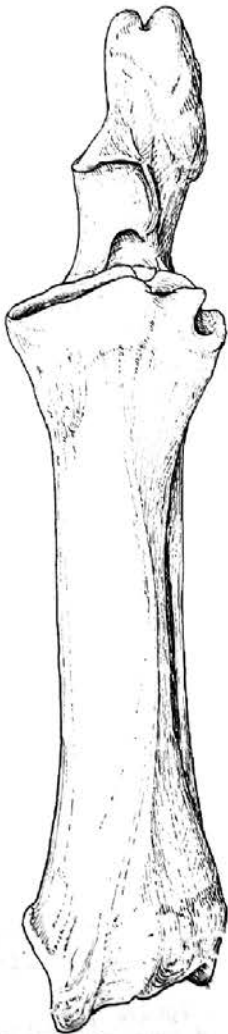
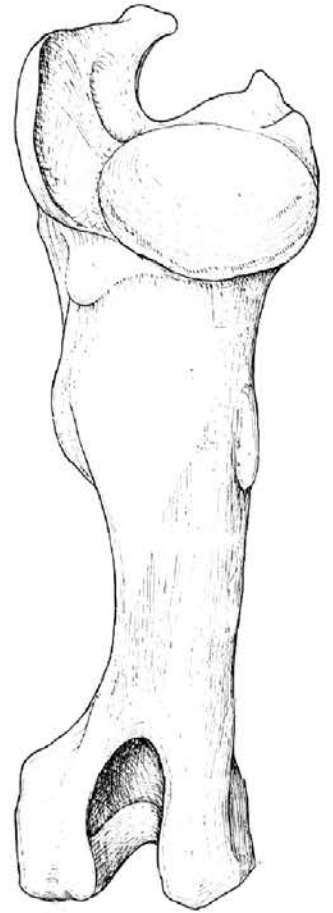
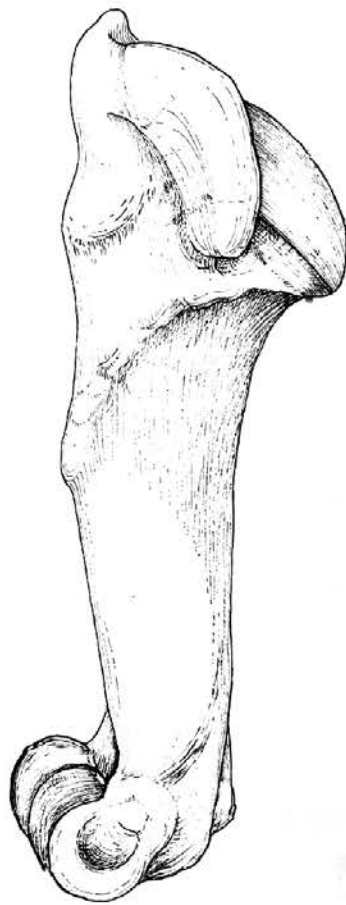
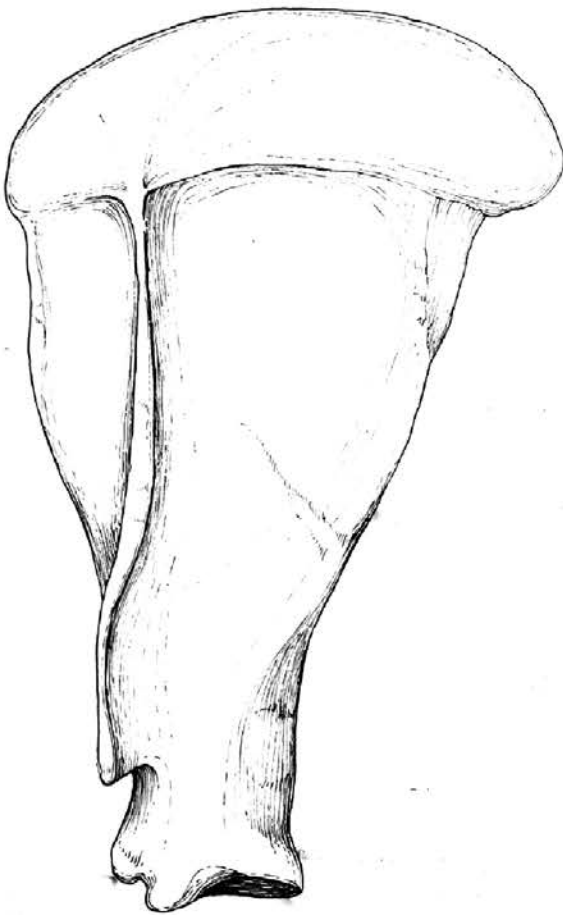
eq



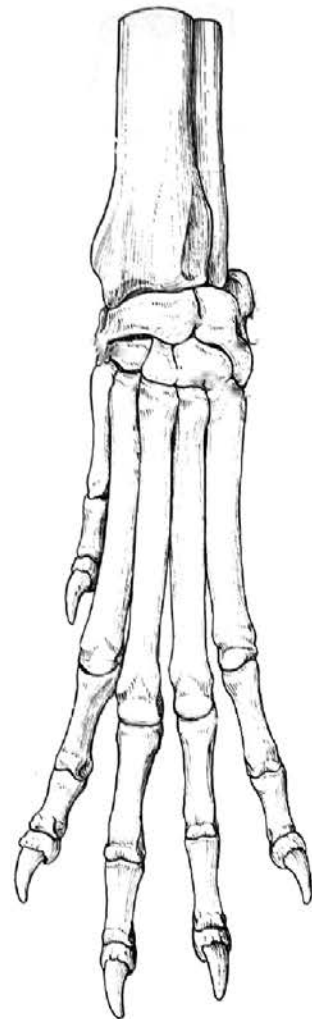
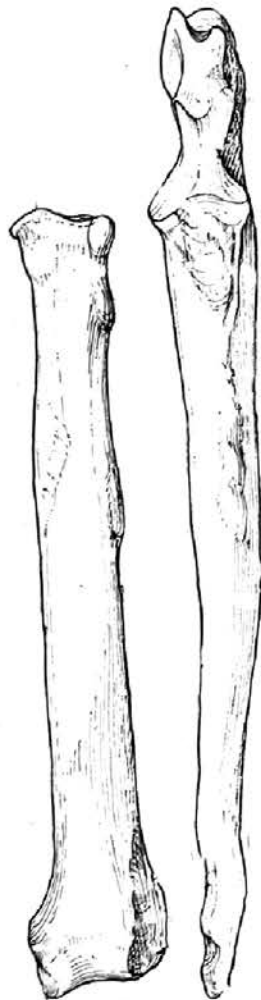
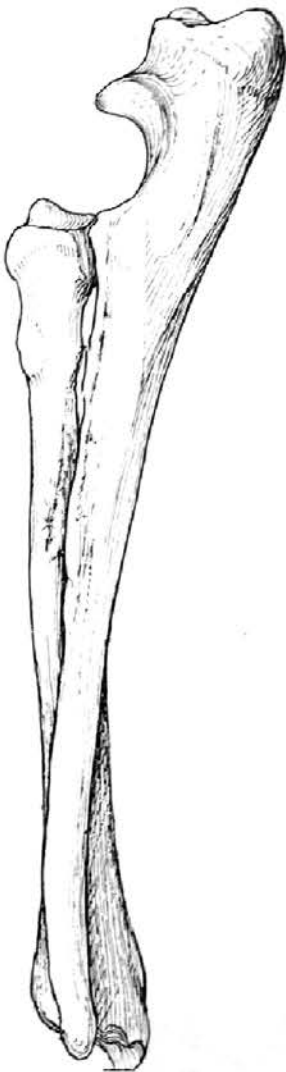
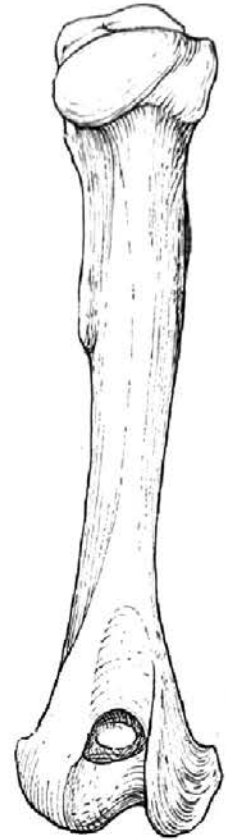
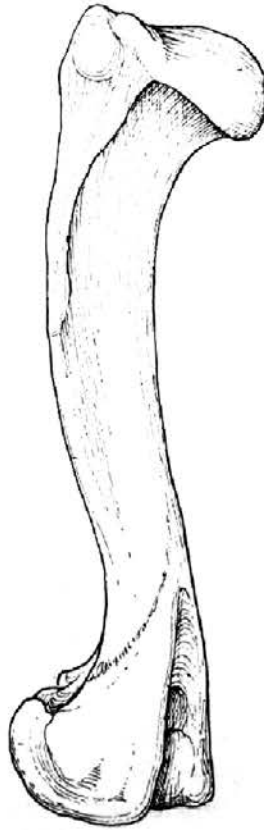
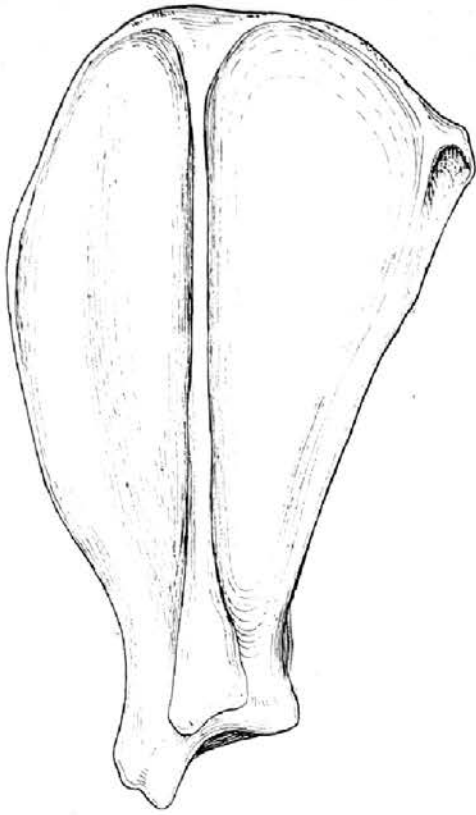
eq

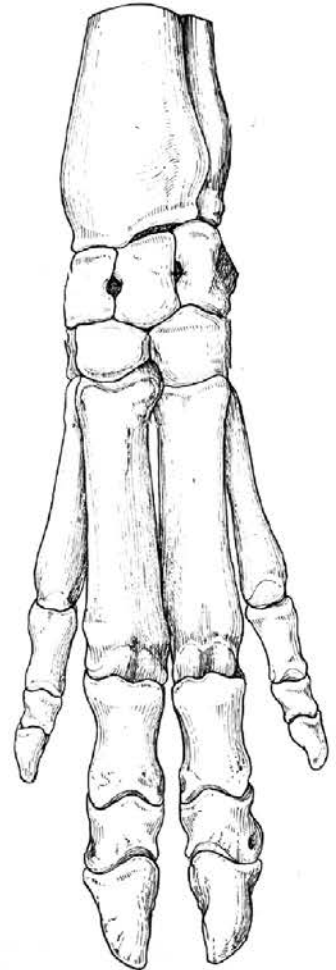
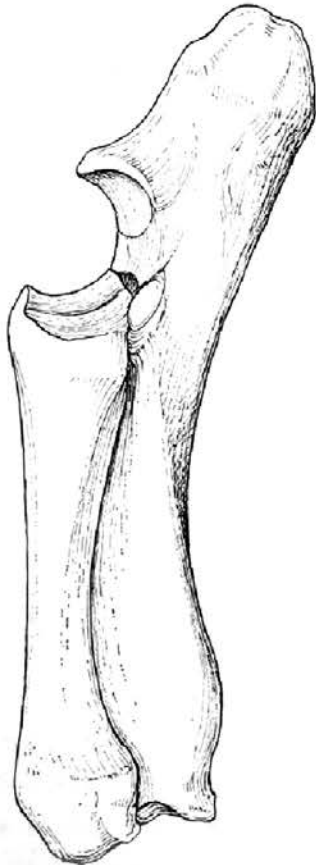
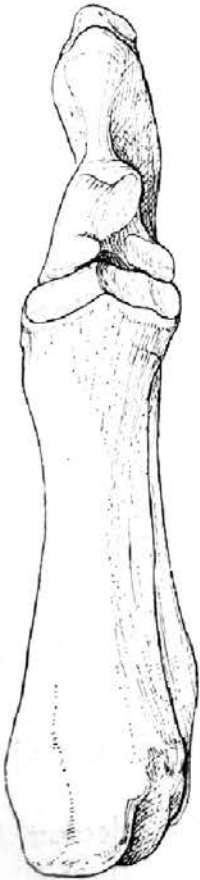
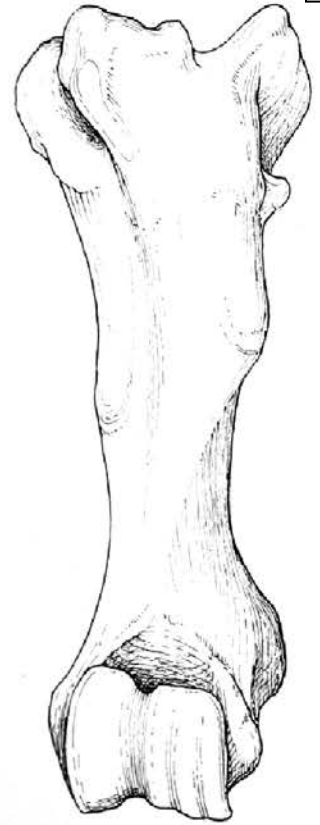
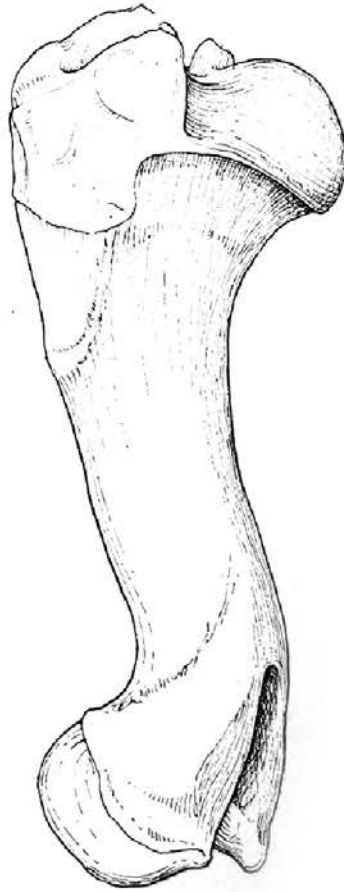
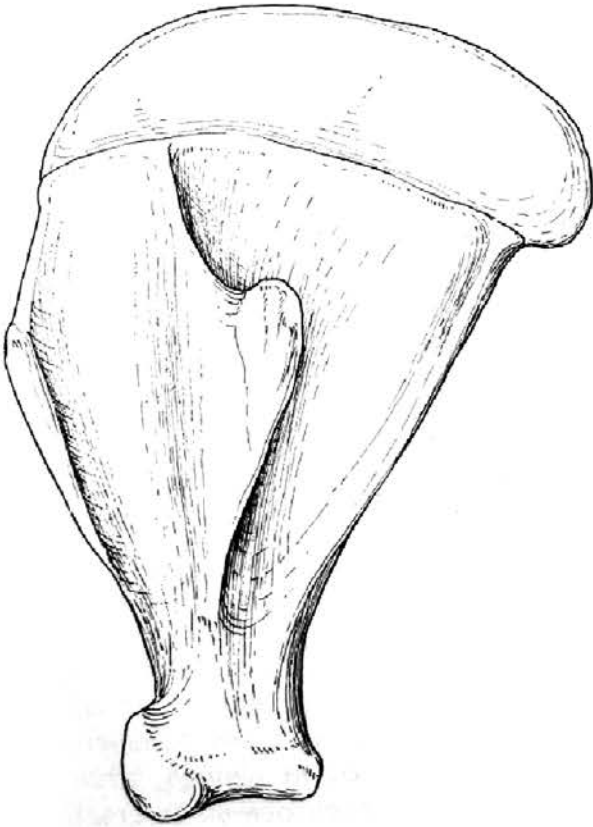


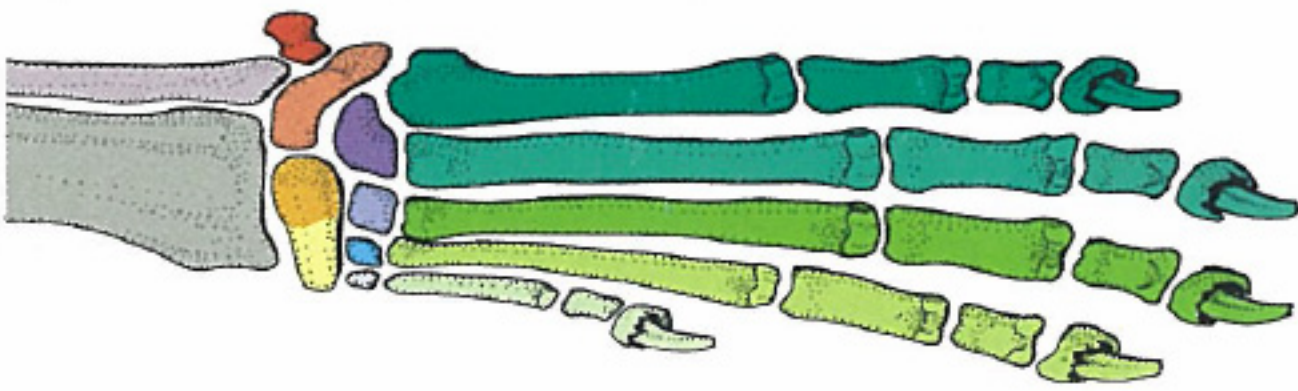
bo



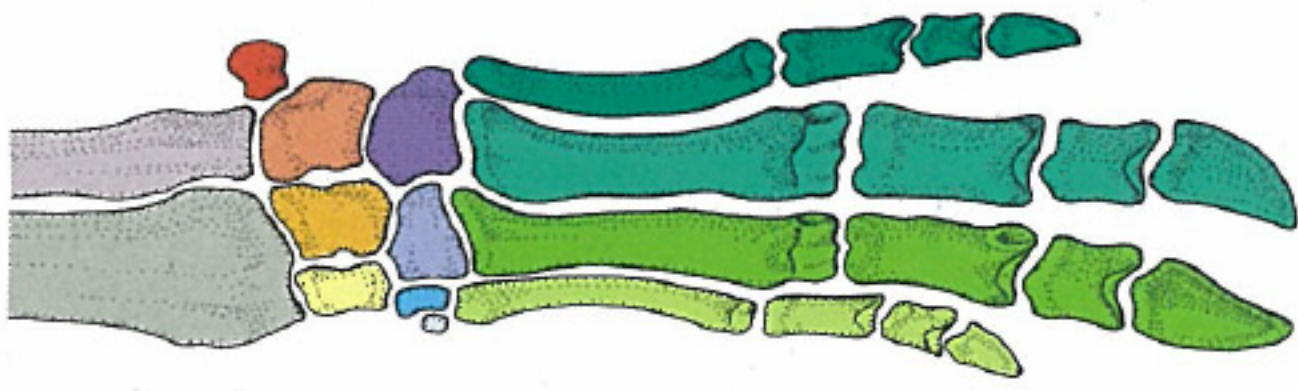
ca








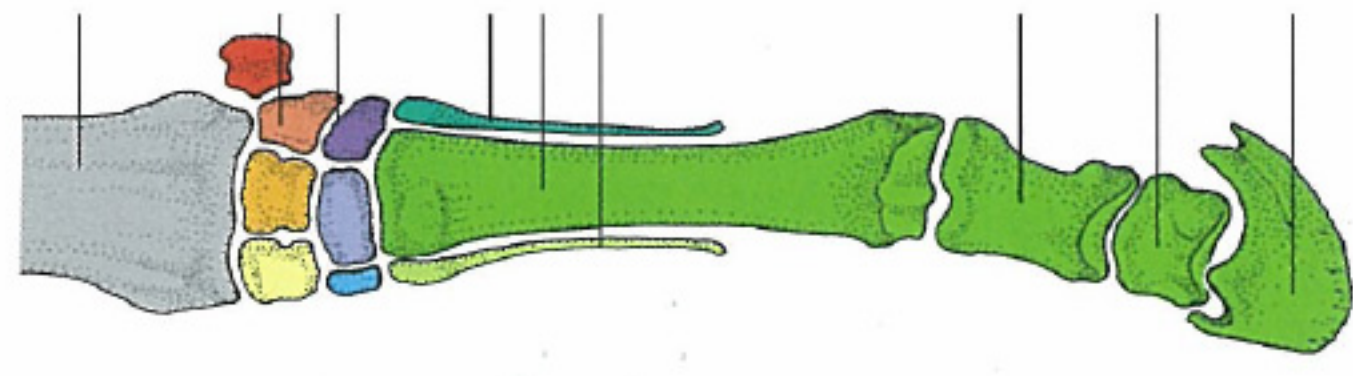
Dog



Pig



Cattle



Horse

- Radius
- Ulna
- Radial carpal bone
- Intermediate carpal bone
- Ulnar carpal bone

- Accessory carpal bone
- 1st carpal bone
- 2nd carpal bone
- 3rd carpal bone
- 4th carpal bone

- 1st metacarpal bone and bones of the 1st toe
- 2nd metacarpal bone and bones of the 2nd toe
- 3rd metacarpal bone and bones of the 3rd toe
- 4th metacarpal bone and bones of the 4th toe
- 5th metacarpal bone and bones of the 5th toe

Antebrachium

Carpal bones
Proximal row
Distal row

4th metacarpal bone
3rd metacarpal bone
2nd metacarpal bone

Proximal phalanx

Middle phalanx

Distal phalanx