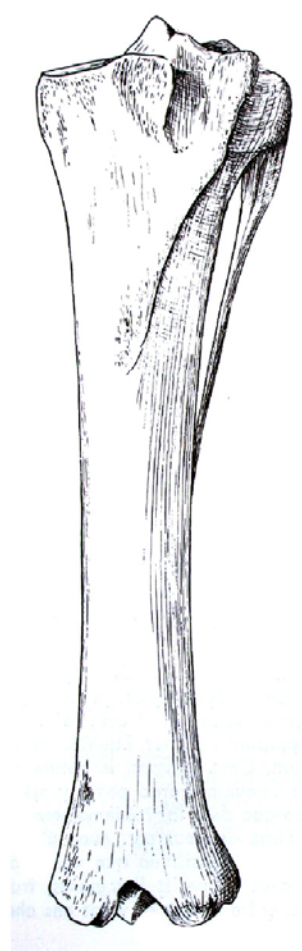
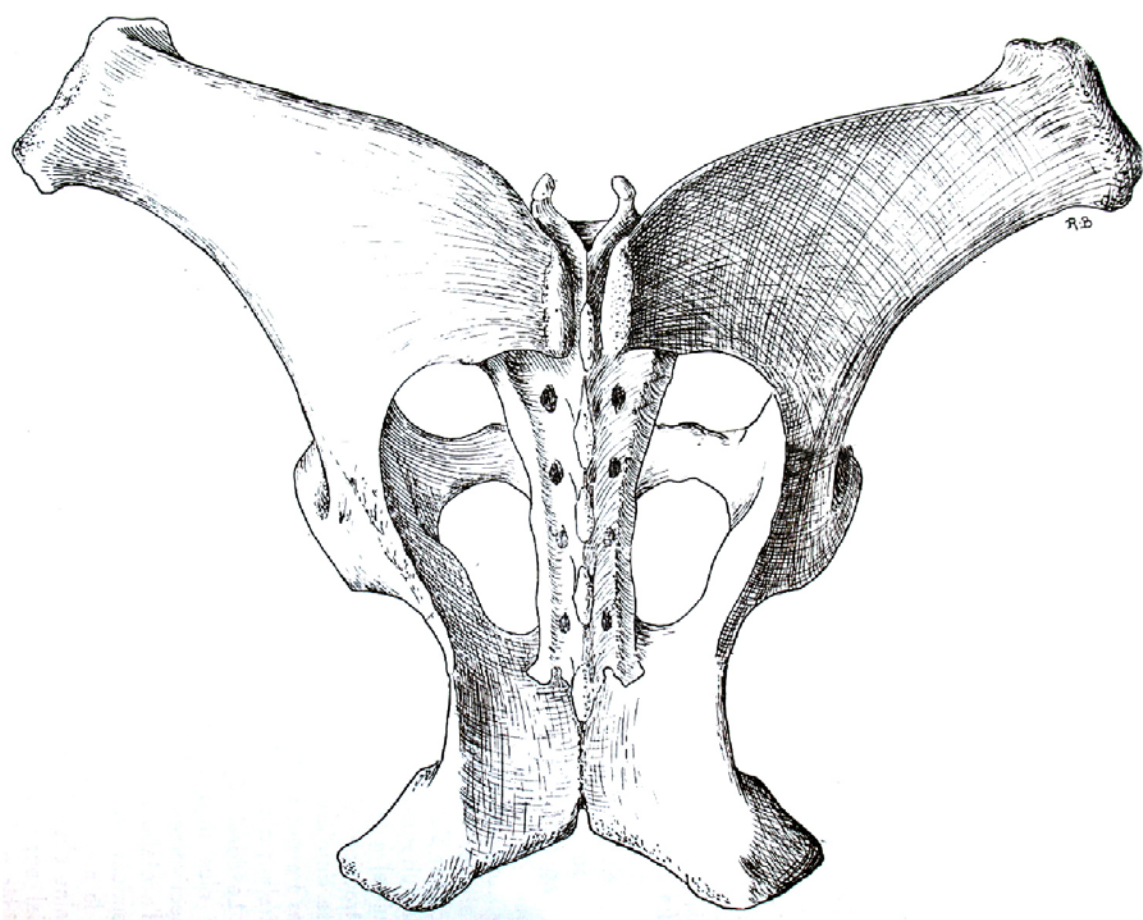
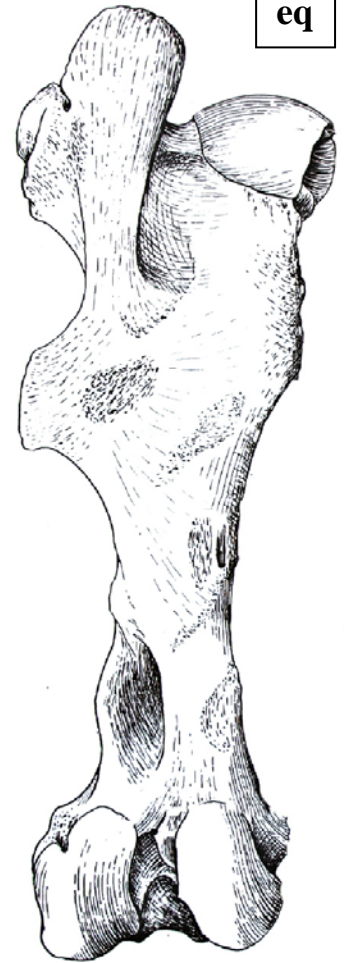
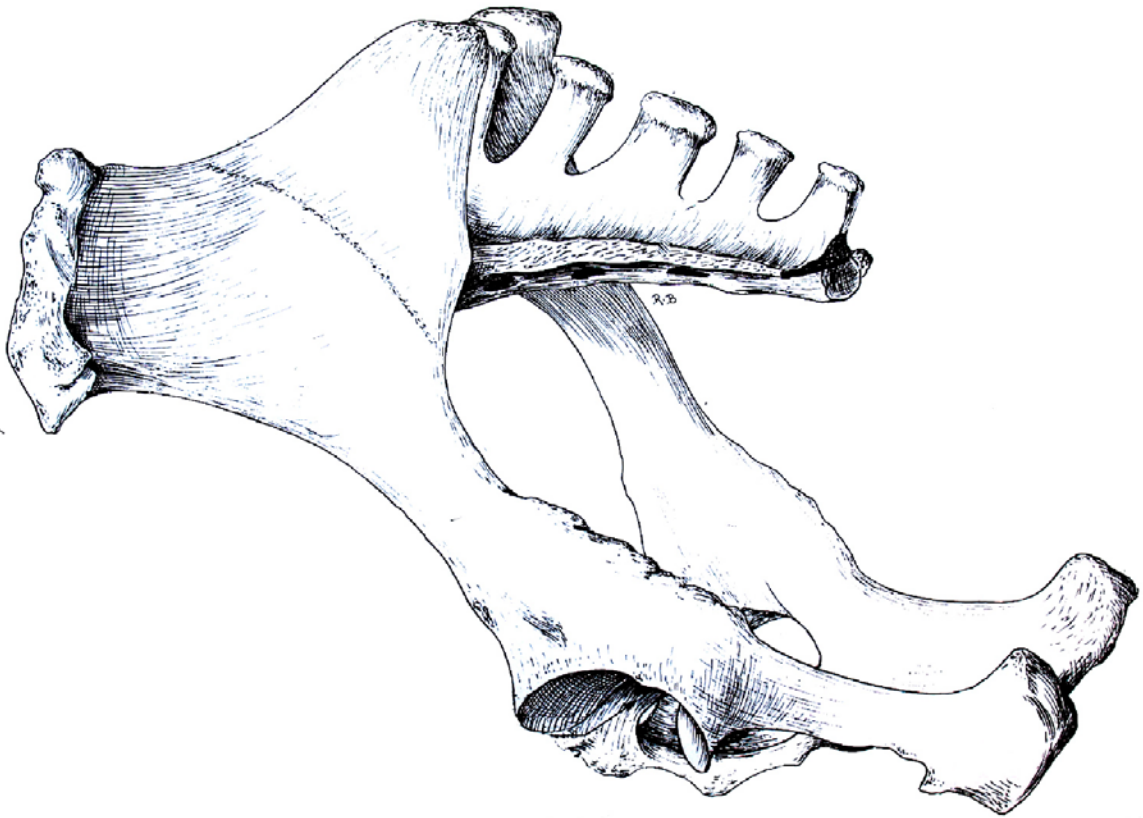
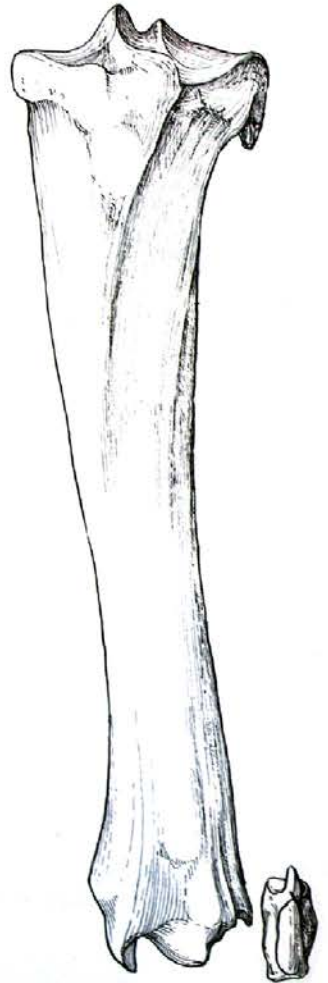
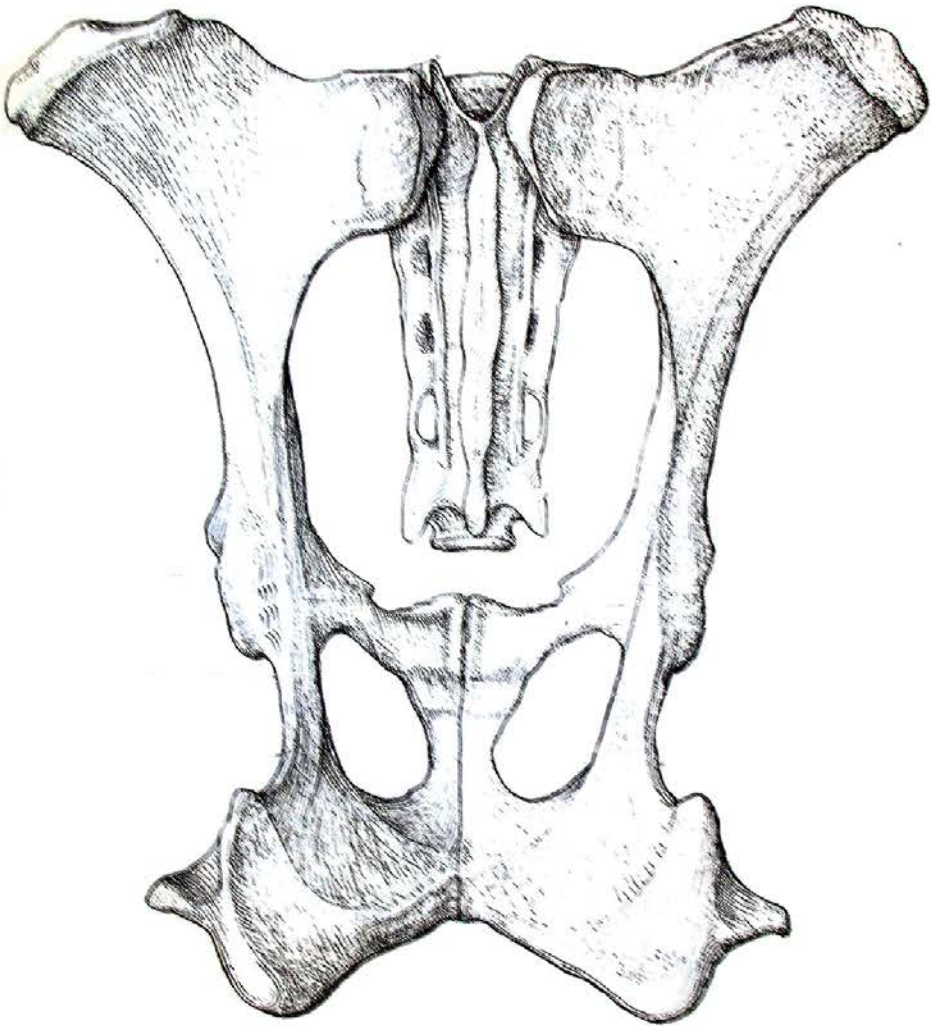
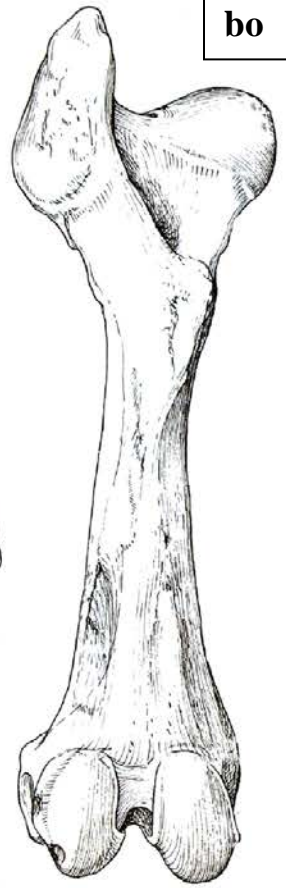
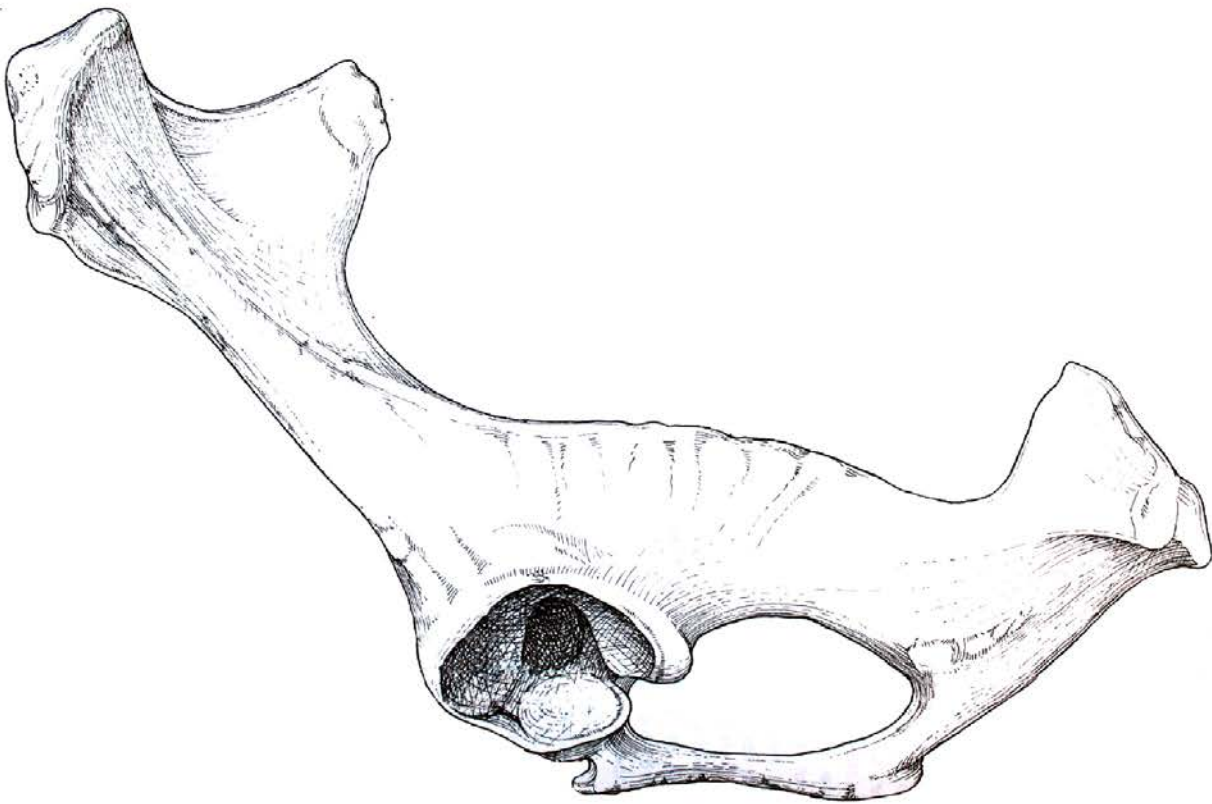


Ossa membri pelvini

eq



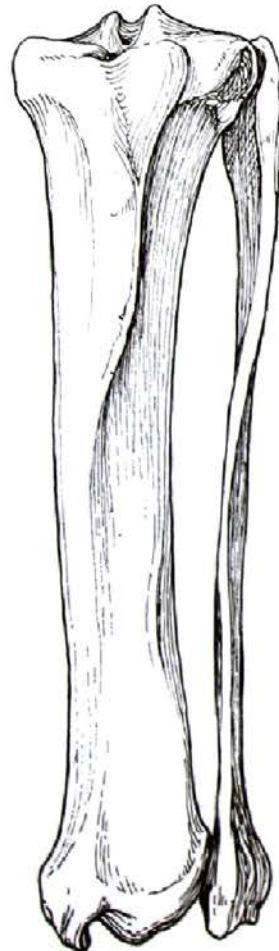
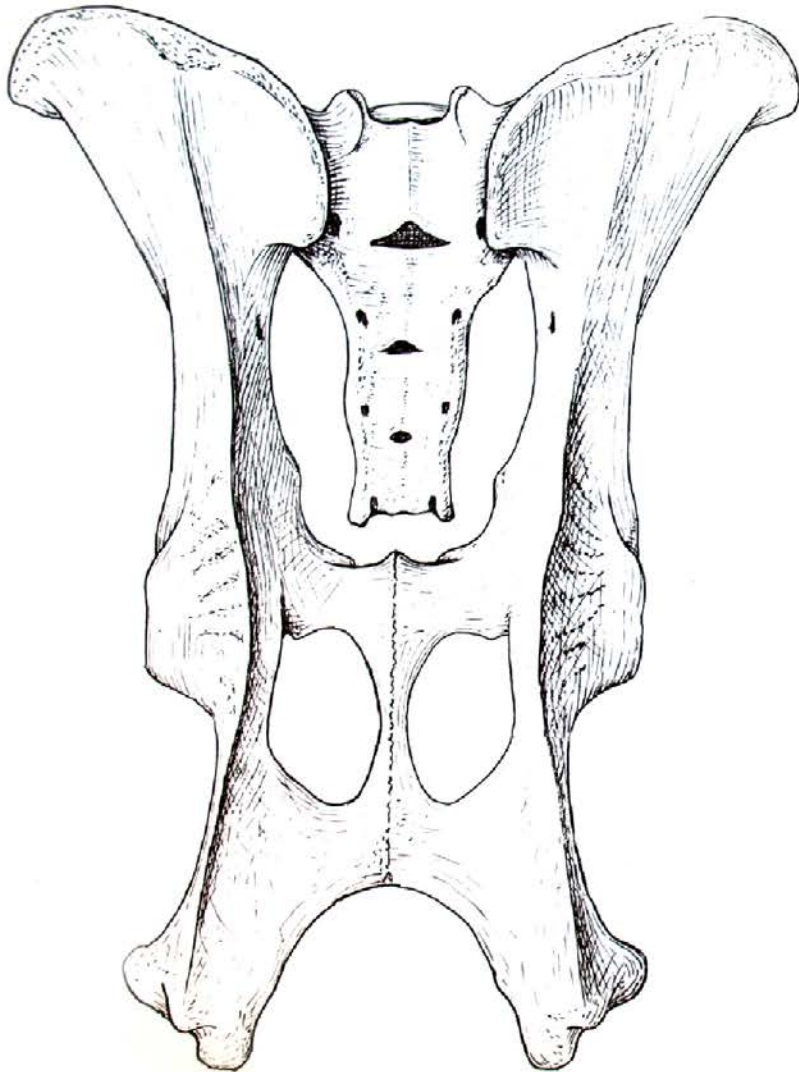
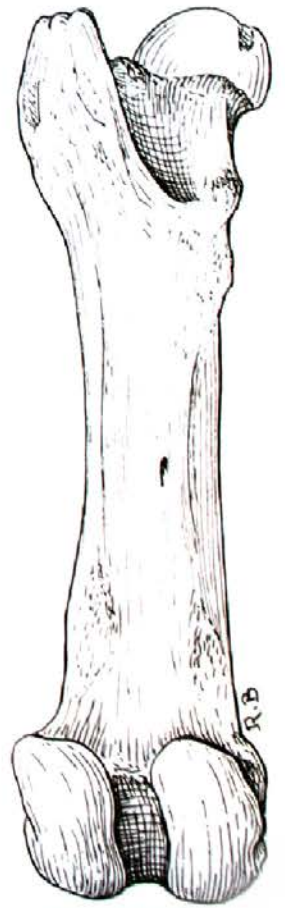
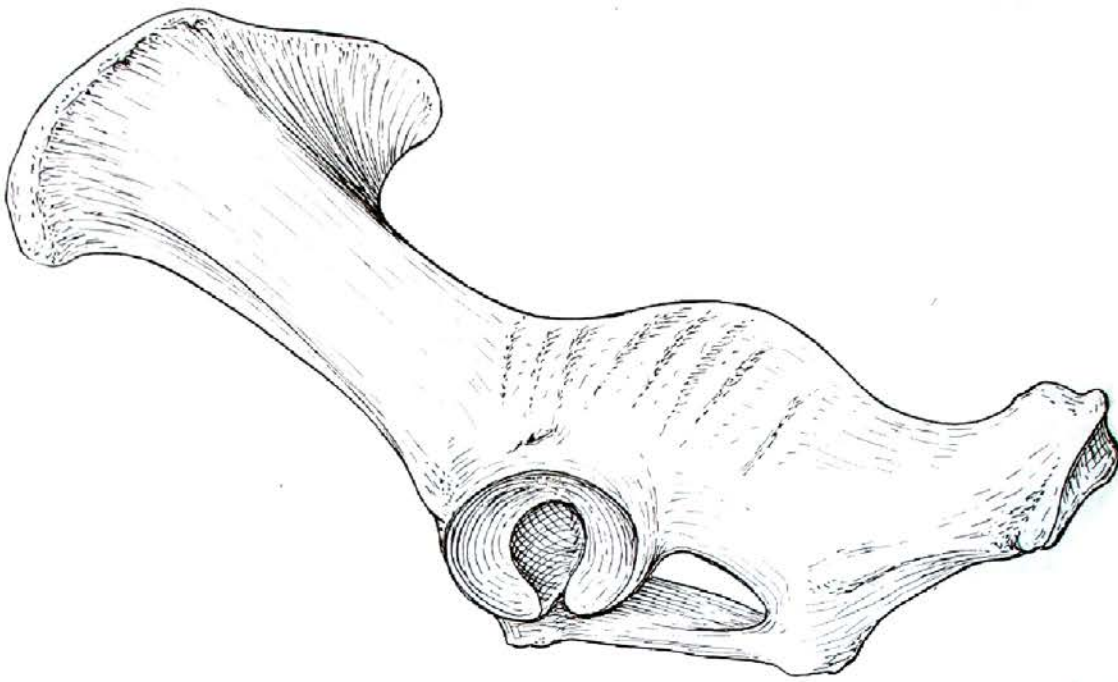
bo



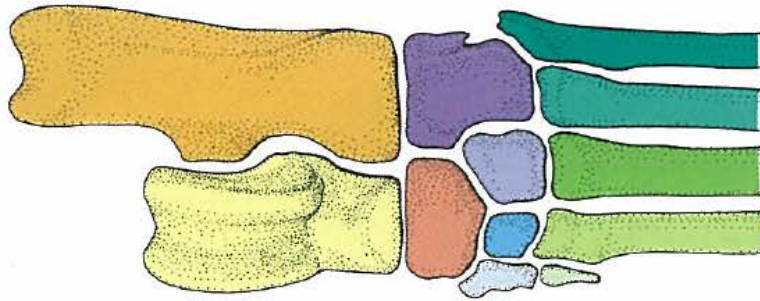




SU

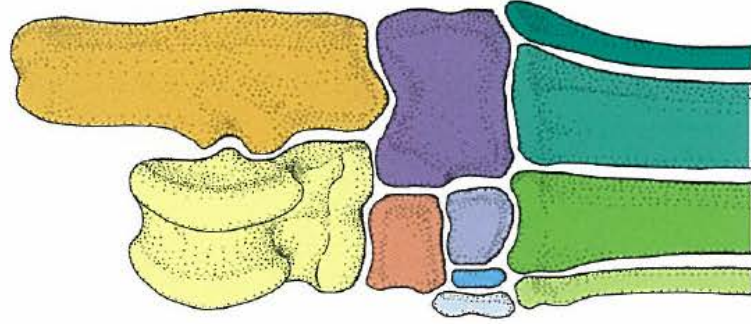






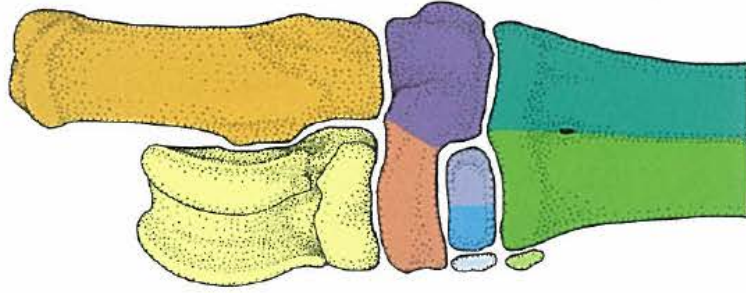
Dog

- Talus
- Calcaneus
- Central tarsal bone



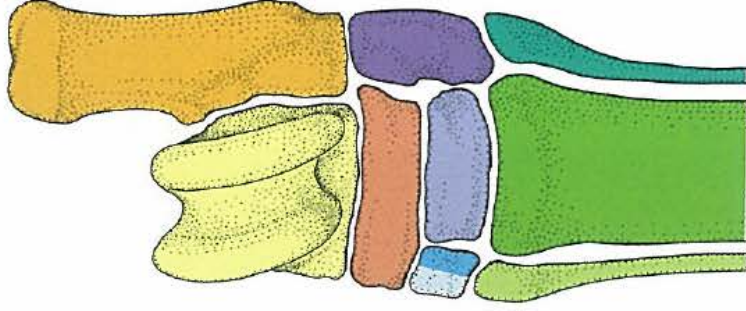
Pig

- 1st tarsal bone
- 2nd tarsal bone
- 3rd tarsal bone



Ox

- 4th tarsal bone
- 1st metatarsal bone
- 2nd metatarsal bone



Horse

- 3rd metatarsal bone
- 4th metatarsal bone
- 5th metatarsal bone