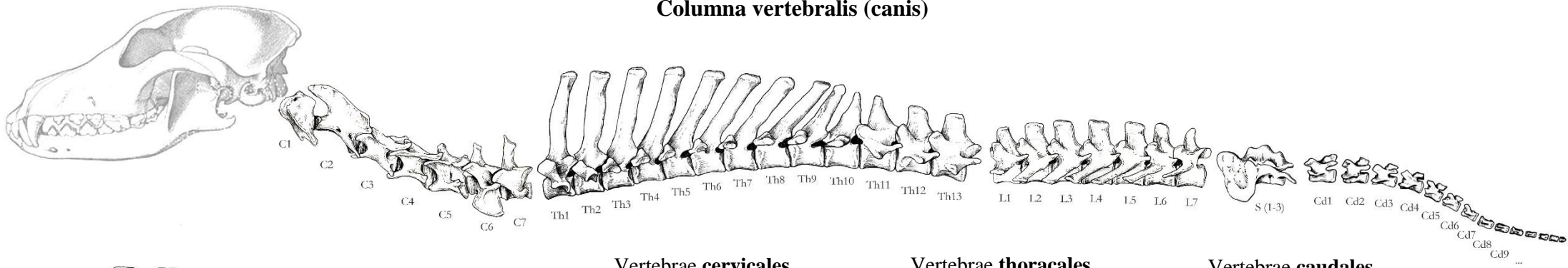


# Columna vertebralis (canis)



## Vertebrae cervicales

Foramen transversarium

### Atlas (C1)

- Massa lateralis
- Ala atlantis
- Incisura alaris
- Foramen vertebrale laterale
- Fossa atlantis
- Fovea articularis cranialis
- Fovea articularis caudalis
- Fovea dentis
- Arcus dorsalis
- Arcus ventralis
- Tuberculum dorsale
- Tuberculum ventrale
- Ø Processus spinosus
- Ø Corpus vertebrae

### Axis (C2)

- Dens

### Vertebra cervicalis III-V. (C3-C5)

- Tuberculum dorsale
- Tuberculum ventrale

### Vertebra cervicalis VI. (C6)

- Tuberculum dorsale
- Lamina ventralis

### Vertebra cervicalis VII. (C7)

- [=vertebra prominens]
- Fovea costalis caudalis
- Ø Foramen transversarium

## Vertebrae thoracales

- Fovea costalis cranialis
- Fovea costalis caudalis
- Fovea costalis transversalis
- Processus mamillaris
- Processus accessorius

## Vertebrae lumbales

- Processus mamillaris
- Processus accessorius

## Vertebrae sacrales

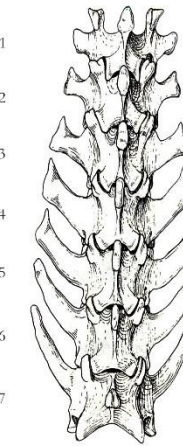
[ = Sacrum ]

- Basis ossis sacri
- Processus articularis cranialis
- Promontorium
- Pars lateralis
- Ala sacralis
- Facies auricularis
- Tuberositas sacralis
- Facies dorsalis
- Foramina sacralia dorsalia
- Crista sacralis lateralis
- Facies pelvina
- Foramina sacralia ventralia
- Lineae transversae
- Apex ossis sacri
- Processus articularis caudalis
- Canalis sacralis

## Vertebrae caudales

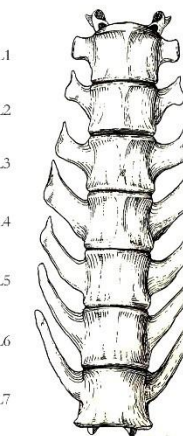
- Arcus hemalis
- Processus hemalis

L1  
L2  
L3  
L4  
L5  
L6  
L7

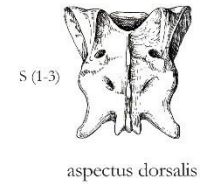


aspectus dorsalis

L1  
L2  
L3  
L4  
L5  
L6  
L7

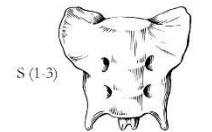


aspectus ventralis



S (1-3)

aspectus dorsalis



S (1-3)

aspectus ventralis



Cd1



Cd6

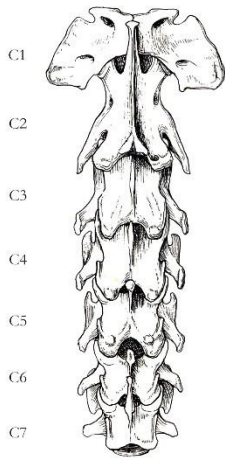
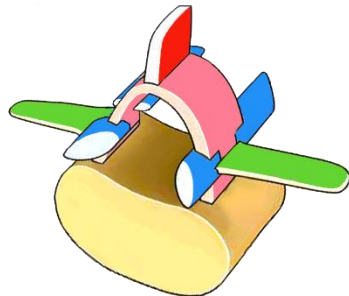


Cd12

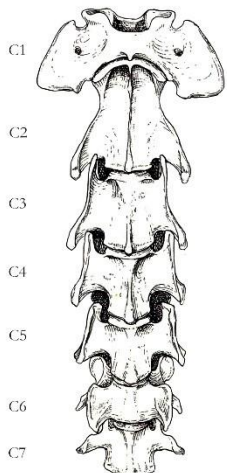
aspectus dorsalis

## Vertebra generalis

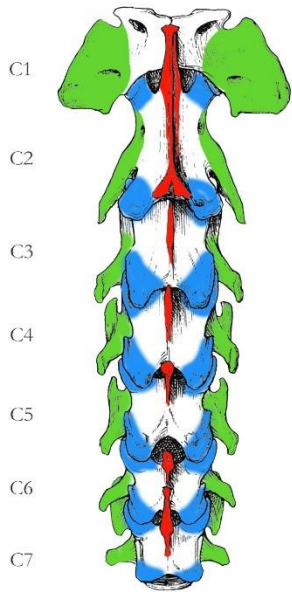
- Corpus vertebrae
- Extremitas cranialis [=Caput vertebrae]
- Extremitas caudalis [=Fossa vertebrae]
- Crista ventralis
- Arcus vertebrae
- Pediculus arcus vertebrae
- Lamina arcus vertebrae
- Foramen vertebrale
- Incisura vertebralis cranialis
- Incisura vertebralis caudalis
- Foramen intervertebrale
- Processus spinosus
- Processus transversus
- Processus articularis cranialis
- Processus articularis caudalis



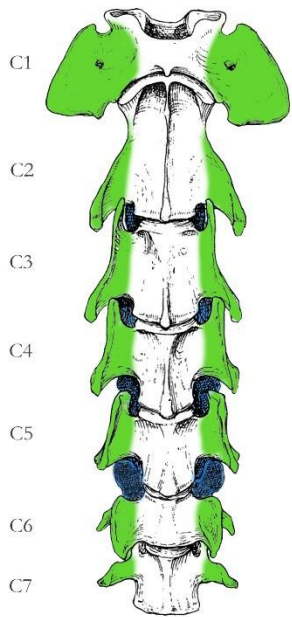
aspectus dorsalis



aspectus ventralis

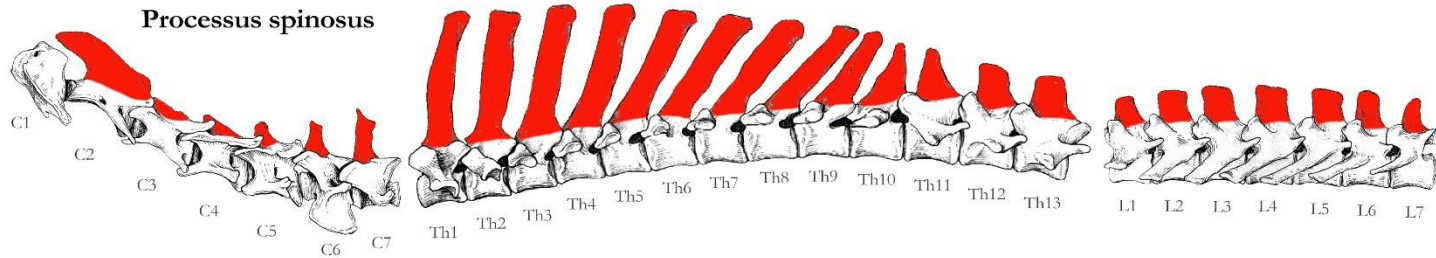


aspectus dorsalis

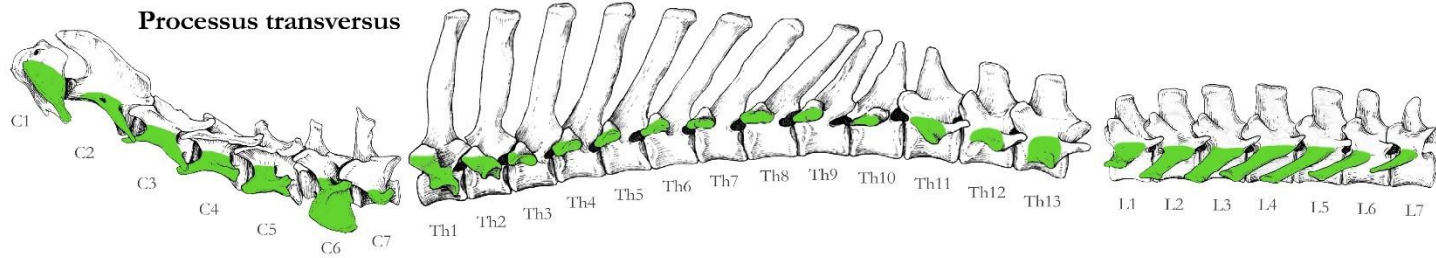


aspectus ventralis

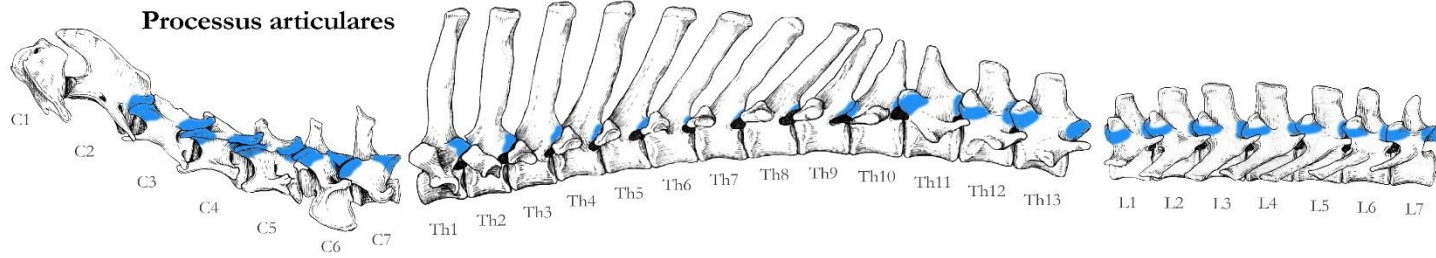
**Processus spinosus**



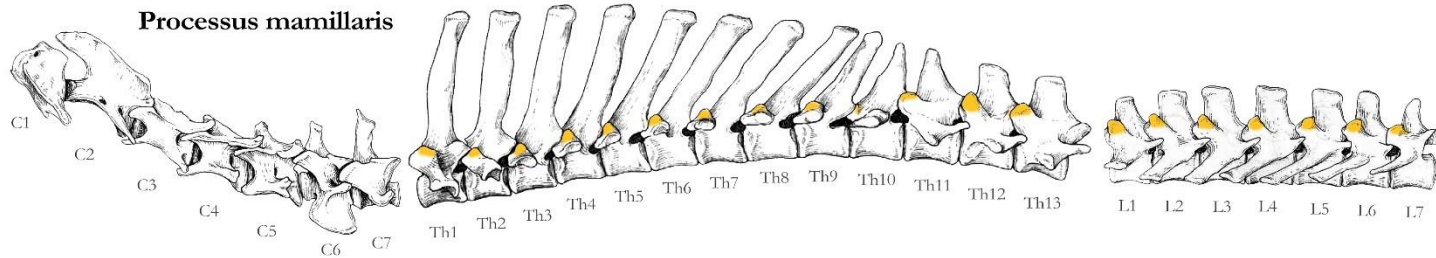
**Processus transversus**



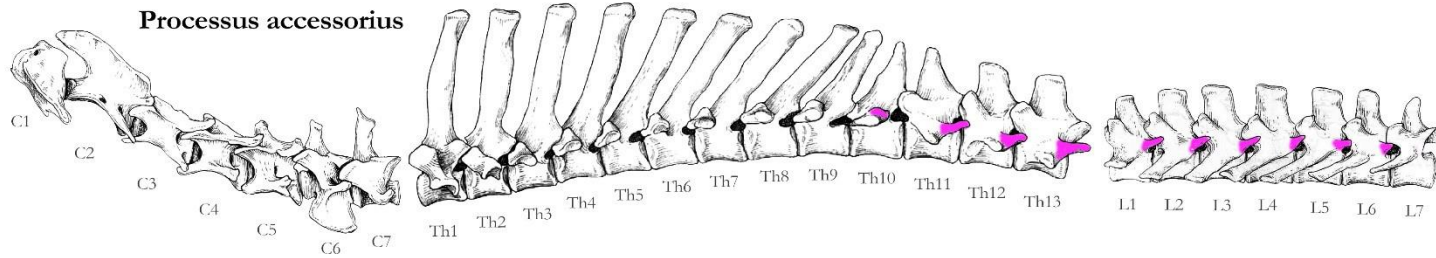
**Processus articulares**



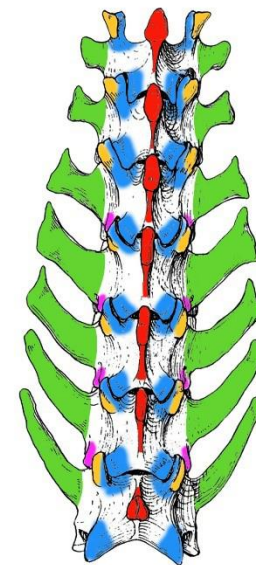
**Processus mamillaris**



**Processus accessorius**

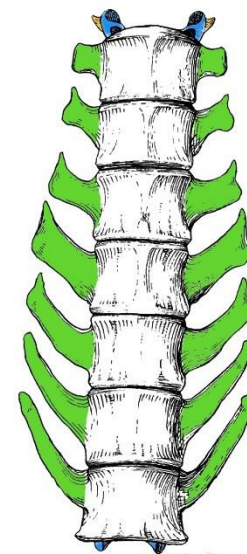


L1  
L2  
L3  
L4  
L5  
L6  
L7



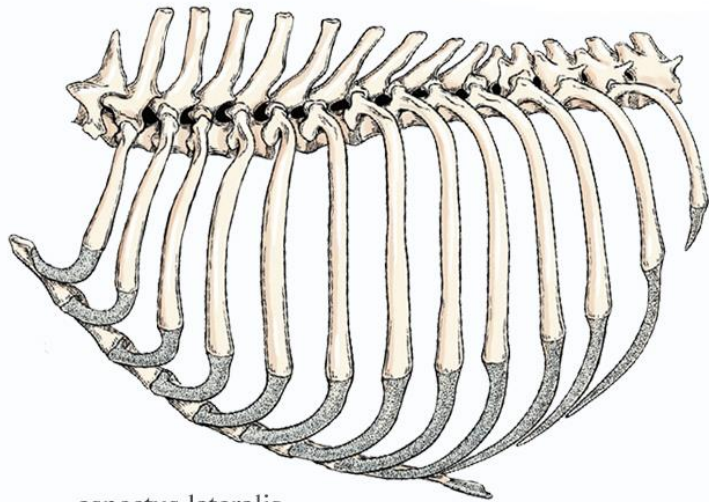
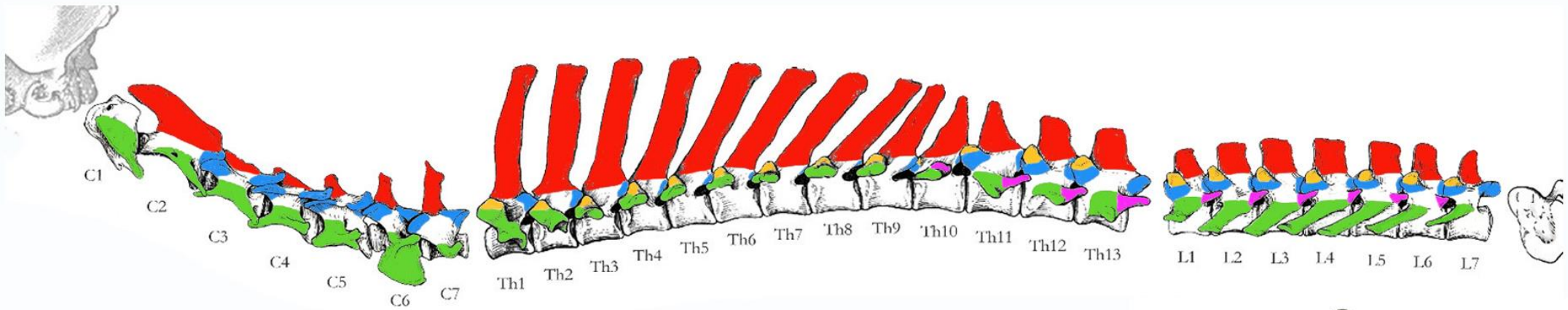
aspectus dorsalis

L1  
L2  
L3  
L4  
L5  
L6  
L7

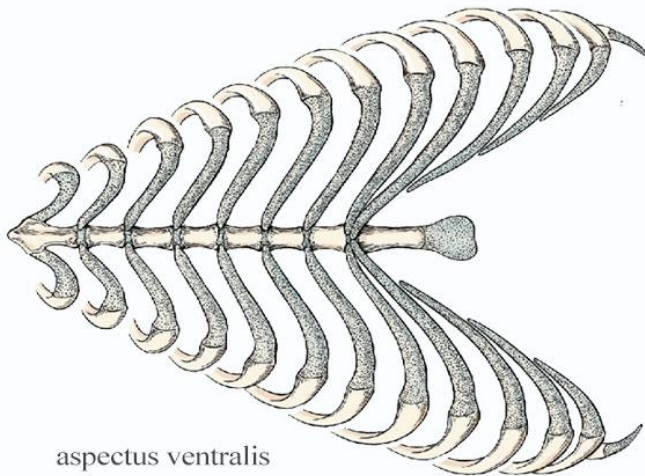


aspectus ventralis





aspectus lateralis



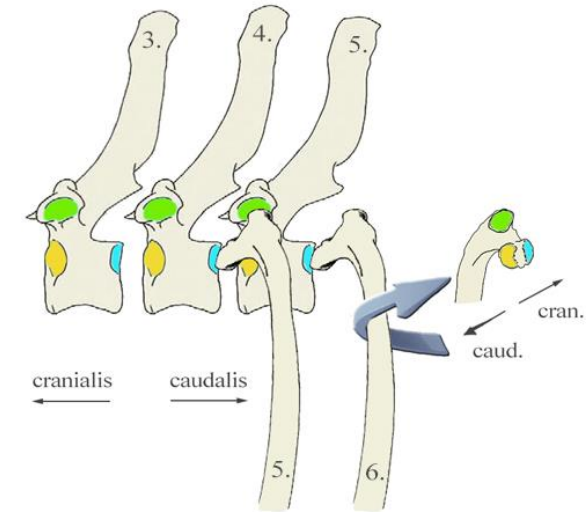
aspectus ventralis

### Costae

- Costae verae [=sternales]
- Costae spuriae [=asternales]
- Costae fluctuantes
- Cartilago costalis
- Os costale
- Caput costae
- Facies articularis capitis costae cranialis et caudalis
- Crista capitis costae
- Collum costae
- Corpus costae
- Tuberculum costae
- Facies articularis tuberculi costae
- Angulus costae
- Sulcus costae
- Sulcus muscularis
- Genu costae

### Sternum

- Manubrium sterni
- Corpus sterni
- Sternebrae
- Processus xiphoideus
- Cartilago xiphoidea
- Incisurae costales



### Cavum thoracis

- Apertura thoracis cranialis
- Apertura thoracis caudalis
- Arcus costalis
- Spatium intercostale

### Facies contactus

- | <u>Costae</u>                                 |   | <u>Vertebrae</u>  |
|---|---|---|
| • Facies articularis capitis costae cranialis | ↔ | Fovea costalis caudalis <span style="color: blue;">■</span>       |
| • Facies articularis capitis costae caudalis  | ↔ | Fovea costalis cranialis <span style="color: yellow;">■</span>    |
| • Facies articularis tuberculi costae         | ↔ | Fovea costalis transversalis <span style="color: green;">■</span> |

