

DEVELOPMENT OF NERVOUS SYSTEM

Andrea Heinzlmann

University of Veterinary Medicine, Budapest

Department of Anatomy and Histology

Embryology Course

DEVELOPMENT OF NERVOUS SYSTEM

the nervous system consists of:

I. CENTRAL NERVOUS SYSTEM (CNS) includes the:

1. brain
2. spinal cords

II. PERIPHERAL NERVOUS SYSTEM (PNS) includes the:

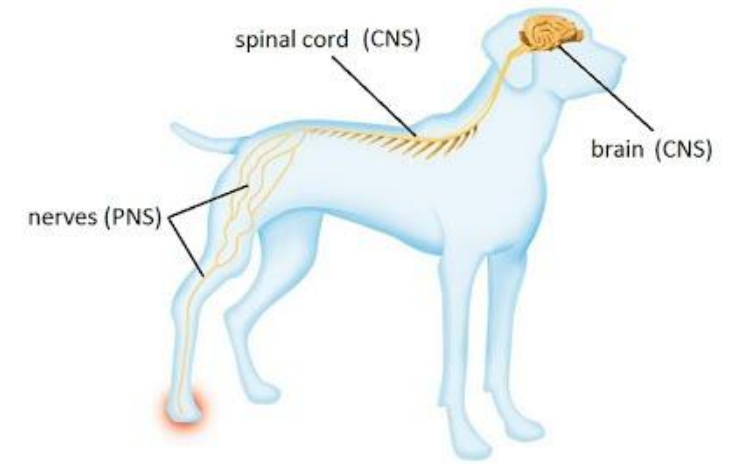
- neurons outside the CNS
- cranial and spinal nerves – connect the brain and spinal cord with the peripheral structures

III. AUTONOMIC NERVOUS SYSTEM (ANS):

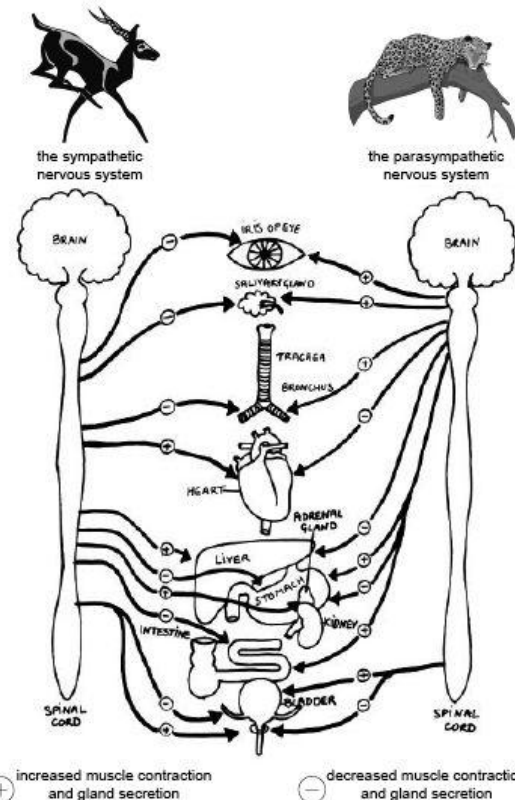
- has parts in CNS and PNS

consists of neurons innervate the:

1. smooth muscle
2. cardiac muscle
3. glandular epithelium



<https://thealevelbiologist.co.uk/genetics-control-homeostasis/the-nervous-system-and-the-identification-and-consequences-of-damage/>



https://en.wikibooks.org/wiki/Anatomy_and_Physiology_of_Animals/Nervous_System

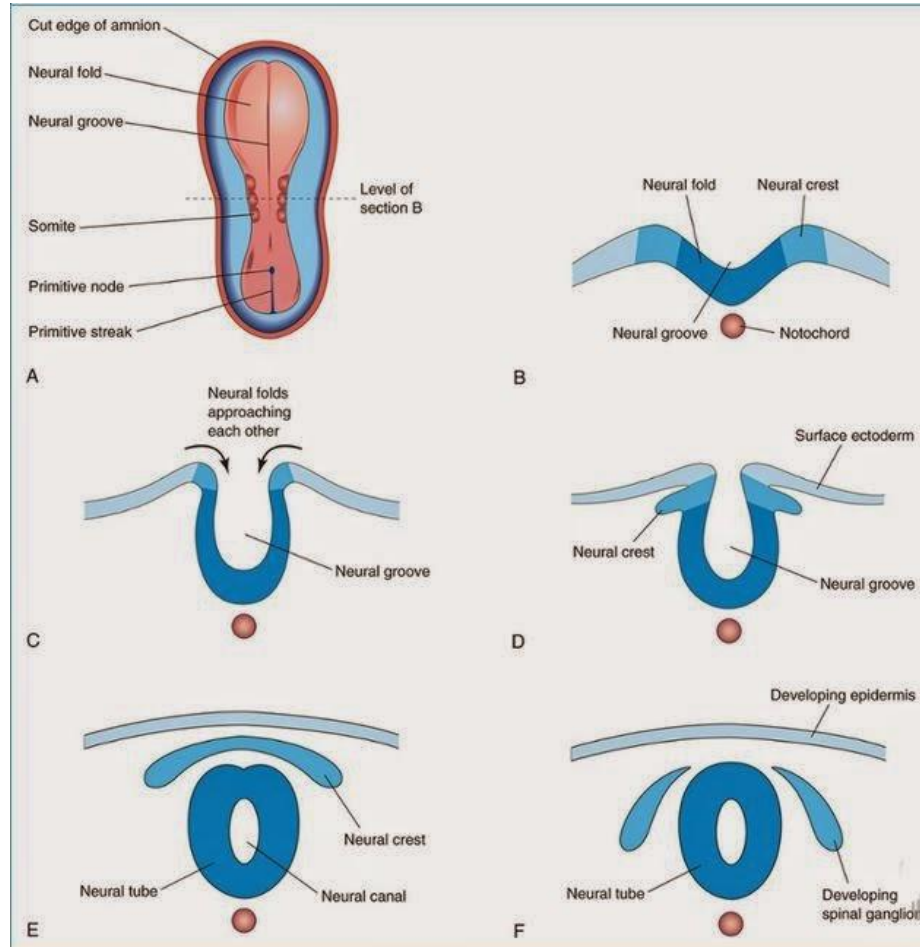
ORIGIN OF NERVOUS SYSTEM

NEURULATION:

- begins during the early part of the 4th week

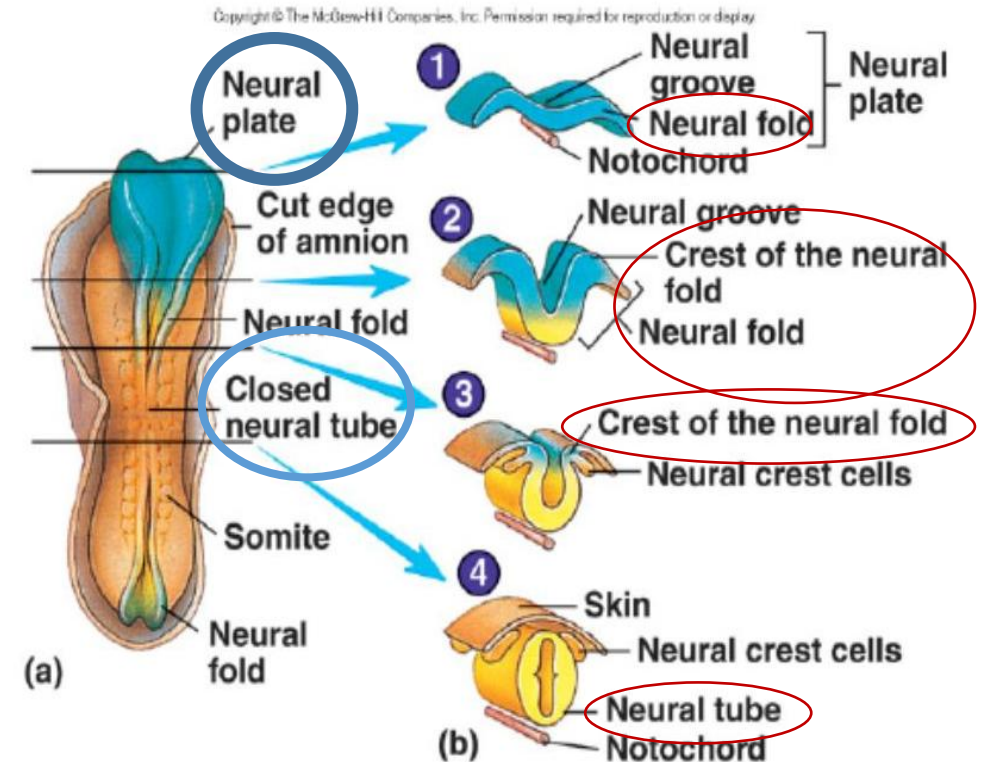
formation of the:

1. neural plate
2. neural tube



<http://embryocentral.blogspot.com/2014/12/neurulation.html>

FORMATION OF NEURAL TUBE



<https://slideplayer.com/slide/7546977/>

ORIGIN OF NERVOUS SYSTEM

- the nervous system develops from the **NEURAL PLATE**

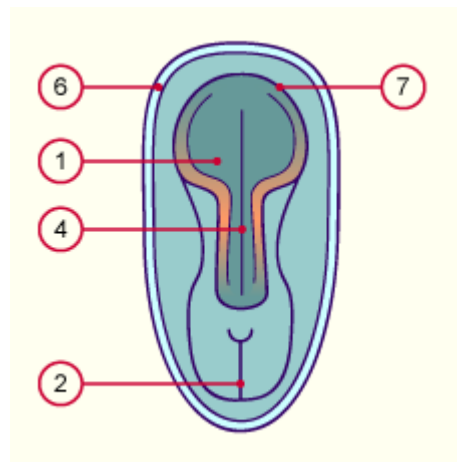
NEURAL PLATE:

- thickened area of embryonic ectoderm

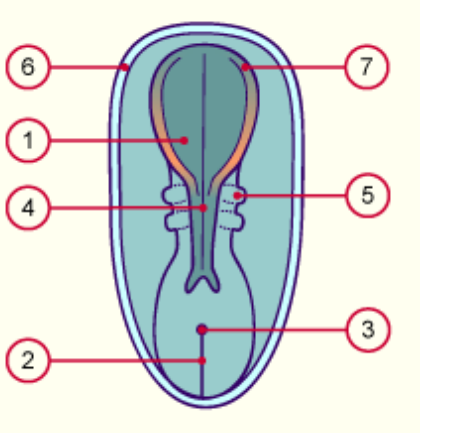
the neural plate forms the:

1. NEURAL FOLDS
2. NEURAL CREST
3. NEURAL GROOVE
4. NEURAL TUBE

Neural plate: 19 – 23rd day

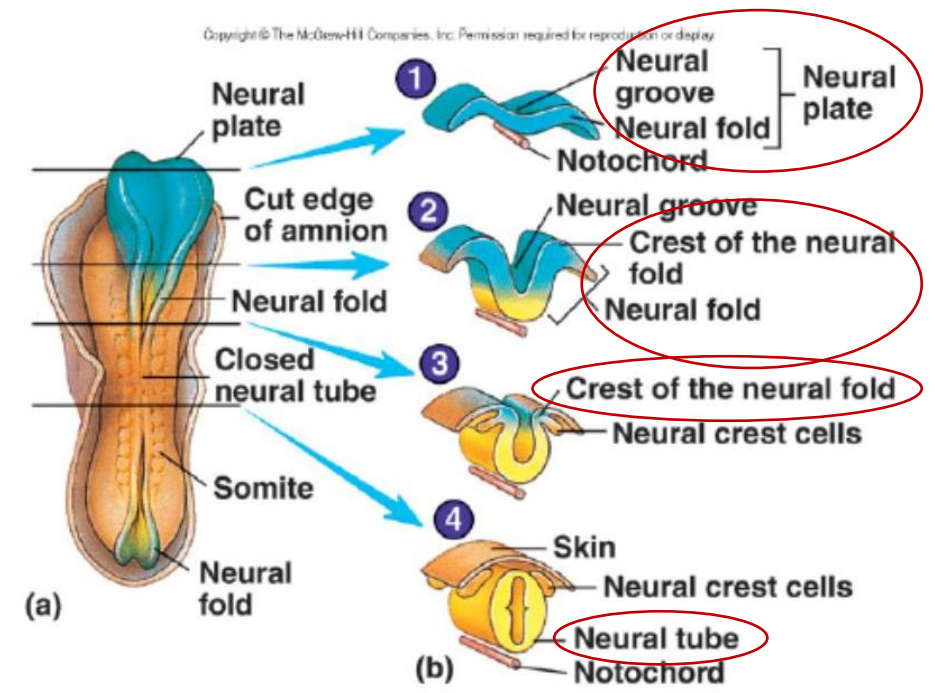


Neural plate at roughly the 25th day



- | | |
|--------------------|-----------------------------|
| 1 Neural plate | 5 Somites |
| 2 Primitive streak | 6 Cut section of the amnion |
| 3 Primitive nodes | 7 Neural folds |
| 4 Neural groove | |

FORMATION OF NEURAL TUBE



<https://slideplayer.com/slide/7546977/>

ORIGIN OF NERVOUS SYSTEM

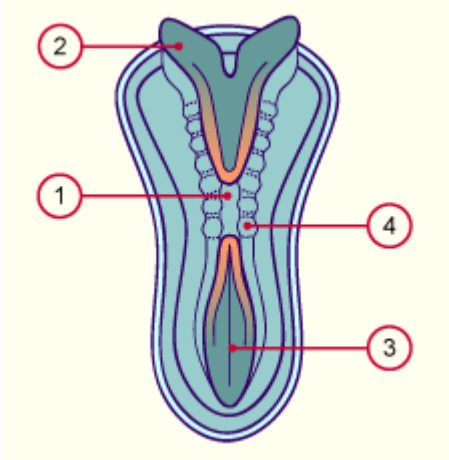
NEURAL TUBE:

- differentiates into the CNS

NEURAL CREST:

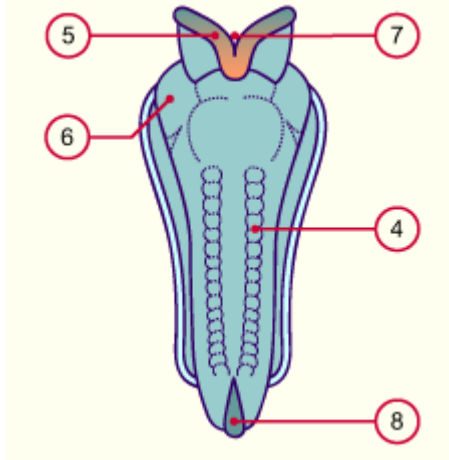
- gives rise to the cells that form most of the PNS and ANS

The neural tube at roughly the 28th day



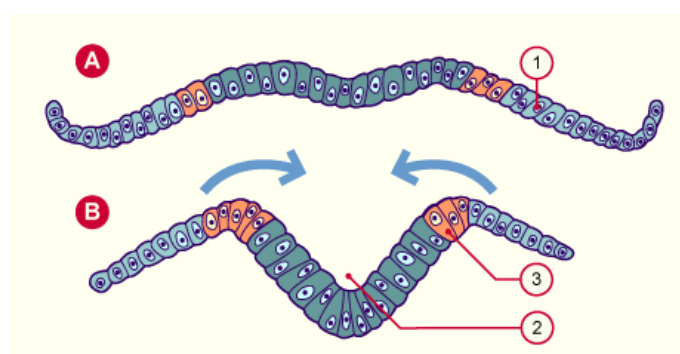
- 1 Neural tube
- 2 Neural fold
- 3 Neural groove
- 4 Somites

The neural tube at roughly the 29th day



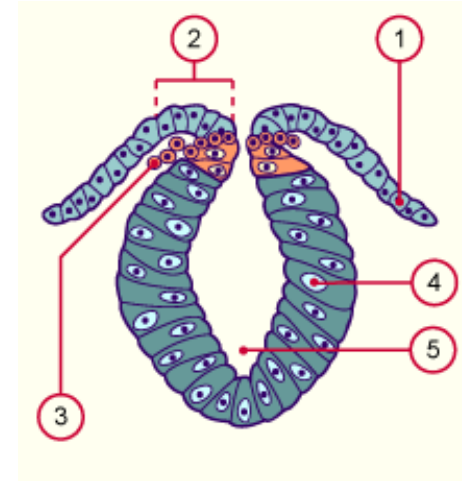
- 5 Neural crest
- 6 Protrusion of the pericardium
- 7 Cranial neuropore
- 8 Caudal neuropore

The forming neural crest (neural plate stage)



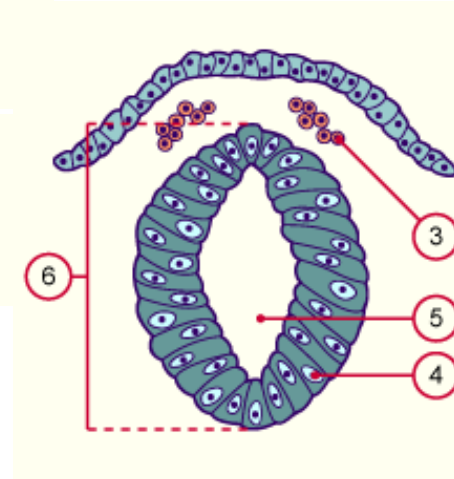
- A Neural plate stage
- B Neural groove stage
- 1 Epiblast
- 2 Neural groove
- 3 Neural crest

Migrating neural crest cells (neural groove stage)



- 1 Epiblast
- 2 Neural fold
- 3 Migrating neural crest cells

Neural crest after a completed detachment (neural tube stage)

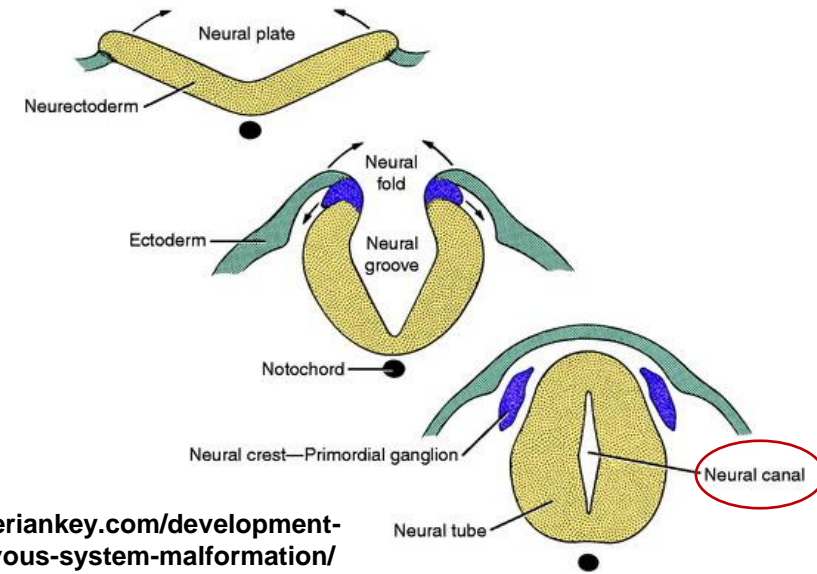


- 4 Neuroepithelium
- 5 Neural canal
- 6 Neural tube

ORIGIN OF NERVOUS SYSTEM

NEURULATION:

1. the NEURAL FOLDS start to fuse – formation of neural tube
2. the fusion of neural folds proceeds in cranial and caudal directions
3. a small area remain open at the cranial and caudal end
4. at the end the lumen of the neural tube – the NEURAL CANAL



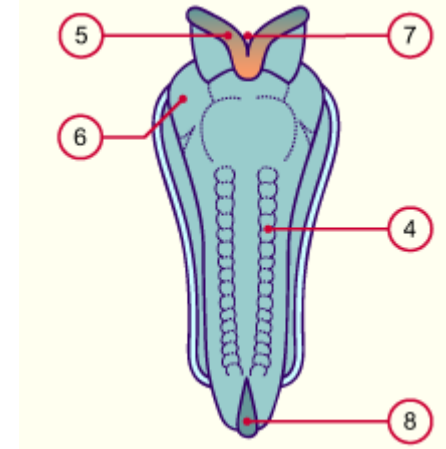
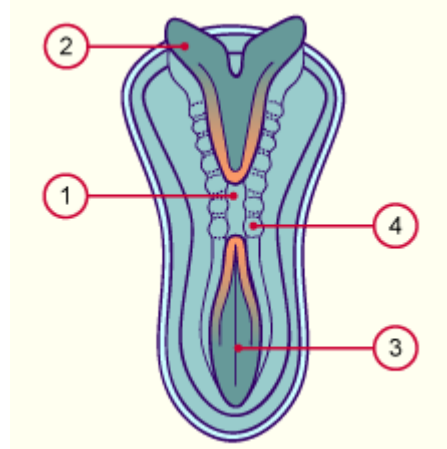
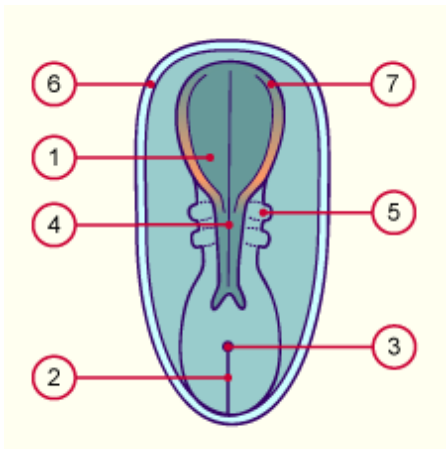
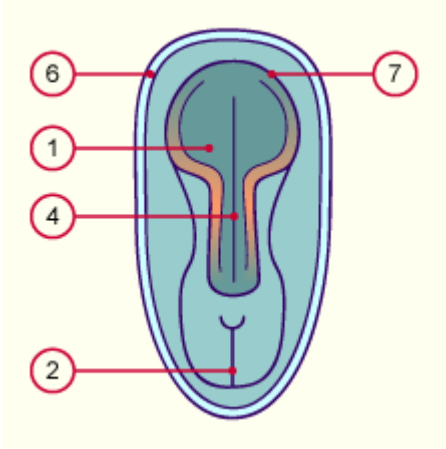
<https://veteriankey.com/development-of-the-nervous-system-malformation/>

Neural plate: 19 – 23rd day

Neural plate at roughly the 25th day

The neural tube at roughly the 28th day

The neural tube at roughly the 29th day



- 1 Neural plate
- 2 Primitive streak
- 3 Primitive nodes
- 4 Neural groove

- 5 Somites
- 6 Cut section of the amnion
- 7 Neural folds

- 1 Neural tube
- 2 Neural fold
- 3 Neural groove
- 4 Somites

- 5 Neural crest
- 6 Protrusion of the pericardium
- 7 Cranial neuropore
- 8 Caudal neuropore

ORIGIN OF NERVOUS SYSTEM

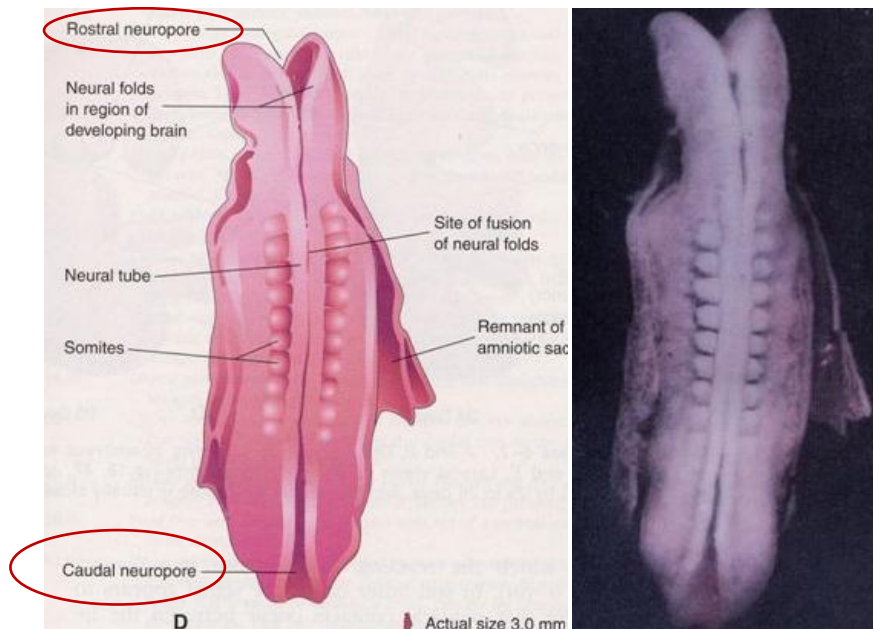
NEURULATION:

1. THE CRANIAL OPENING OF THE NEURAL TUBE:

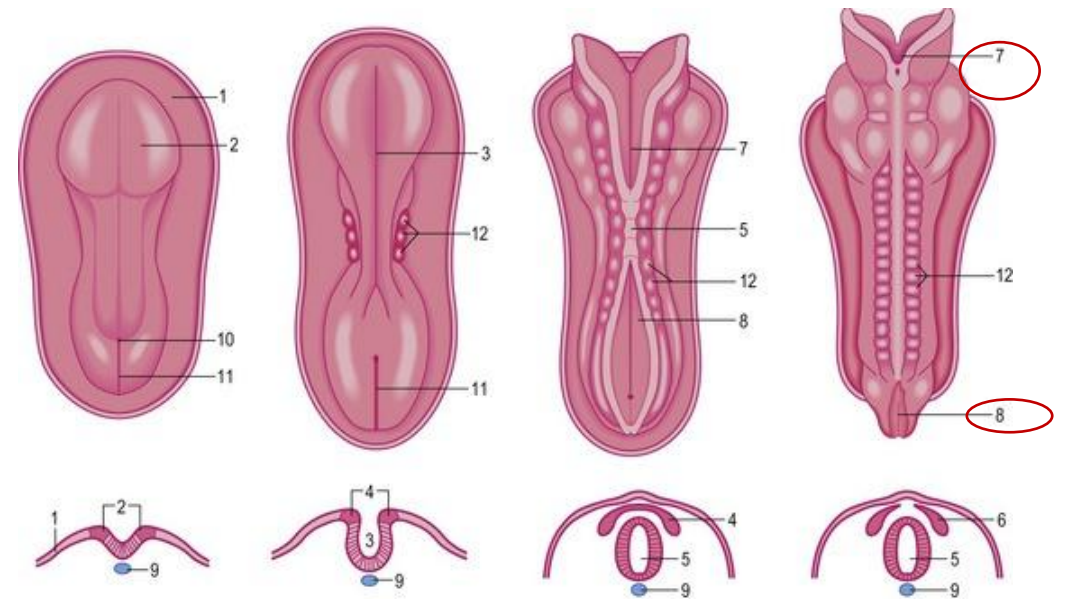
- rostral neuropore (NEUROPORUS ROSTRALIS)
- closes approximately the 25th day

2. THE CAUDAL OPENING OF THE NEURAL TUBE:

- caudal neuropore (NEUROPORUS CAUDALIS)
- closes the 27th day

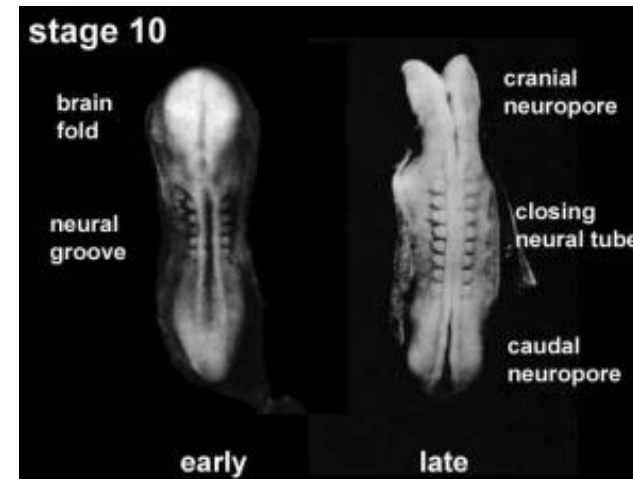


<https://slideplayer.com/slide/5270049/>



1: Surface ectoderm; 2: Neural plate; 3: Neural groove; 4: Neural crest; 5: Neural tube; 6: Spinal ganglion; 7: Anterior neuropore; 8: Posterior neuropore; 9: Notochord; 10: Primitive node; 11: Primitive streak; 12: Somites.

<https://veteriankey.com/neurulation/>



Neural groove closing to neural tube Embryo early week 4 ([Stage 10](#))

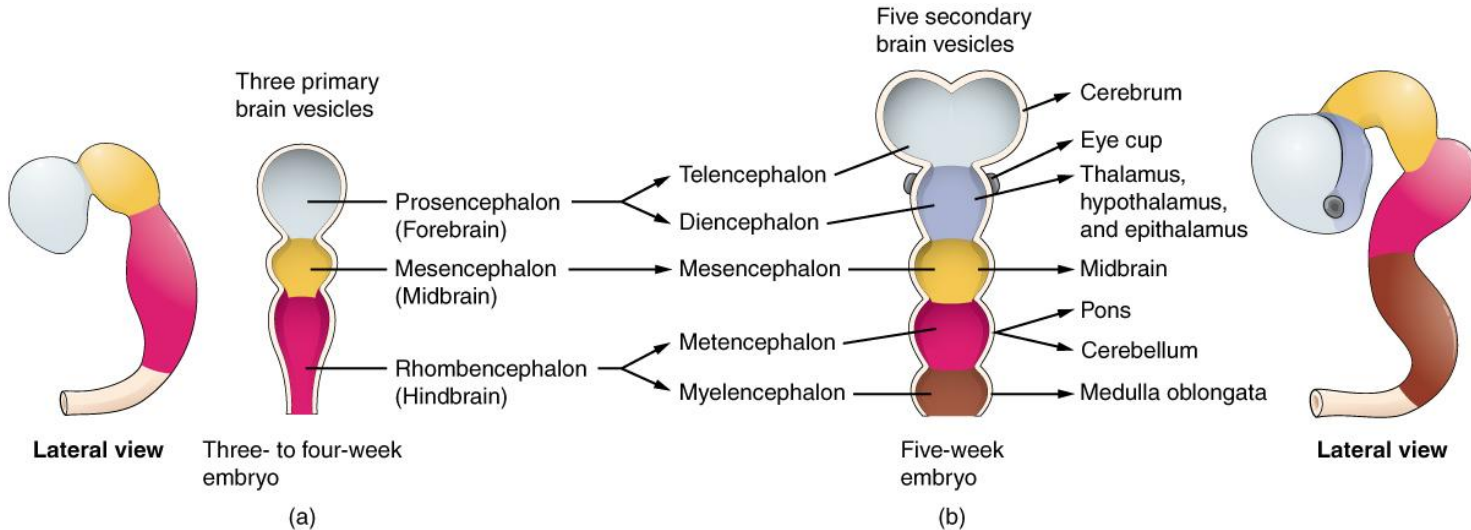
https://embryology.med.unsw.edu.au/embryology/index.php/Neural_-_Spinal_Cord_Development

ORIGIN OF NERVOUS SYSTEM

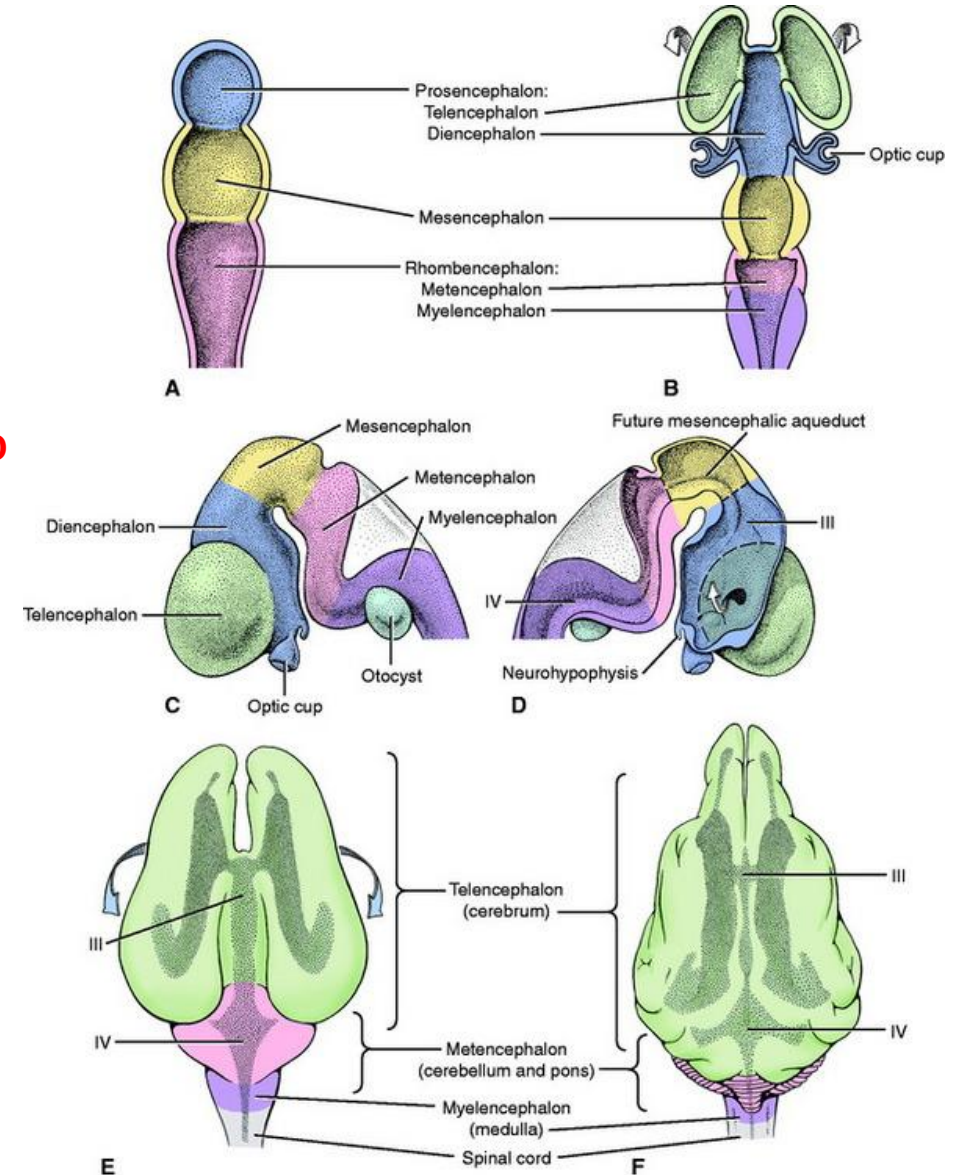
NEURULATION:

CLOSURE OF THE NEUROPORES:

- coincides with the establishment of the vascular circulation for the neural tube
- **THE WALLS of the neural tube thicken to form the BRAIN and THE SPINAL CORD**



<https://en.wikipedia.org/wiki/Brain Vesicle>



<https://veteriankey.com/development-of-the-nervous-system-malformation/>

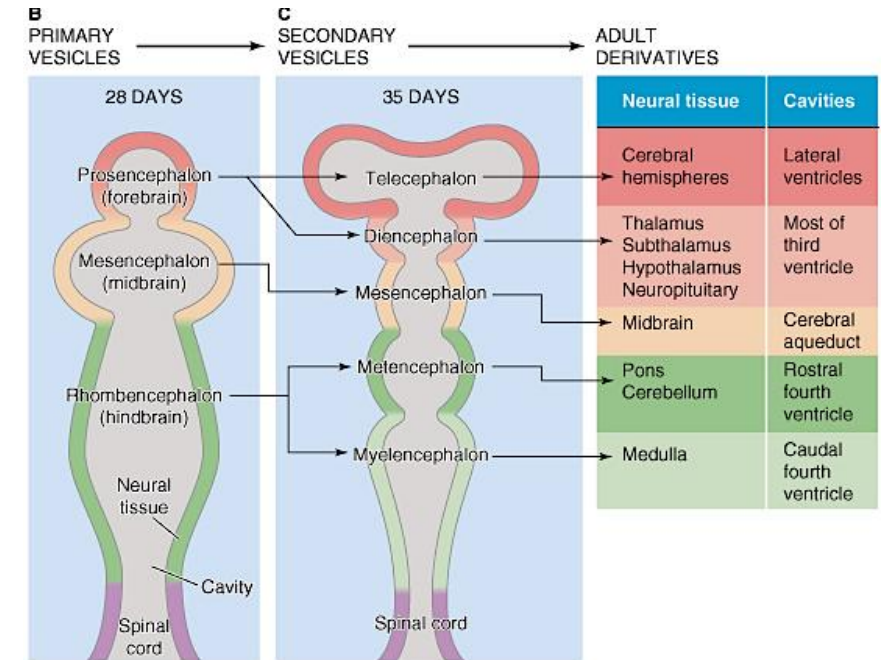
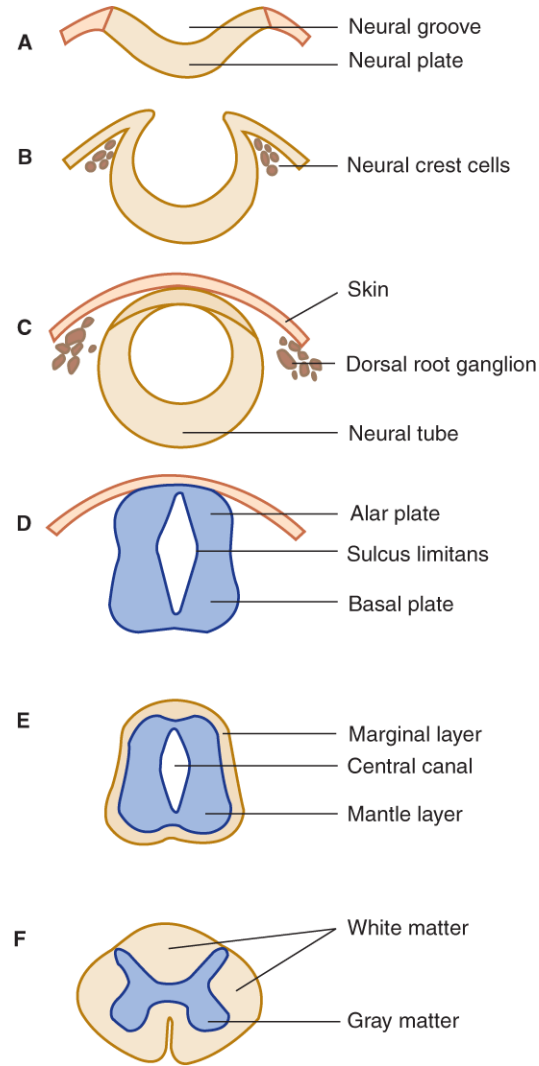
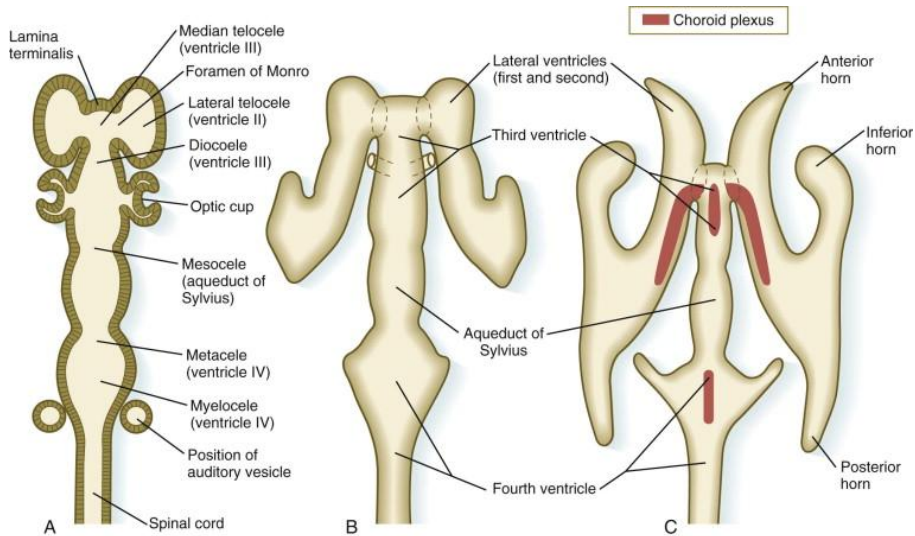
ORIGIN OF NERVOUS SYSTEM

NEURULATION:

- THE NEURAL CANAL forms:

a. THE VENTRICULAR SYSTEM of the brain

b. THE CENTRAL CANAL of the spinal cord



<http://brainmind.com/AbnormalBrainDevelopment.html>

Source: Waxman SG: *Clinical Neuroanatomy: Twenty-Seventh Edition*: www.accessmedicine.com
Copyright © The McGraw-Hill Companies, Inc. All rights reserved.

<https://www.sciencedirect.com/topics/veterinary-science-and-veterinary-medicine/ventricular-system>

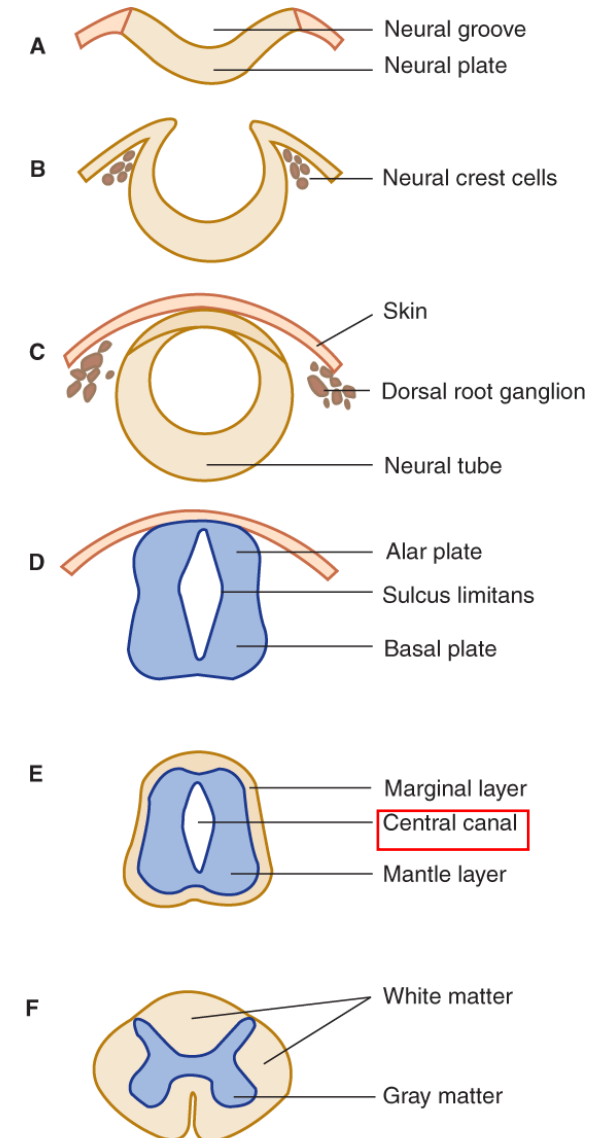
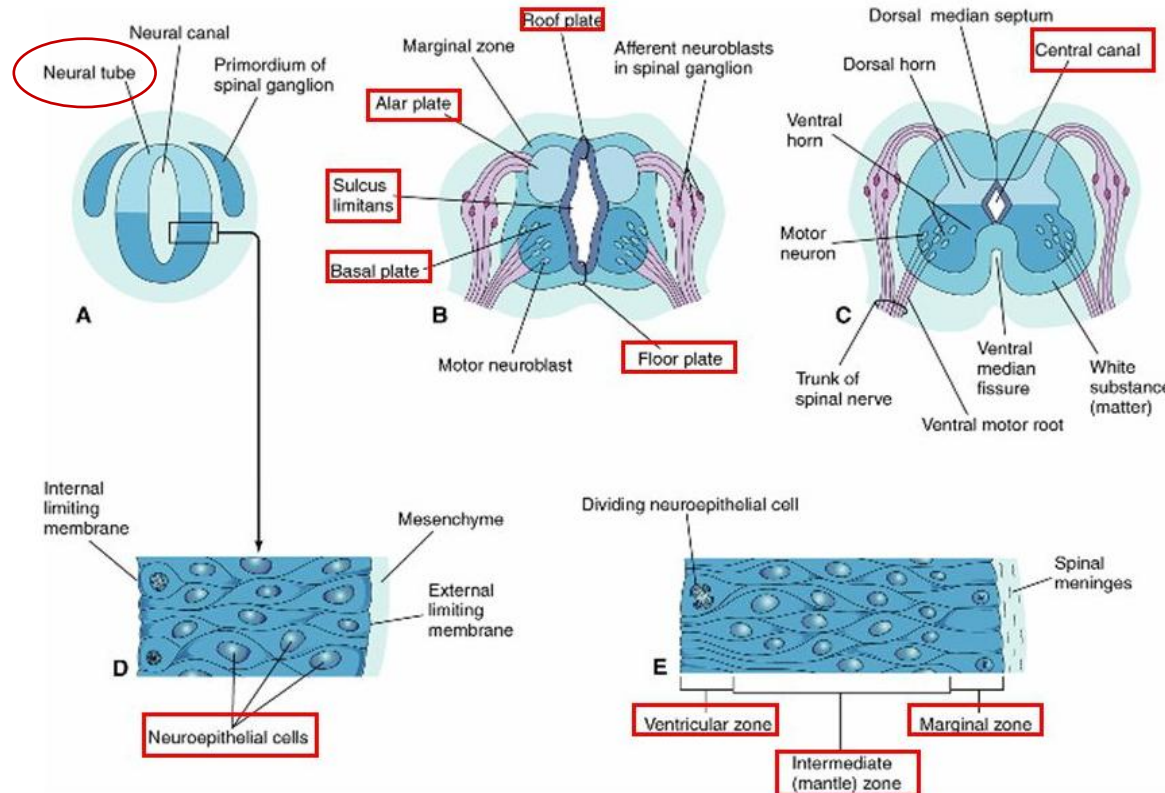
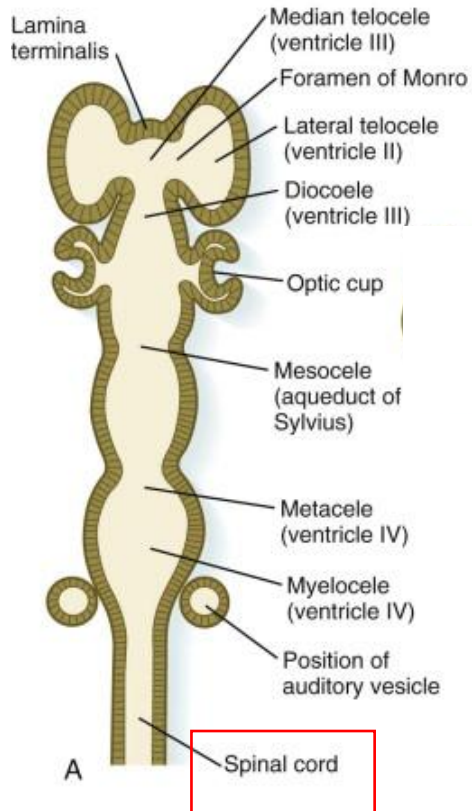
<https://www.digital-world-medical-school.net/01.%20Medical%20School/1.%201st/10.%20Organogenesis,%20Tissue%20Structure%20and%20Function/06.%20Nervous%20System/02.%20Structure/01.%20Central%20Nervous%20System/02.%20Spinal%20Cord/Spinal%20Cord.html>

DEVELOPMENT OF SPINAL CORD

- the neural tube caudal to the 4th pair of somites develops into the spinal cord

the lateral wall of the neural tube:

1. thicken
2. reduce the size of the neural canal to the CENTRAL CANAL



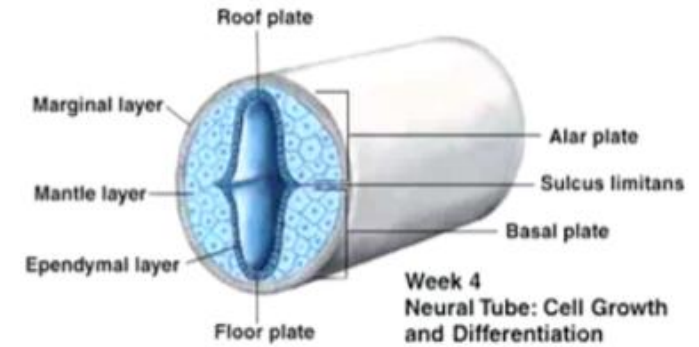
Source: Waxman SG: Clinical Neuroanatomy: Twenty-Seventh Edition: www.accessmedicine.com Copyright © The McGraw-Hill Companies, Inc. All rights reserved.

DEVELOPMENT OF SPINAL CORD

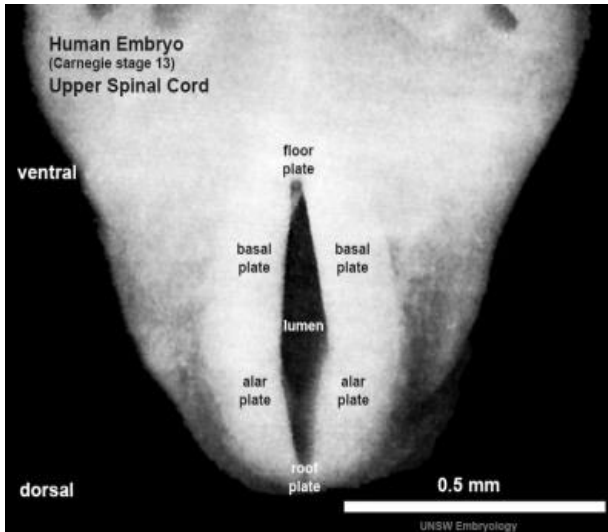
- the wall of the neural tube composed of pseudostratified columnar epithelium (neuroepithelium)
- the neuroepithelial cells constitute the EPENDYMAL LAYER (ventricular zone)

1. EPENDYMAL LAYER gives rise to:

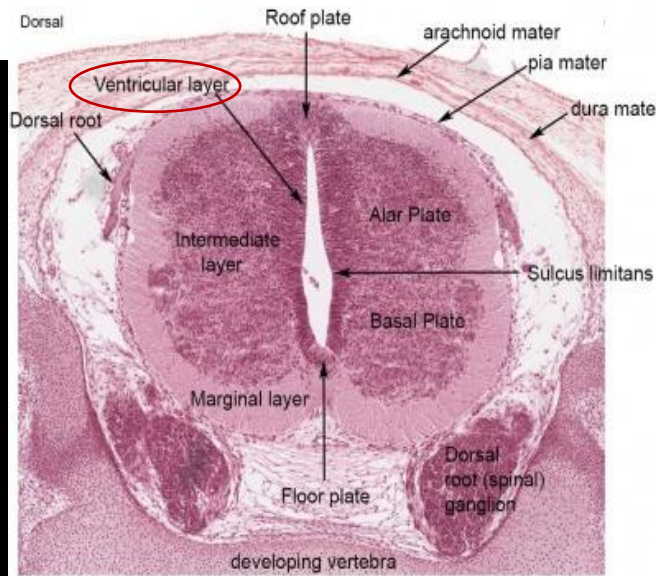
- all neurons
- macroglial cells (astrocytes, oligodendrocytes) in the spinal cord



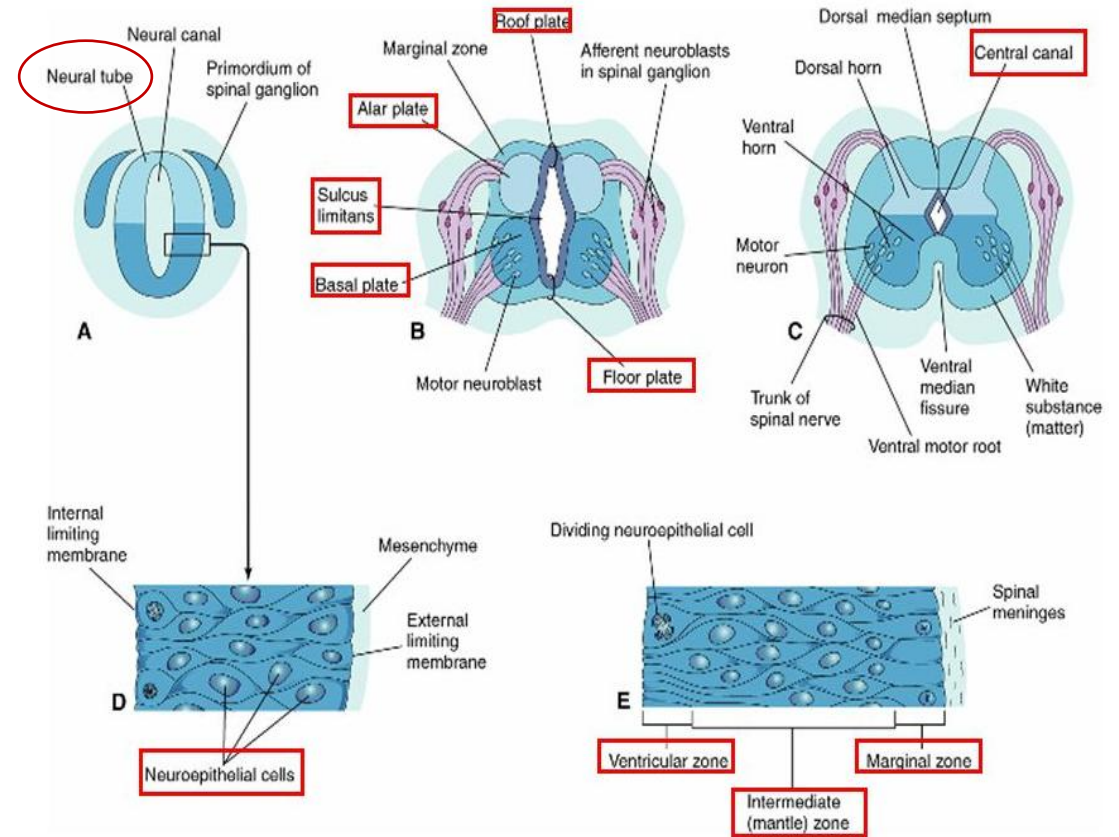
<https://quizlet.com/ca/267073367/embryology-head-and-neck-flash-cards/>



Stage 13 Spinal cord cross-section (upper part of cord).



Stage 22 Spinal cord cross-section (ventral is at bottom of image)



<https://slideplayer.com/slide/4948221/>

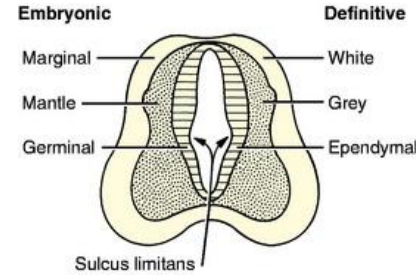
https://embryology.med.unsw.edu.au/embryology/index.php/Neural_-_Spinal_Cord_Development

DEVELOPMENT OF SPINAL CORD

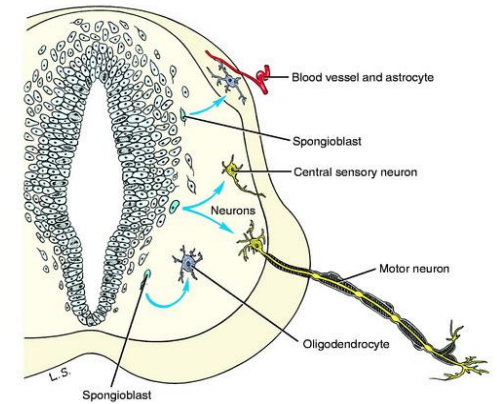
- some epithelial cells in the ventricular zone differentiate into **NEUROBLASTS**

2. NEUROBLASTS form the INTERMEDIATE ZONE (mantle layer):

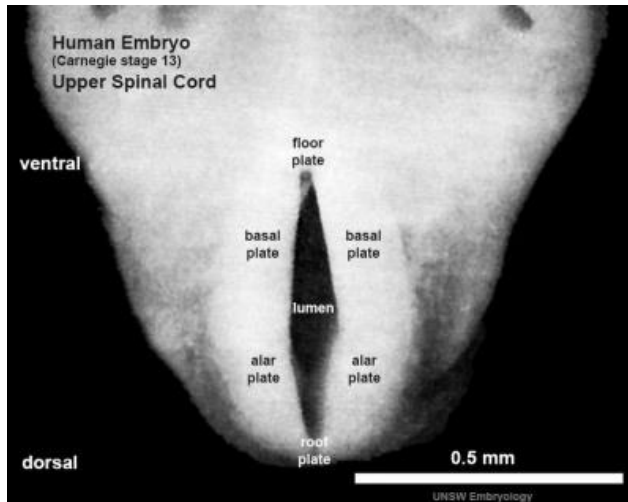
- neuroblasts become neurones with cytoplasmic processes



<https://veteriankey.com/development-of-the-nervous-system-malformation/>

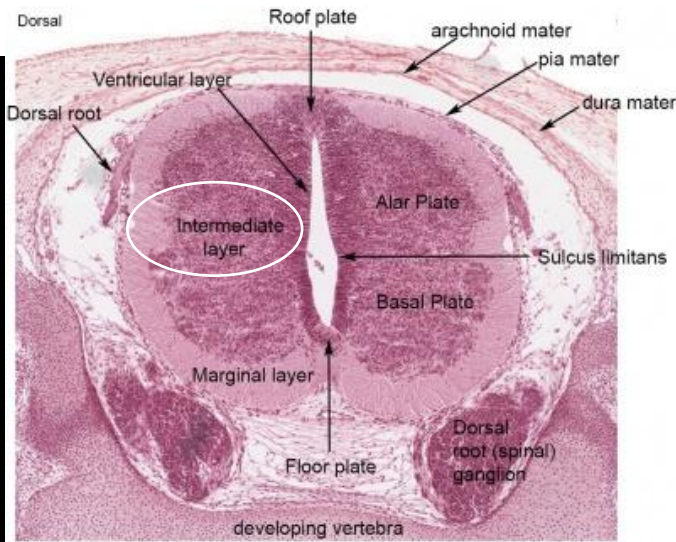


<https://veteriankey.com/development-of-the-nervous-system-malformation/>

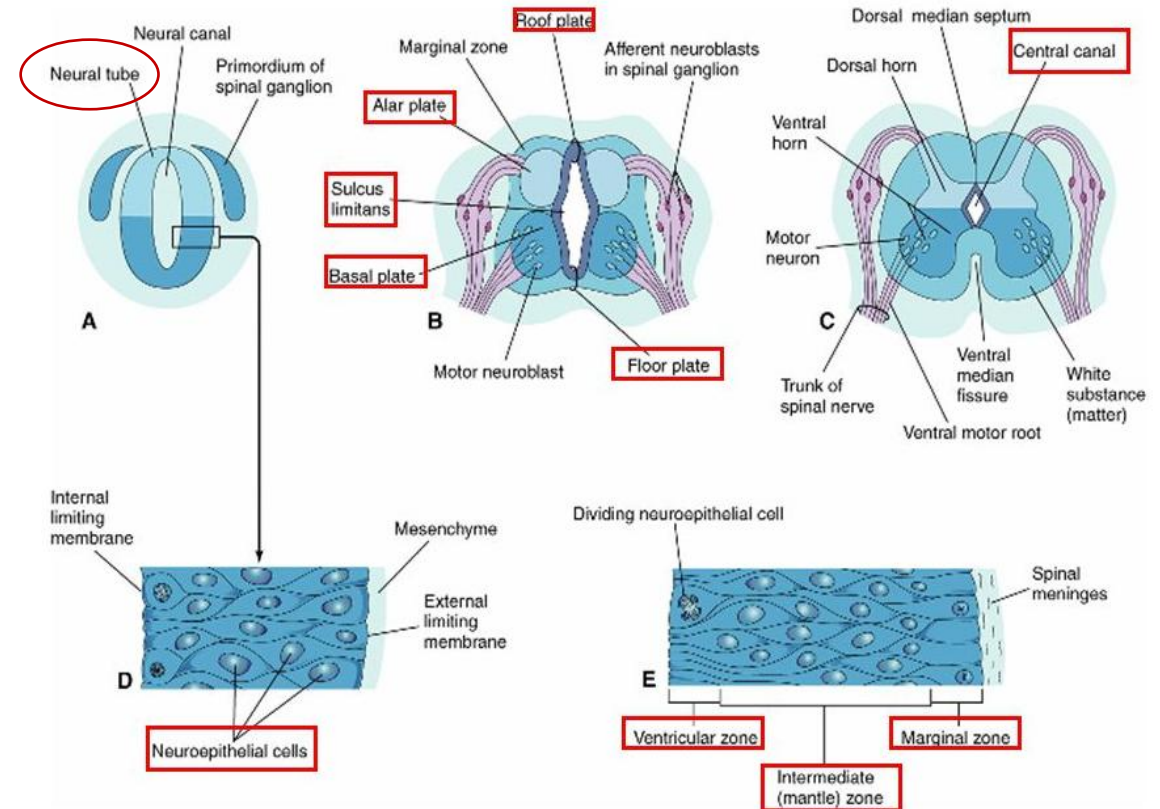


Stage 13 Spinal cord cross-section (upper part of cord).

https://embryology.med.unsw.edu.au/embryology/index.php/Neural_-_Spinal_Cord_Development



Stage 22 Spinal cord cross-section (ventral is at bottom of image)



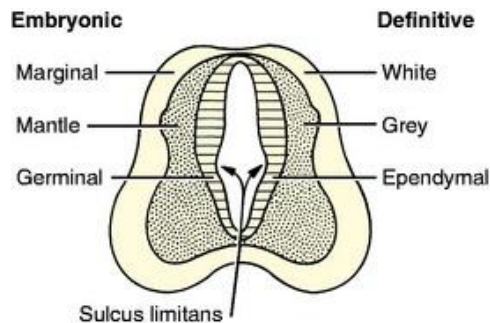
<https://slideplayer.com/slide/4948221/>

DEVELOPMENT OF SPINAL CORD

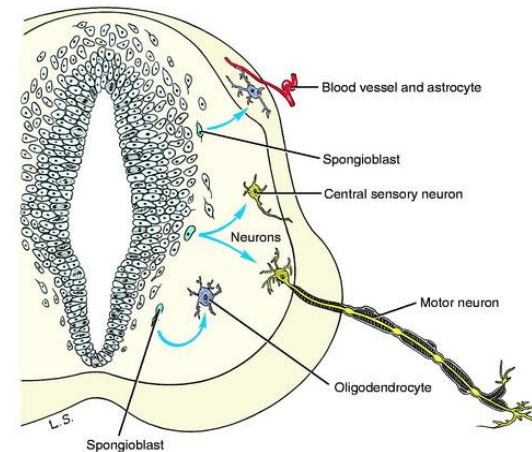
- outer part of epithelial cells constitute the MARGINAL ZONE

3. MARGINAL ZONE becomes the:

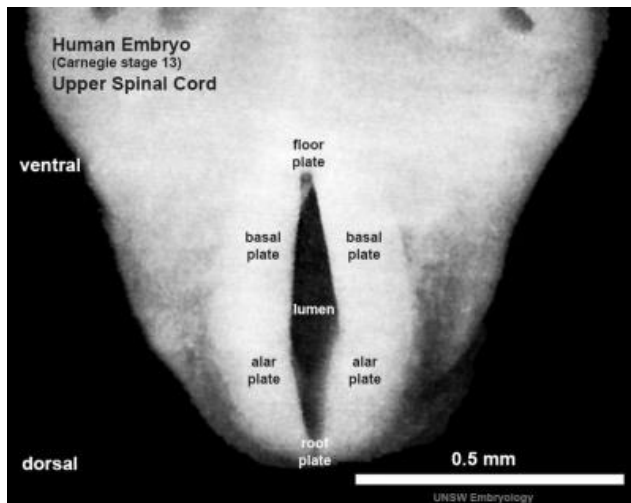
a. white matter of spinal cord



<https://veteriankey.com/development-of-the-nervous-system-malformation/>

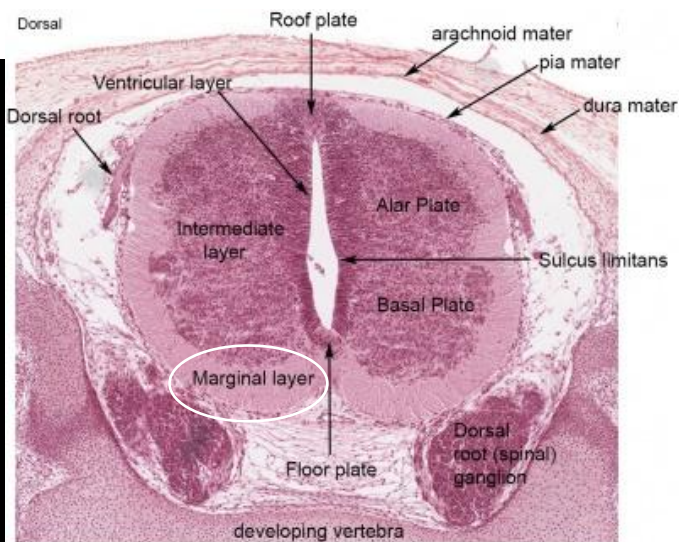


<https://veteriankey.com/development-of-the-nervous-system-malformation/>

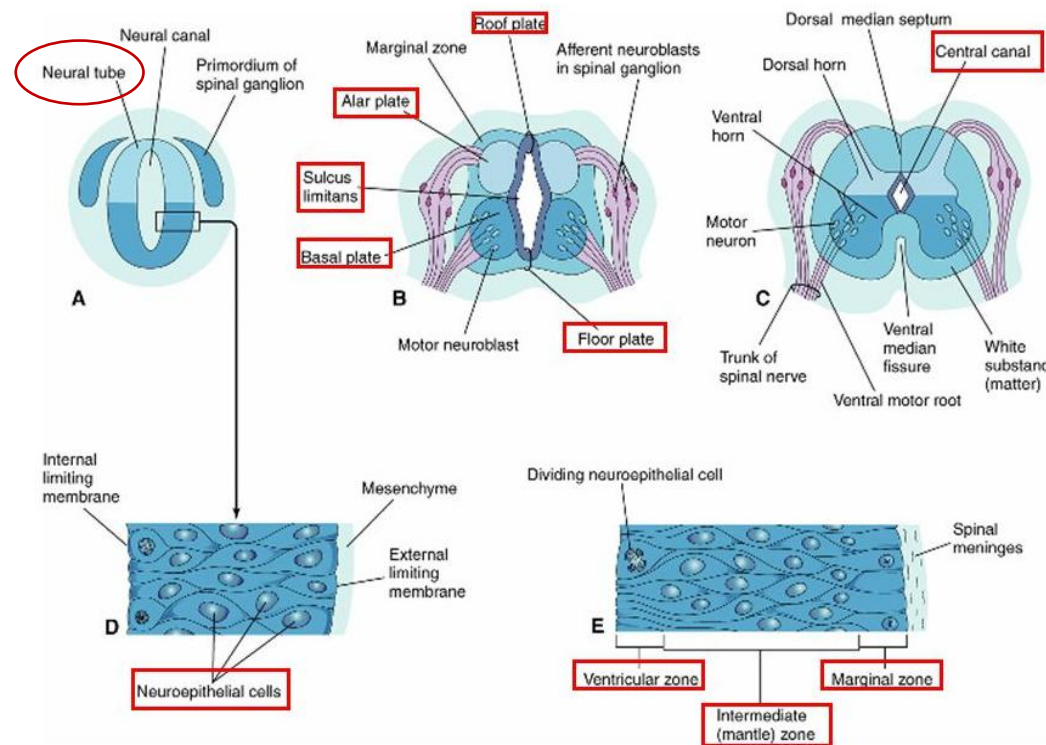


Stage 13 Spinal cord cross-section (upper part of cord).

https://embryology.med.unsw.edu.au/embryology/index.php/Neural_-_Spinal_Cord_Development



Stage 22 Spinal cord cross-section (ventral is at bottom of image)

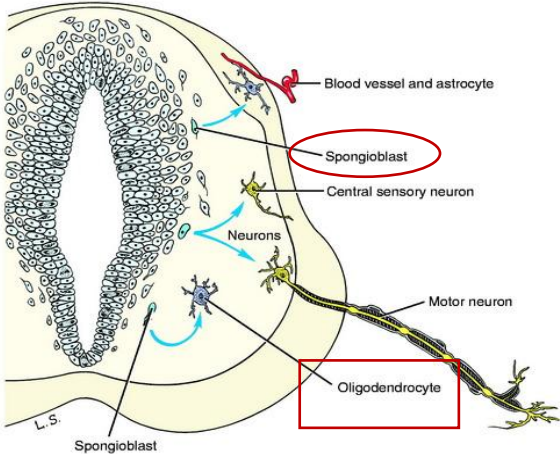
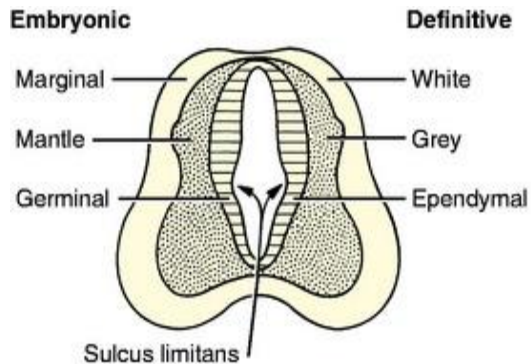


<https://slideplayer.com/slide/4948221/>

DEVELOPMENT OF SPINAL CORD

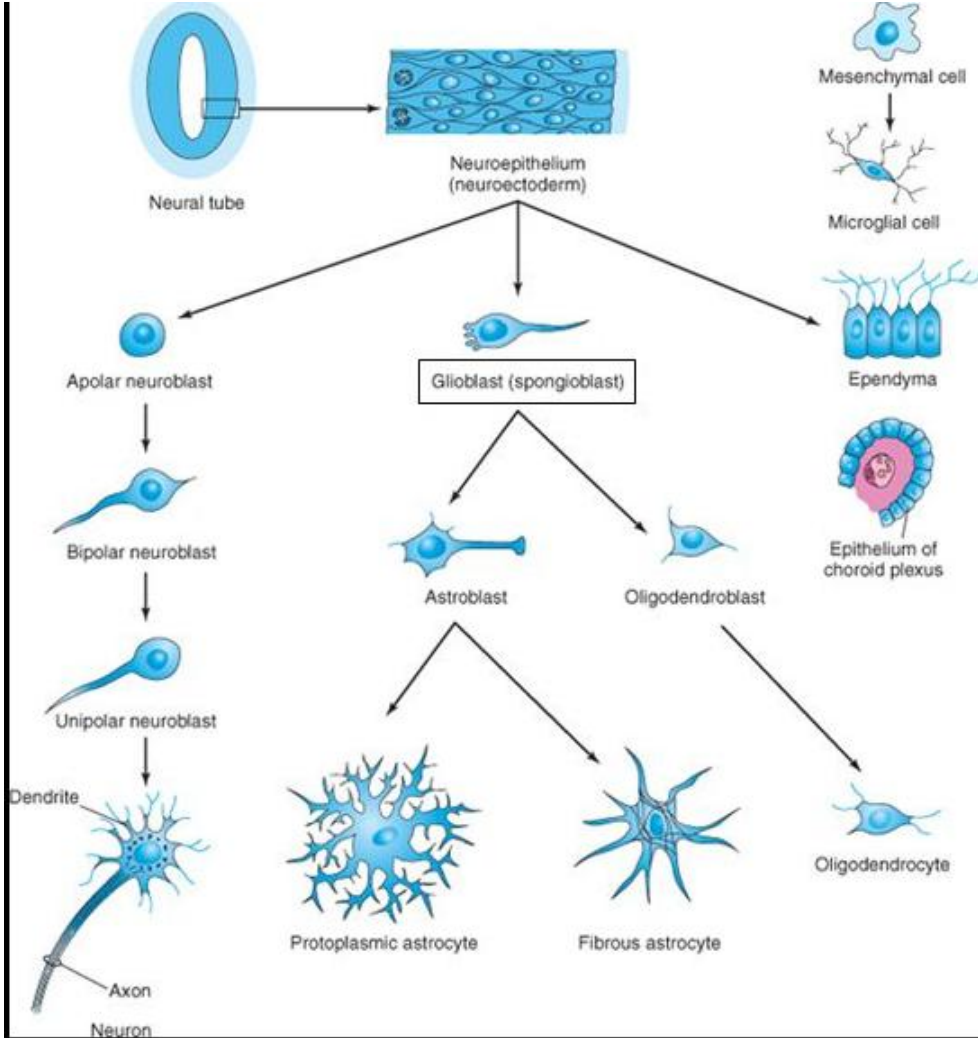
GLIOBLASTS (SPONGIOBLASTS):

- supporting cells of CNS
 - differentiate from the neuroepithelial cells
 - they migrate from the ventricular zone – into the intermediate zone – and marginal zone
1. some glioblasts become – astroblast – than astrocytes
 2. some glioblasts become oligodendroblasts – than oligodendrocytes
 3. some neuroepithelial cells become ependyma – lining the central canal of the spinal cord



<https://veteriankey.com/development-of-the-nervous-system-malformation/>

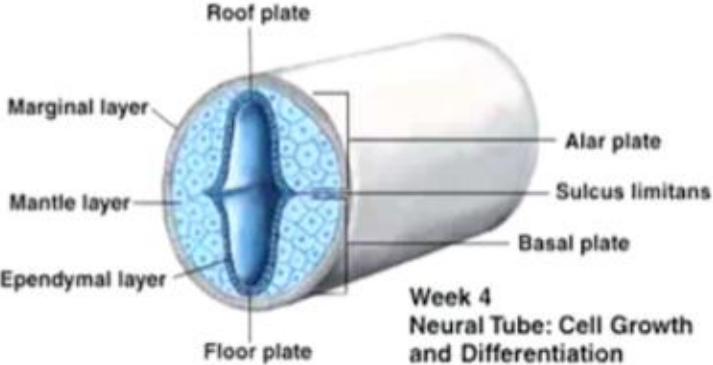
<https://veteriankey.com/development-of-the-nervous-system-malformation/>



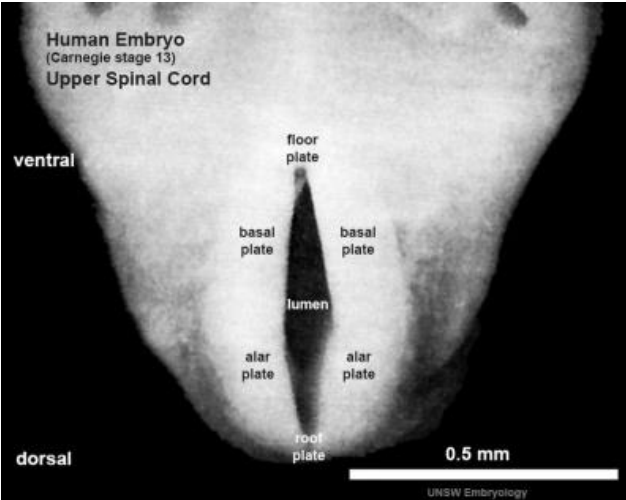
DEVELOPMENT OF SPINAL CORD

- proliferation and differentiation of neuroepithelial cells in the developing spinal cord produce:

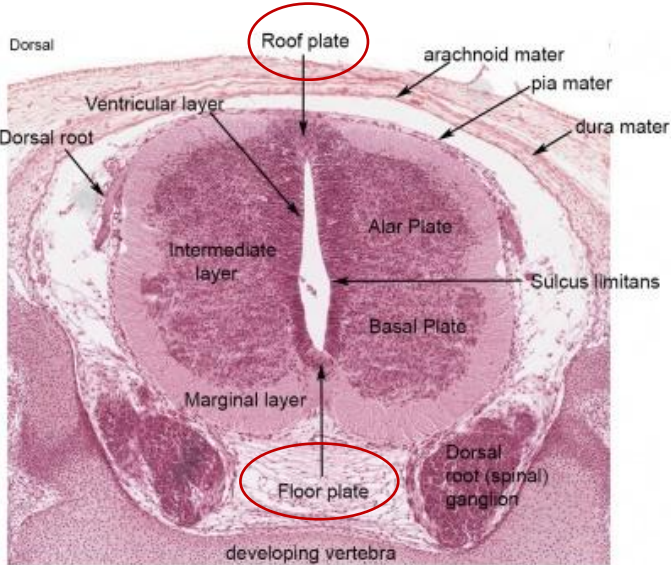
1. thick walls
2. thin roof plate
3. thin floor plate



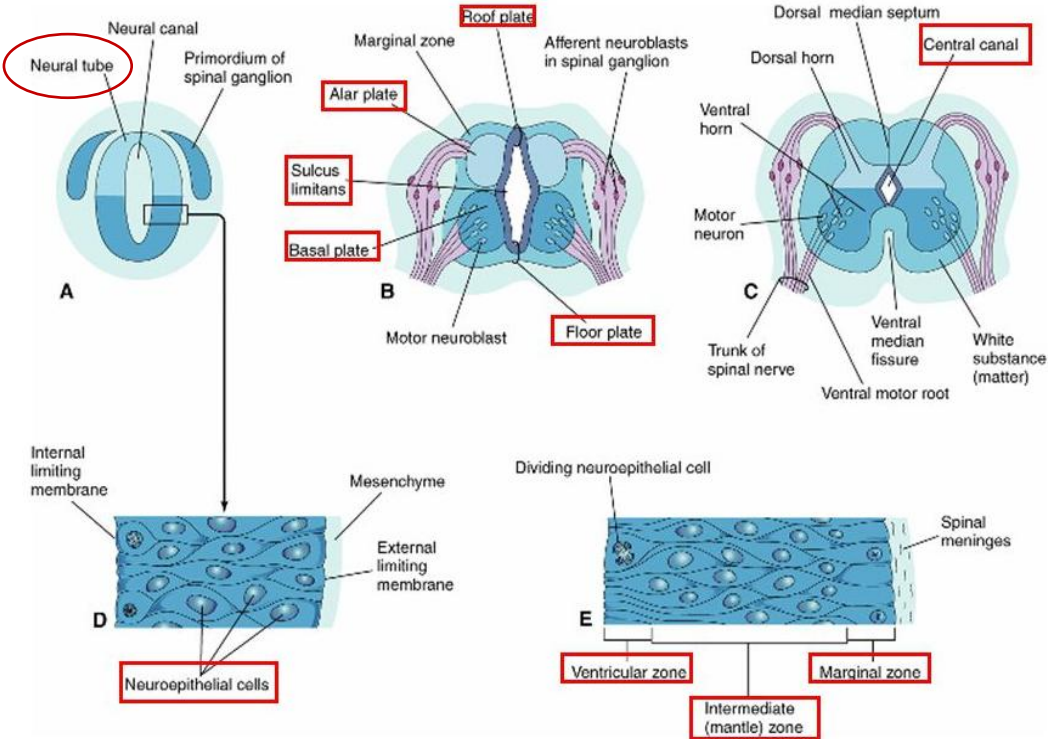
<https://quizlet.com/ca/267073367/embryology-head-and-neck-flash-cards/>



Stage 13 Spinal cord cross-section (upper part of cord).



Stage 22 Spinal cord cross-section (ventral is at bottom of image)



<https://slideplayer.com/slide/4948221/>

https://embryology.med.unsw.edu.au/embryology/index.php/Neural_-_Spinal_Cord_Development

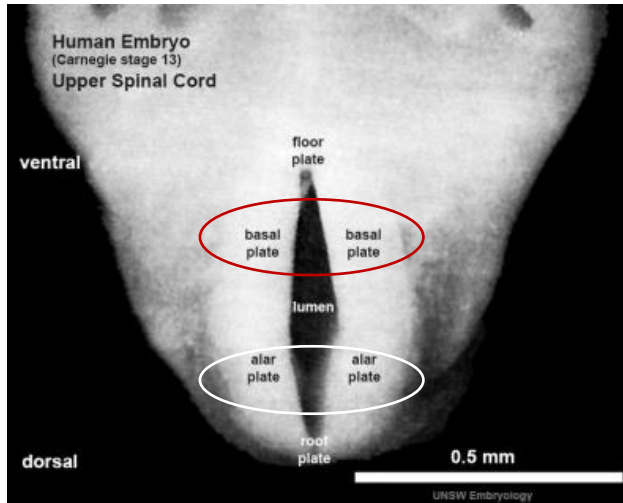
DEVELOPMENT OF SPINAL CORD

THICKENING OF THE LATERAL WALLS produce:

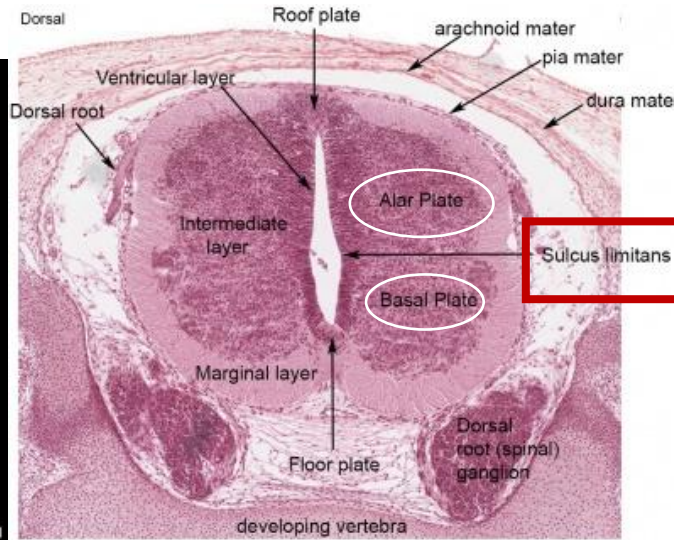
- one each side the **SULCUS LIMITANS**

SULCUS LIMITANS separates:

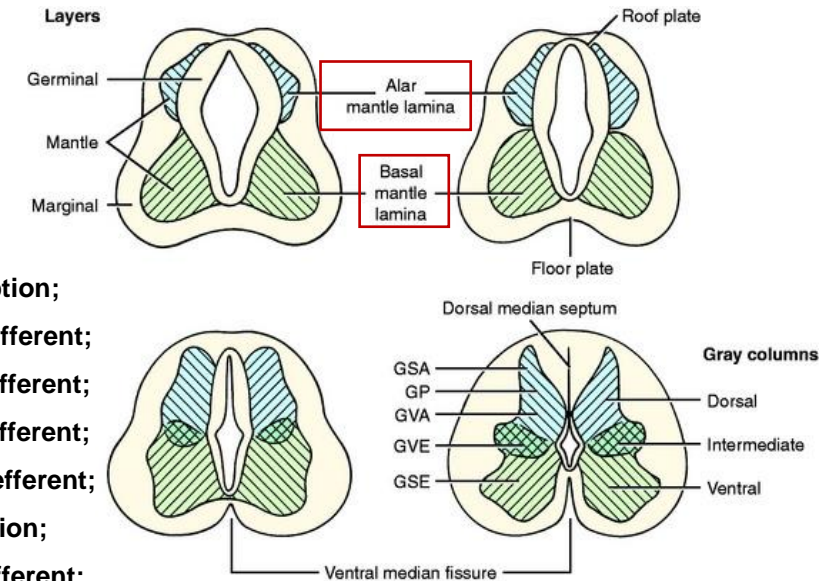
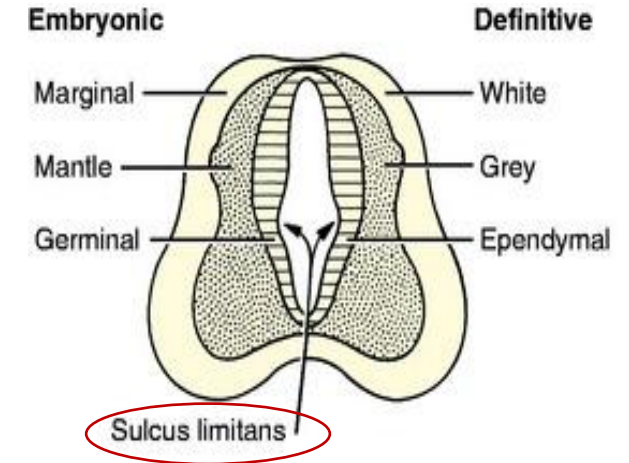
- the **ALAR PLATE** from **BASAL PLATE**
- the alar and basal plate associated with afferent and efferent functions



Stage 13 Spinal cord cross-section (upper part of cord).



Stage 22 Spinal cord cross-section (ventral is at bottom of image)



- GP**, General proprioception;
- GSA**, general somatic afferent;
- GSE**, general somatic efferent;
- GVA**, general visceral afferent;
- GVE**, general visceral efferent;
- SP**, special proprioception;
- SSA**, special somatic afferent;
- SVA**, special visceral afferent.

<https://veteriankey.com/development-of-the-nervous-system-malformation/>

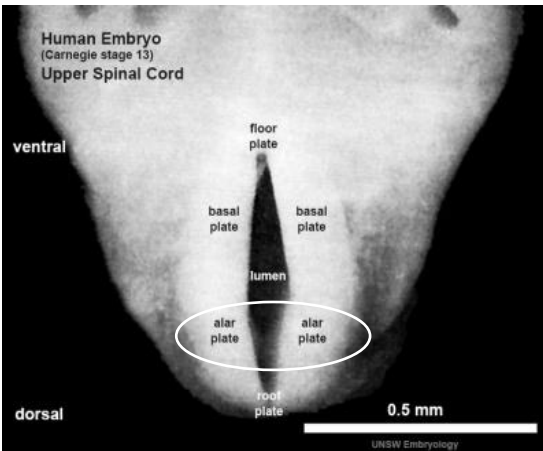
DEVELOPMENT OF SPINAL CORD

ALAR PLATE:

- cell bodies in the alar plates form the **DORSAL GRAY COLUMNS**

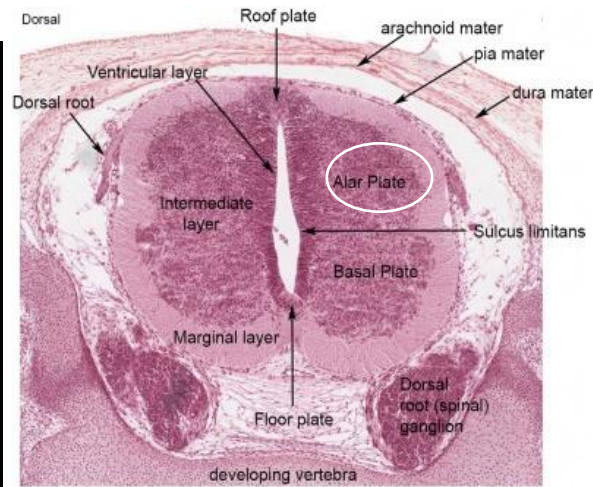
in transverse section – these columns are:

1. the dorsal grey horns

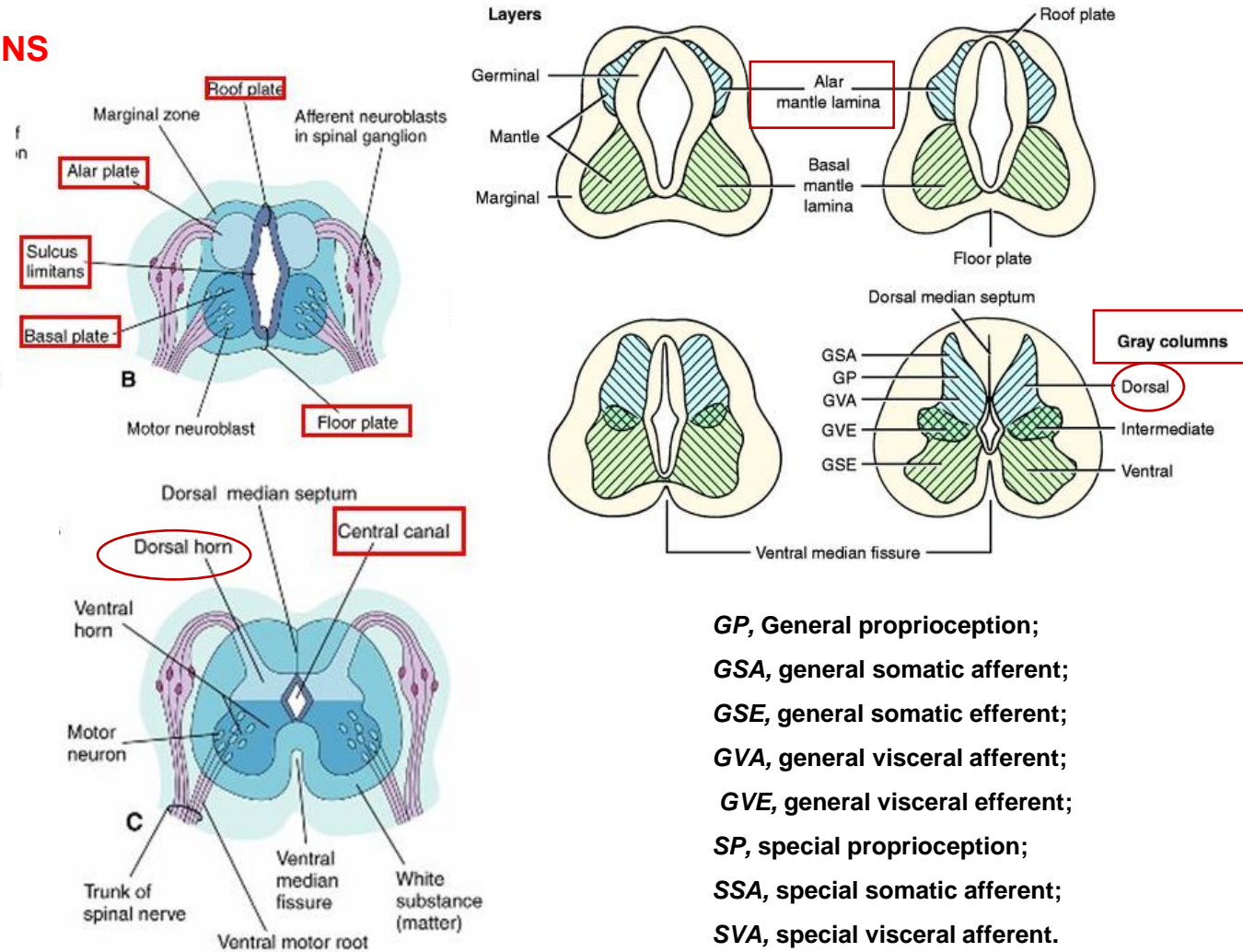


Stage 13 Spinal cord cross-section (upper part of cord).

https://embryology.med.unsw.edu.au/embryology/index.php/Neural_-_Spinal_Cord_Development



Stage 22 Spinal cord cross-section (ventral is at bottom of image)



<https://slideplayer.com/slide/4948221/>

DEVELOPMENT OF SPINAL CORD

BASAL PLATE:

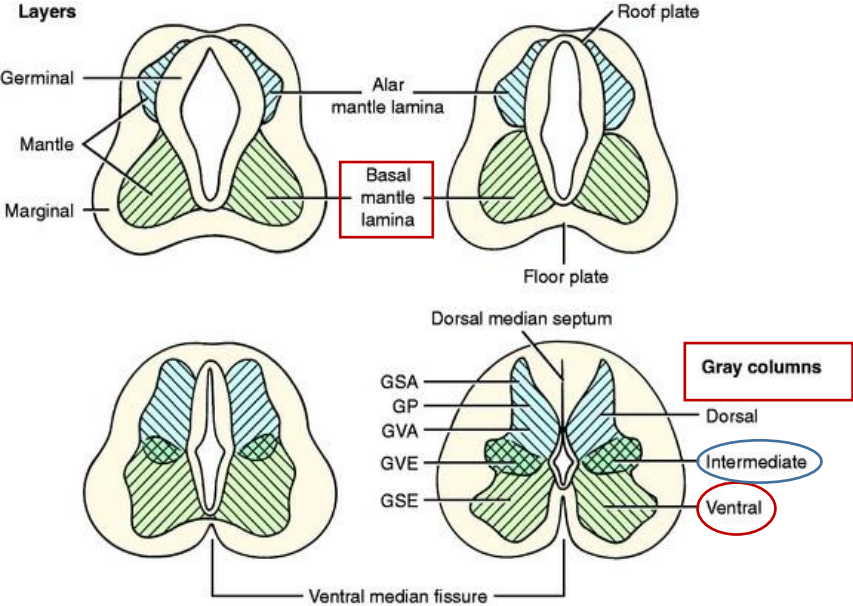
- cell bodies in the basal plates form the ventral and lateral gray columns

in transverse section these columns are:

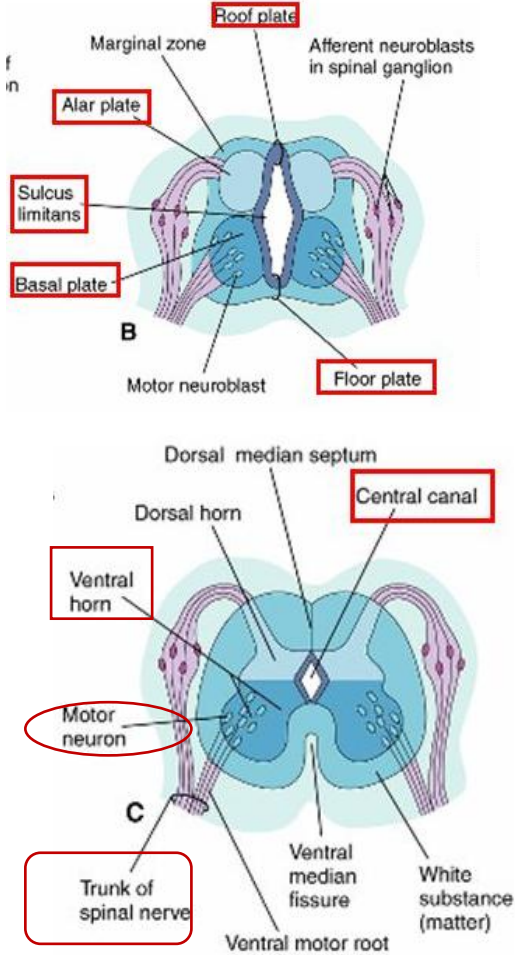
1. the ventral grey horns
2. the lateral gray horns

AXONS from the ventral horn cells:

- grow out of the cord
- form the ventral roots of the spinal nerves



GP, General proprioception;
GSA, general somatic afferent;
GSE, general somatic efferent;
GVA, general visceral afferent;
GVE, general visceral efferent;
SP, special proprioception;
SSA, special somatic afferent;
SVA, special visceral afferent.

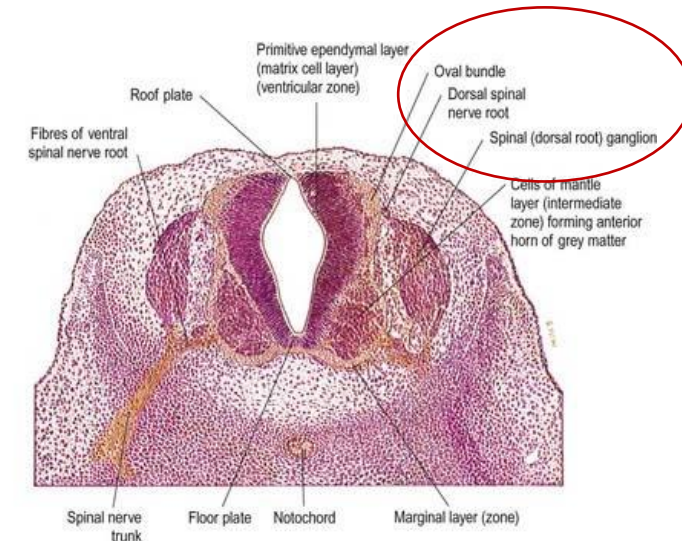


DEVELOPMENT OF SPINAL GANGLIA

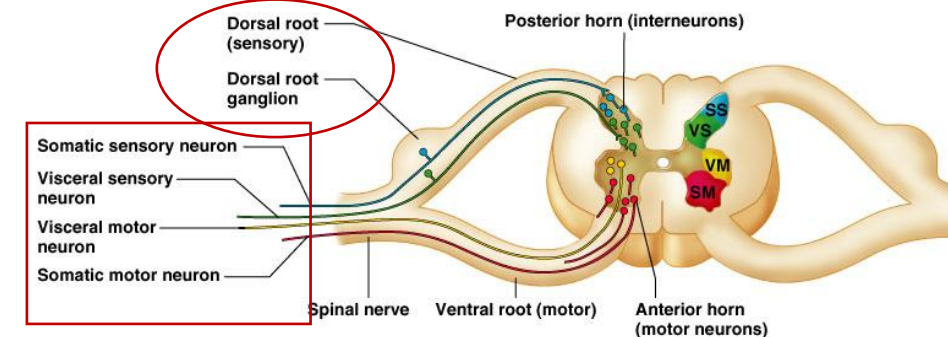
- the unipolar neurons in the spinal ganglia (dorsal root ganglia) **derived from neural crest cells**

a. the peripheral processes of the spinal ganglion cells pass in the spinal nerves to sensory endings in somatic or visceral structures

b. the central processes enter the spinal cord – constituting the dorsal roots of the spinal nerves

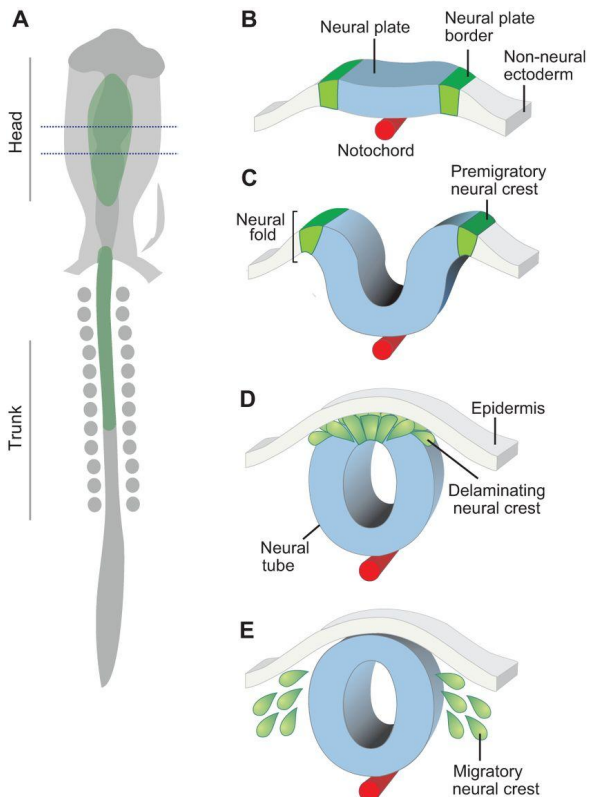


<https://clinicalgate.com/development-of-the-nervous-system-4/>



Copyright © 2004 Pearson Education, Inc., publishing as Benjamin Cummings.

http://www.profelis.org/vorlesungen/neuroanatomy_3.html



F Neural crest derivatives

Mesenchymal cells

- Chondroblasts/chondrocytes
- Osteoblasts/osteocytes
- Fibroblasts
- Odontoblasts
- Cardiac mesenchyme
- Myoblasts
- Adipocytes

Neuronal cells

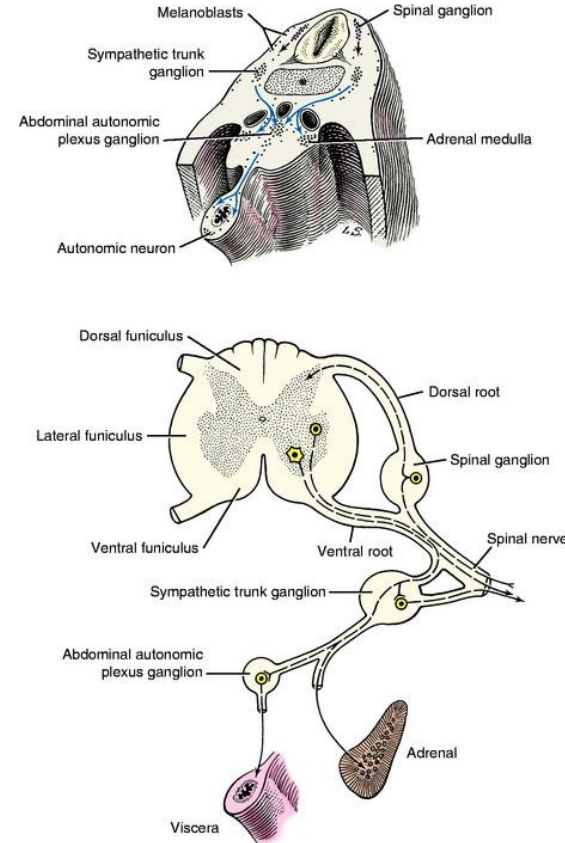
- Sensory neurons
- Cholinergic neurons
- Adrenergic neurons
- Satellite cells
- Schwann cells
- Glial cells

Secretory cells

- Chromaffin cells
- Parafollicular cells
- Calcitonin-producing cells

Pigmented cells

- Melanocytes



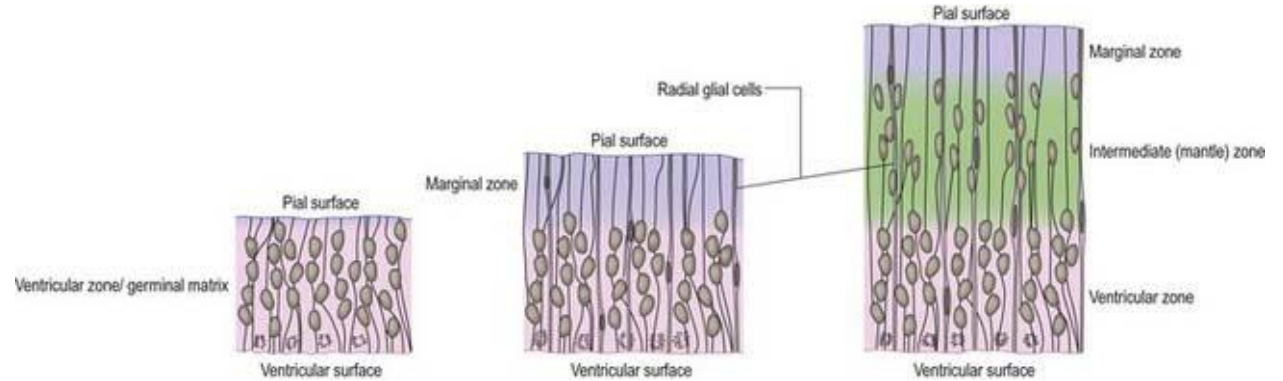
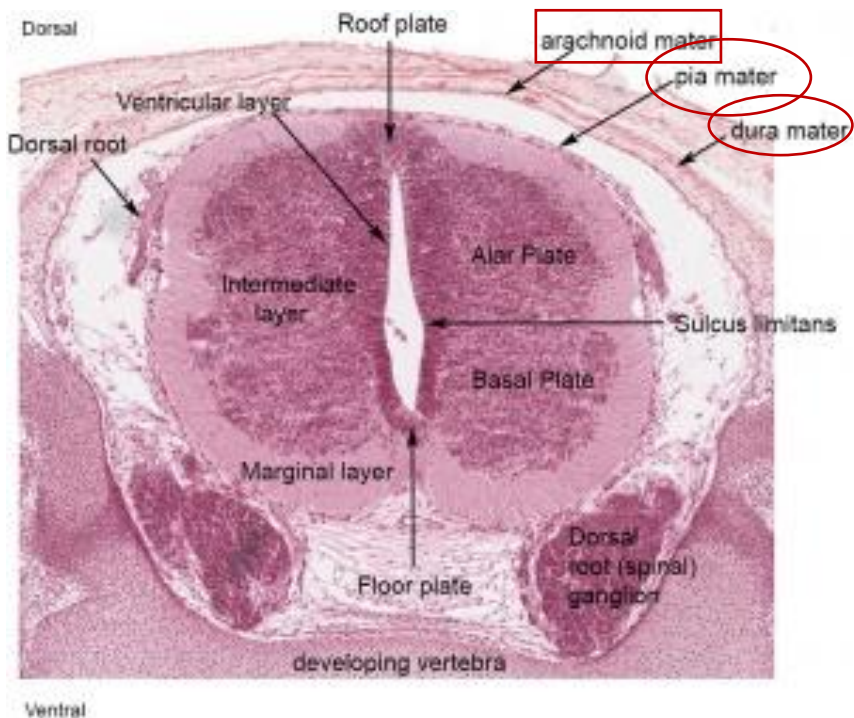
<http://dev.biologists.org/content/142/2/242>

<https://veteriankey.com/development-of-the-nervous-system-malformation/>

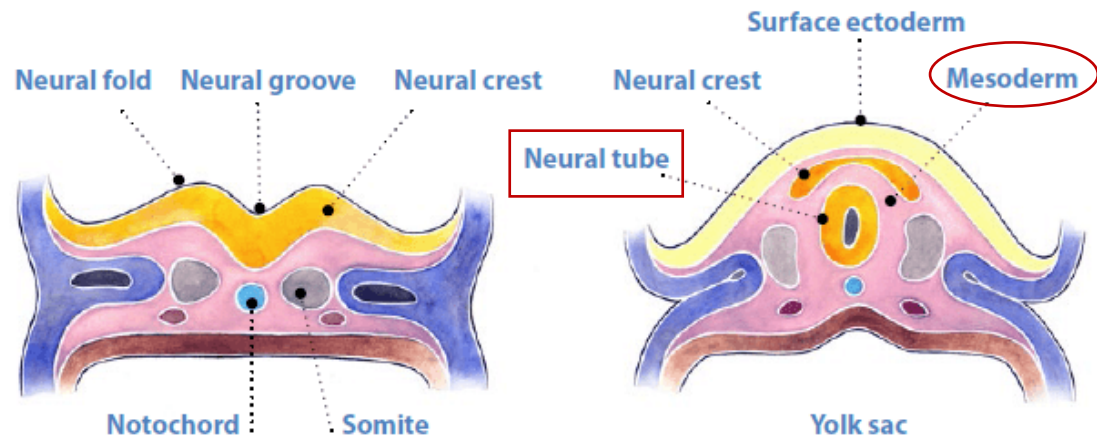
DEVELOPMENT OF SPINAL MENINGES

- **mesenchyme surrounding the neural tube** condenses to form the primordial meninges

1. the external layer gives rise to the **dura mater**
2. the internal layer gives rise to **pia mater**
3. neural crest cells give rise to **arachnoid mater**



<https://clinicalgate.com/development-of-the-nervous-system-4/>



<https://www.cdc.gov/ncbddd/birthdefects/surveillancemanual/photo-atlas/nervous.html>

DEVELOPMENT OF BRAIN

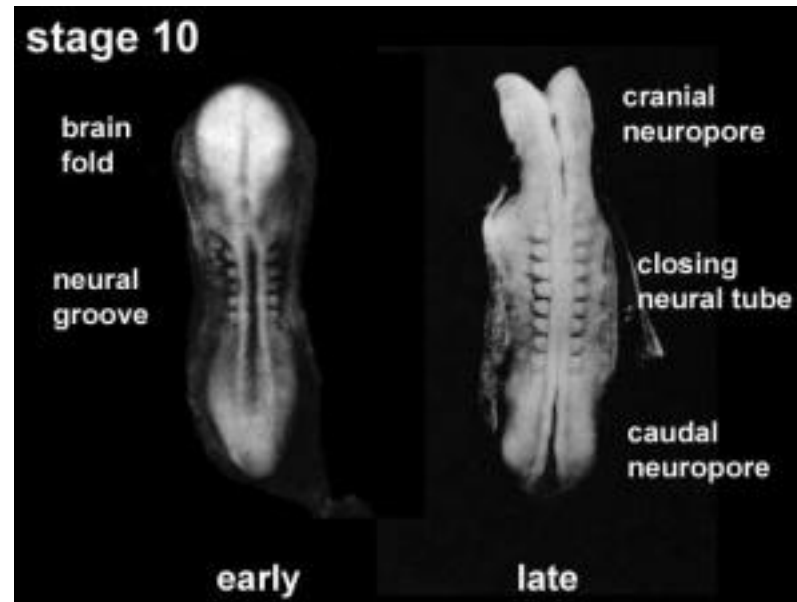
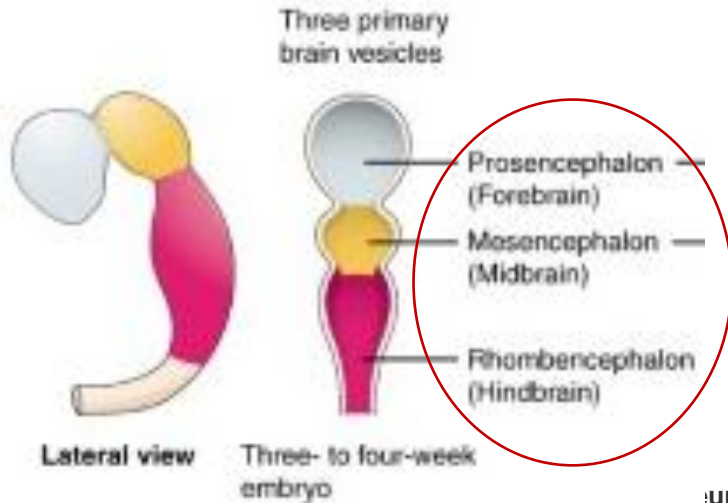
- the neural tube cranial to the 4th pair of somites develops into brain

before the neural folds completely fused:

- 3 vesicles are recognizable in the rostral end of the neural tube

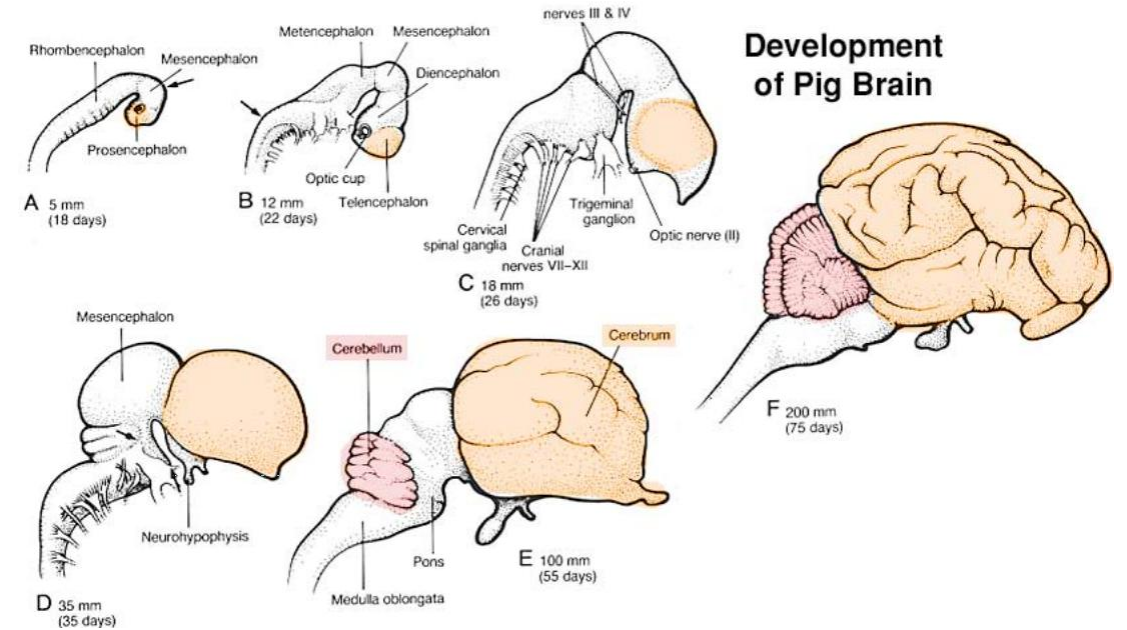
FROM ROSTRAL TO CAUDAL PRIMARY BRAIN VESICLES form the:

1. FOREBRAIN (PROSENCEPHALON)
2. MIDBRAIN (MESENCEPHALON)
3. HINDBRAIN (RHOMBENCEPHALON)



neural groove closing to neural tube Embryo early week 4 ([Stage 10](#))

https://embryology.med.unsw.edu.au/embryology/index.php/Neural_-_Spinal_Cord_Development



Development of Pig Brain

<http://vanat.cvm.umn.edu/NeuroLectPDFs/LectNeuroEmbr.pdf>

DEVELOPMENT OF BRAIN

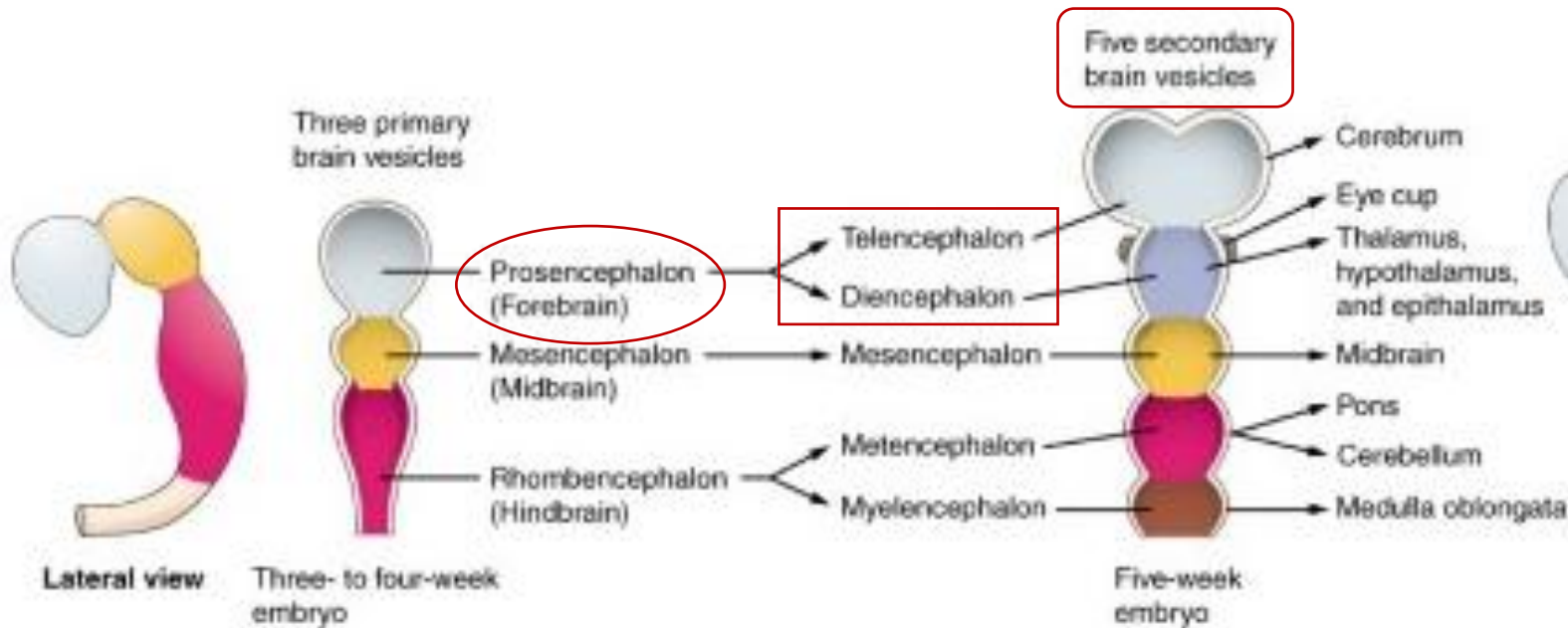
FOREBRAIN (PROSENCEPHALON):

- during the 5th week the forebrain partially divides into:

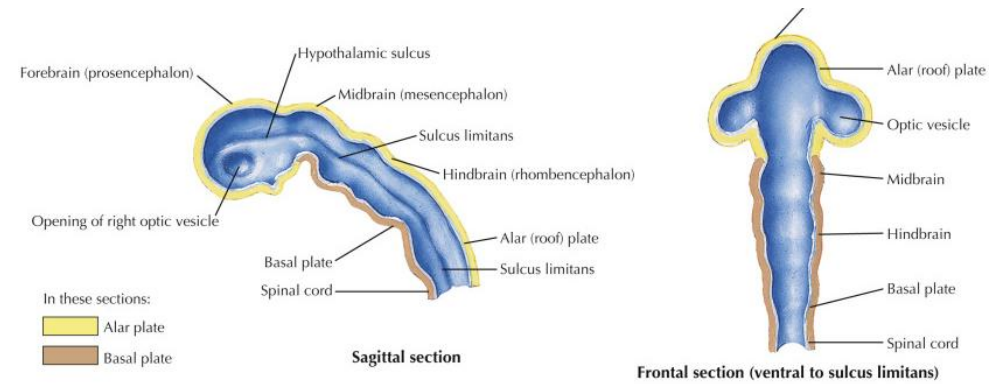
a. TELENCEPHALON

b. DIENCEPHALON

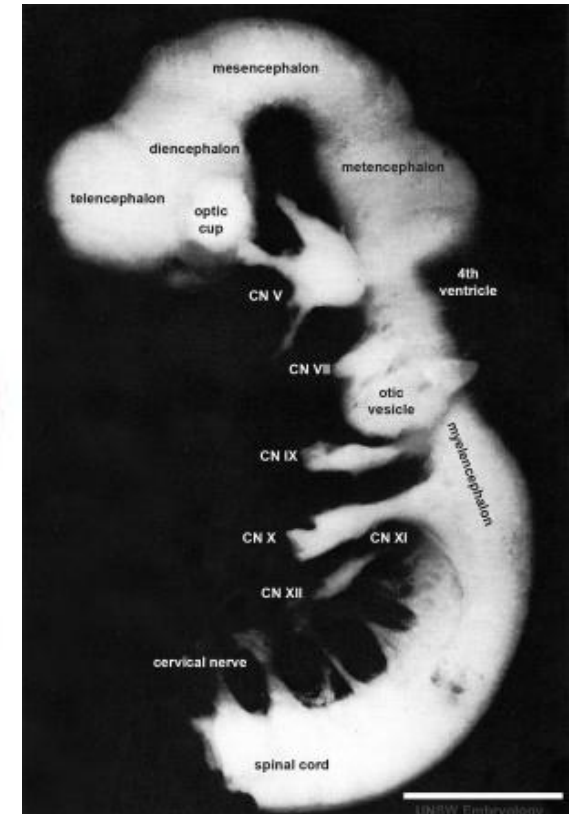
SECONDARY BRAIN VESICLES



<https://www.learnmedicalneuroscience.nl/study-tips-brain-development/>



<https://www.sciencedirect.com/topics/neuroscience/cephalic-flexure>



https://embryology.med.unsw.edu.au/embryology/index.php/Neural_System_Development

DEVELOPMENT OF BRAIN

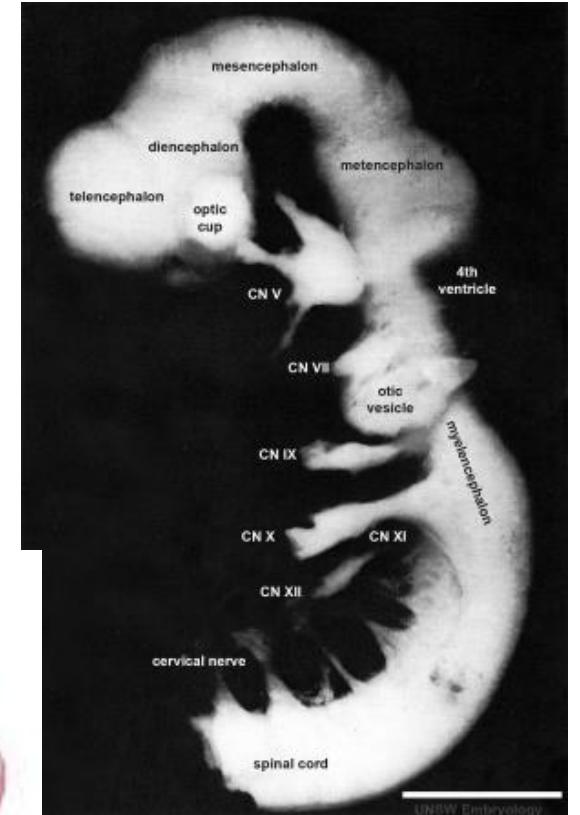
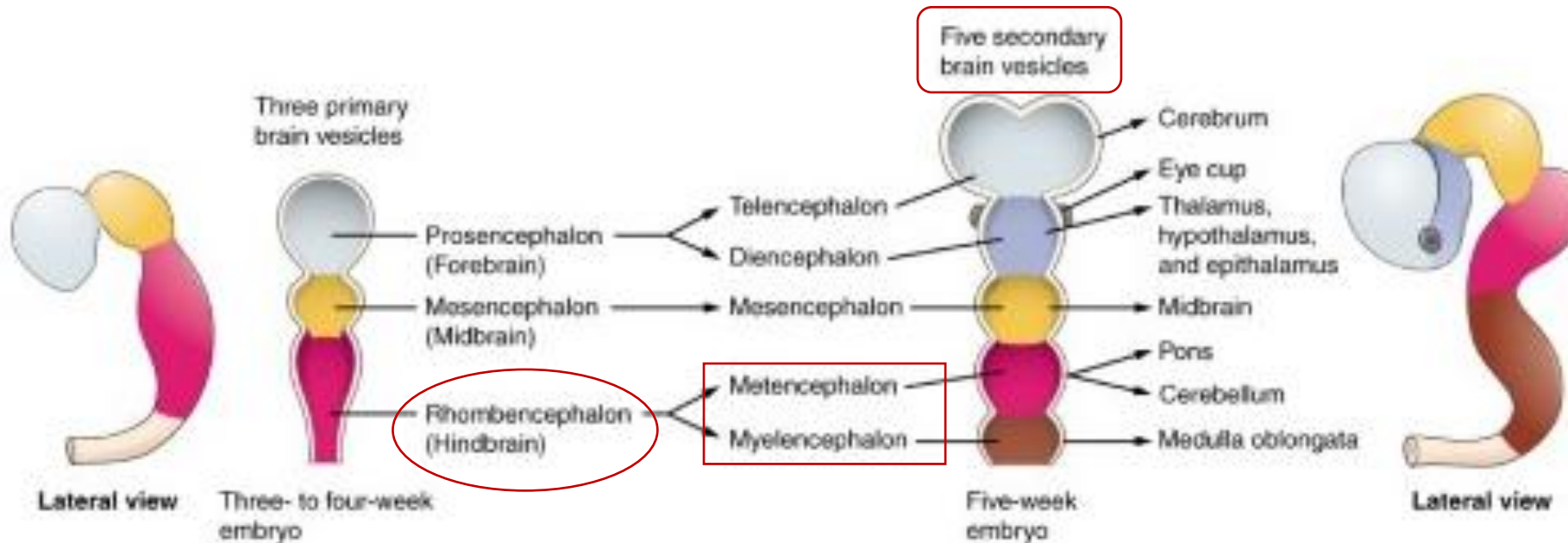
HINDBRAIN (RHOMBENCEPHALON):

divides into:

a. METENCEPHALON

b. MYELENCEPHALON

SECONDARY BRAIN VESICLES



https://embryology.med.unsw.edu.au/embryology/index.php/Neural_System_Development

<https://www.learnmedicalneuroscience.nl/study-tips-brain-development/>

BRAIN FLEXURES

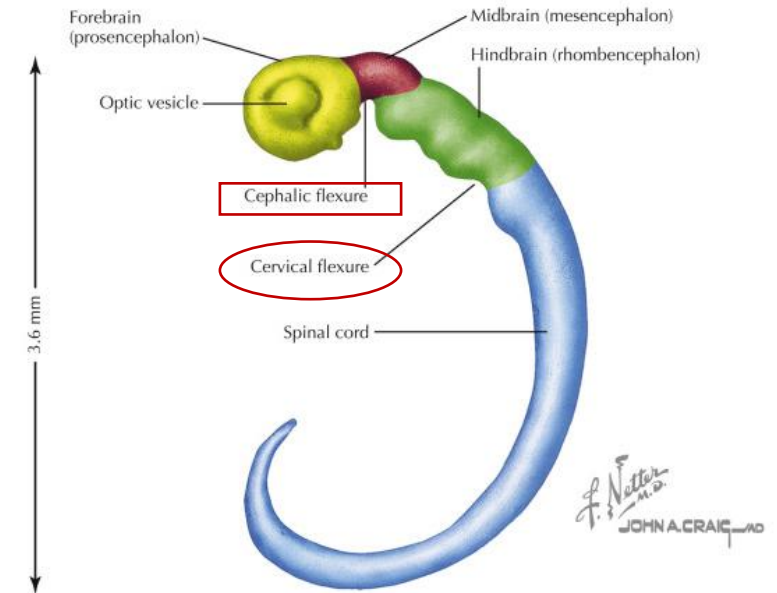
THE EMBRYONIC BRAIN:

1. grows rapidly during the 4th week
2. bends ventrally with the head fold

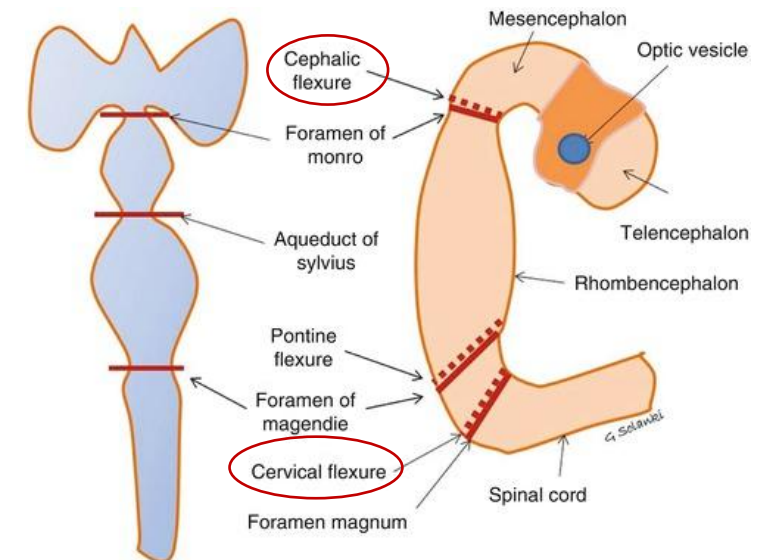
THESE BENDING produces:

1. the MIDBRAIN (CEPHALIC) FLEXURE – in the midbrain region
2. the CERVICAL FLEXURE – at the junction of the hindbrain and the spinal cord

Central nervous system at 28 days



<https://www.sciencedirect.com/topics/neuroscience/cephalic-flexure>

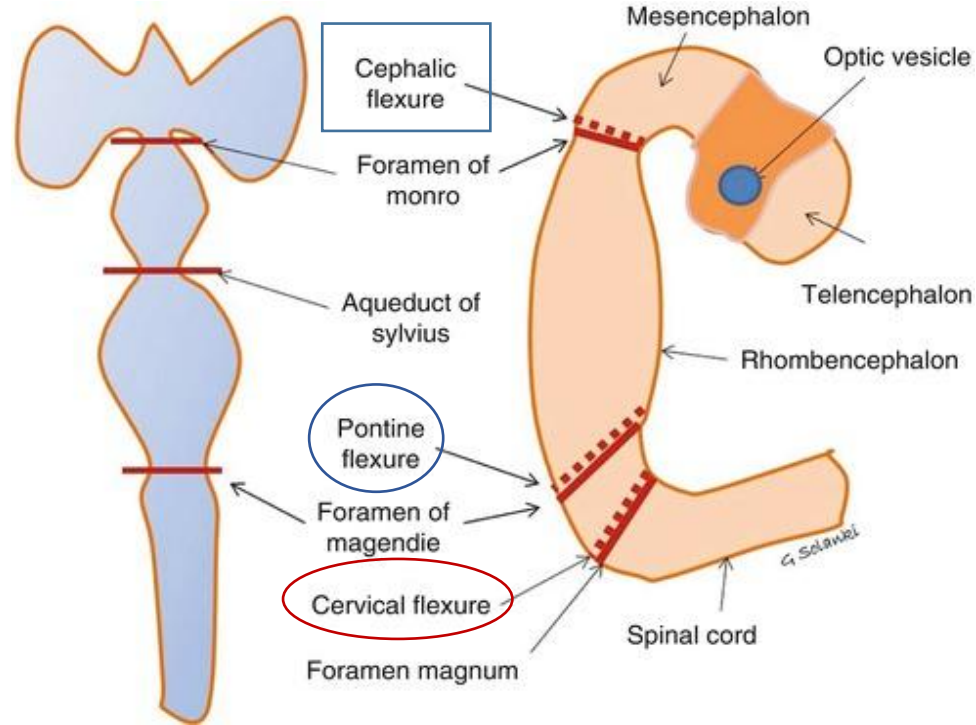


<https://www.bilderbeste.com/foto/pontine-flexure-e4.html>

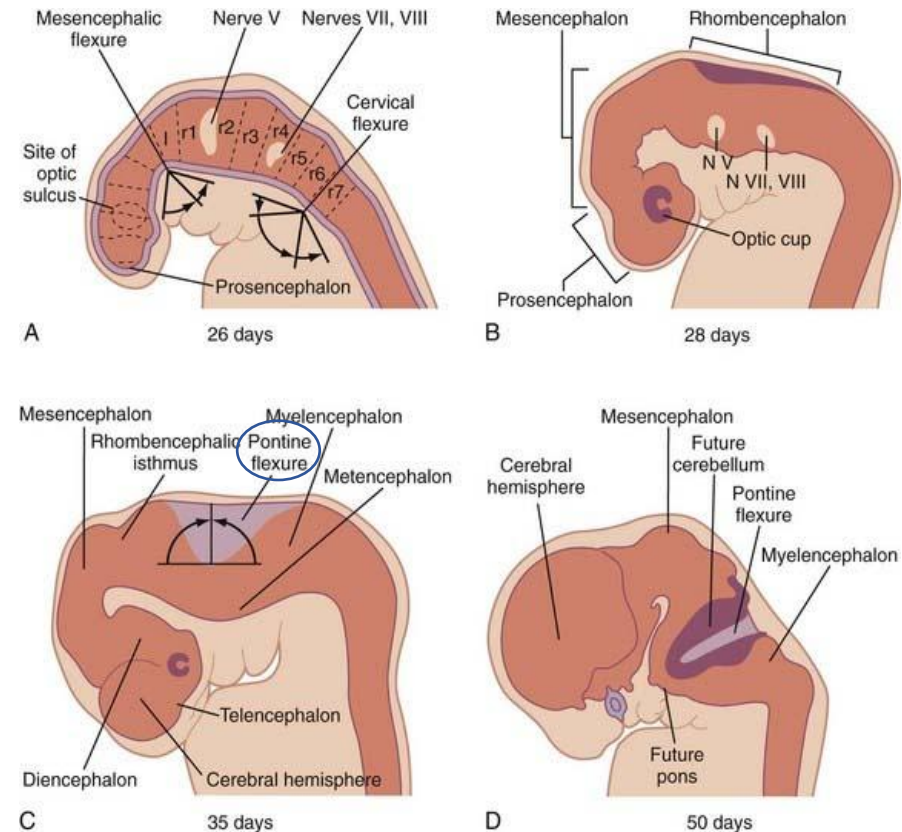
BRAIN FLEXURES

THE EMBRYONIC BRAIN:

- growth between the midbrain and cervical flexure – and produce the **PONTINE FLEXURE**



<https://www.bilderbeste.com/foto/pontine-flexure-e4.html>

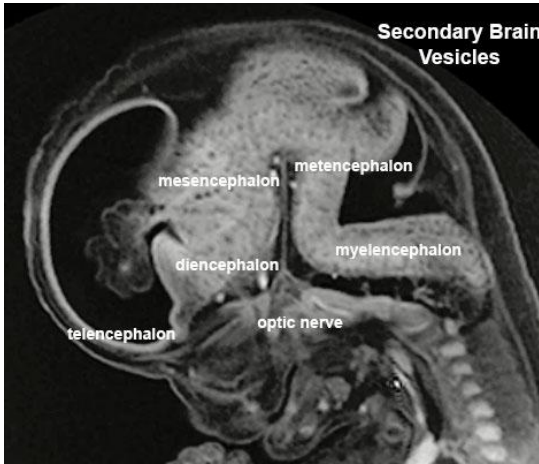


<https://www.bilderbeste.com/foto/pontine-flexure-e4.html>

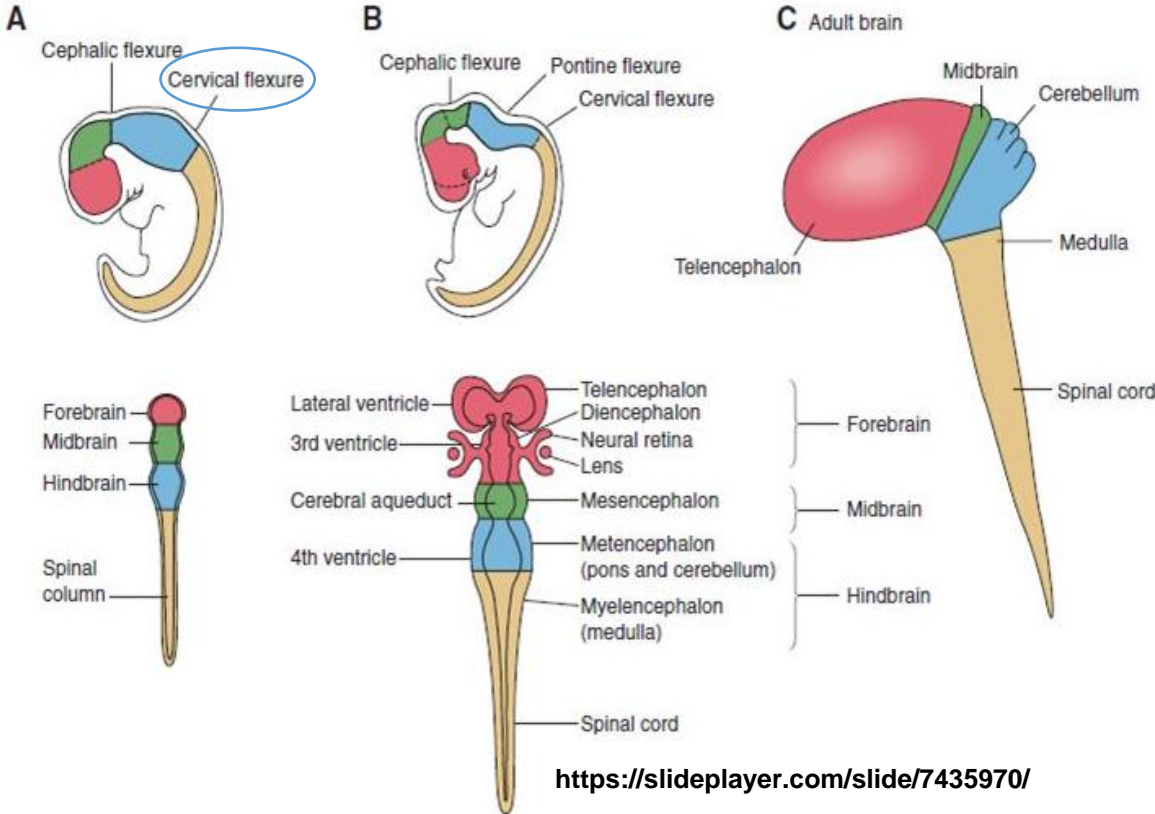
DEVELOPMENT OF BRAIN

HINDBRAIN:

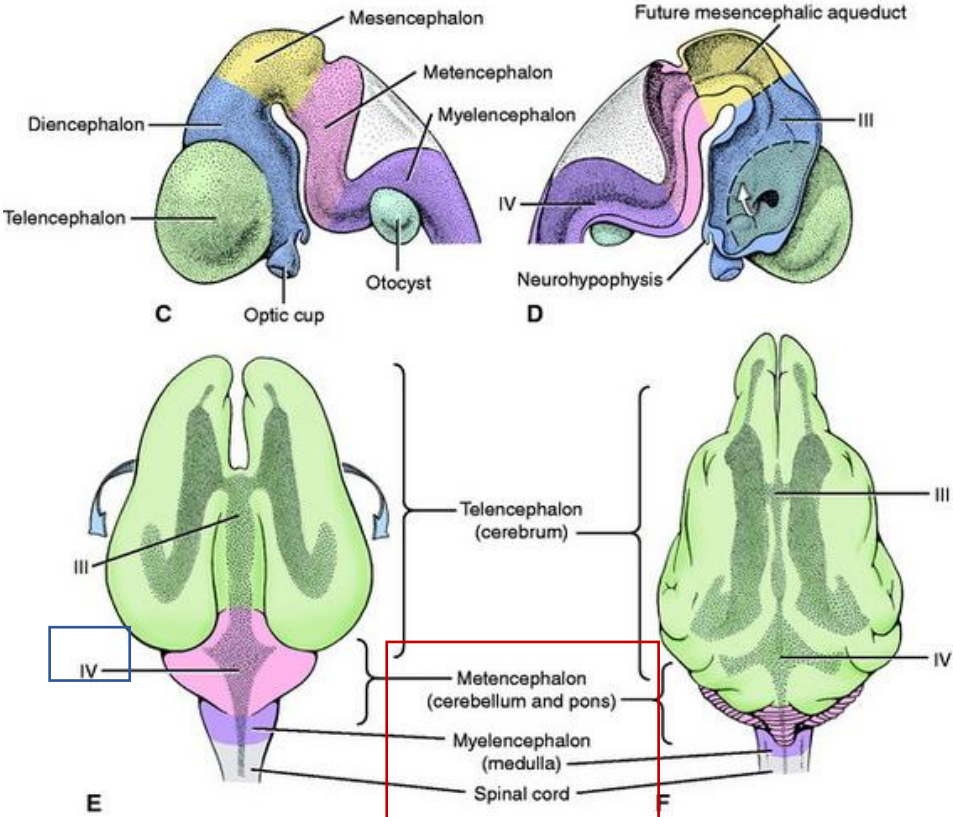
- the cervical flexure demarcates the hindbrain from the spinal cord



https://embryology.med.unsw.edu.au/embryology/index.php/Neural_System_Development



<https://slideplayer.com/slide/7435970/>

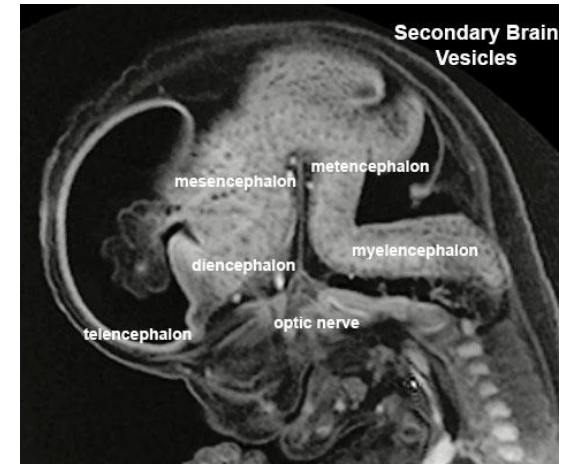


DEVELOPMENT OF BRAIN

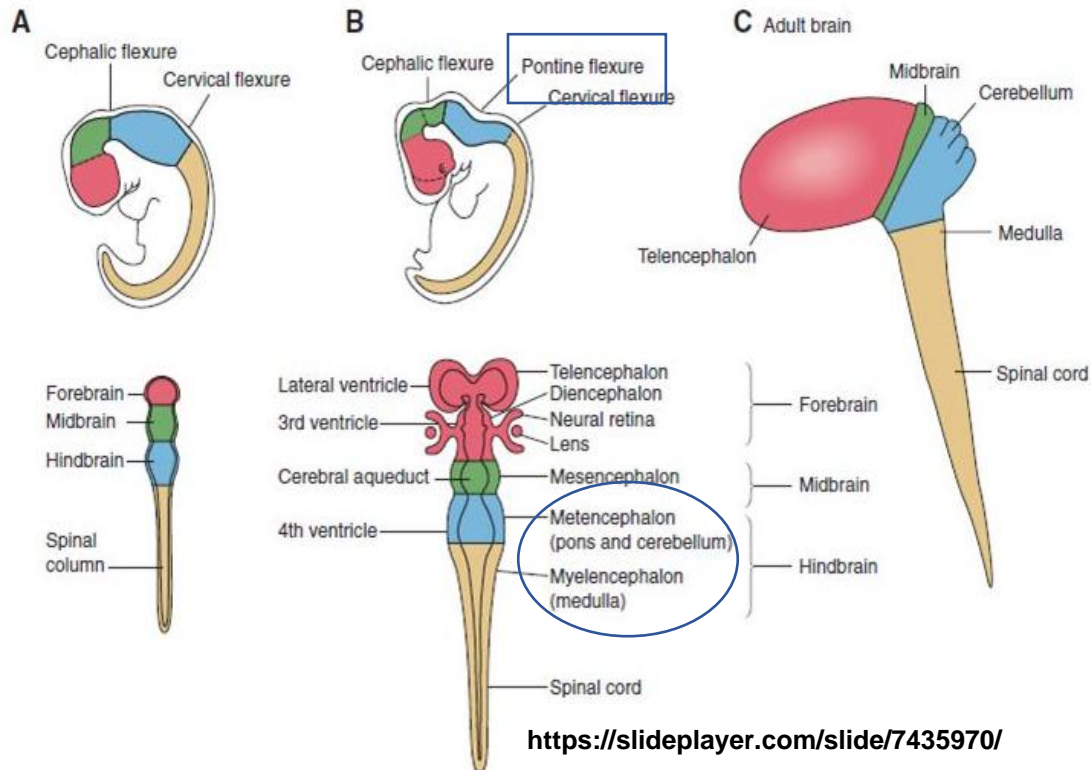
HINDBRAIN:

- the pontine flexure divides the hindbrain into:

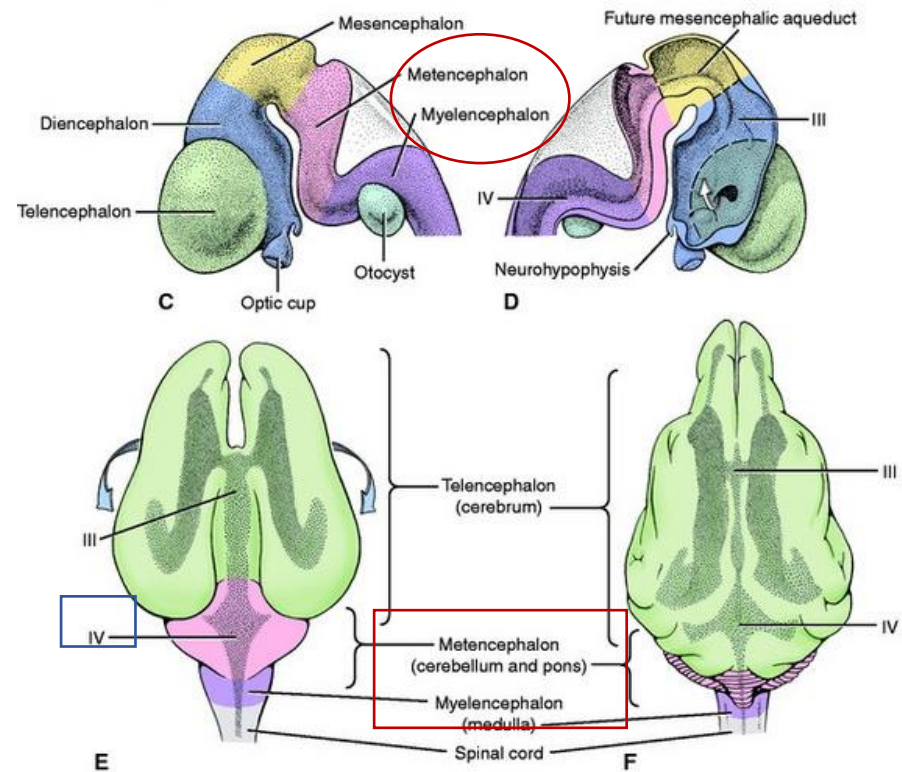
- CAUDAL, MYELENCEPHALON
- ROSTRAL, METENCEPHALON
- THE CAVITY OF the hindbrain becomes the **FOURTH VENTRICLE**



https://embryology.med.unsw.edu.au/embryology/index.php/Neural_System_Development



<https://slideplayer.com/slide/7435970/>

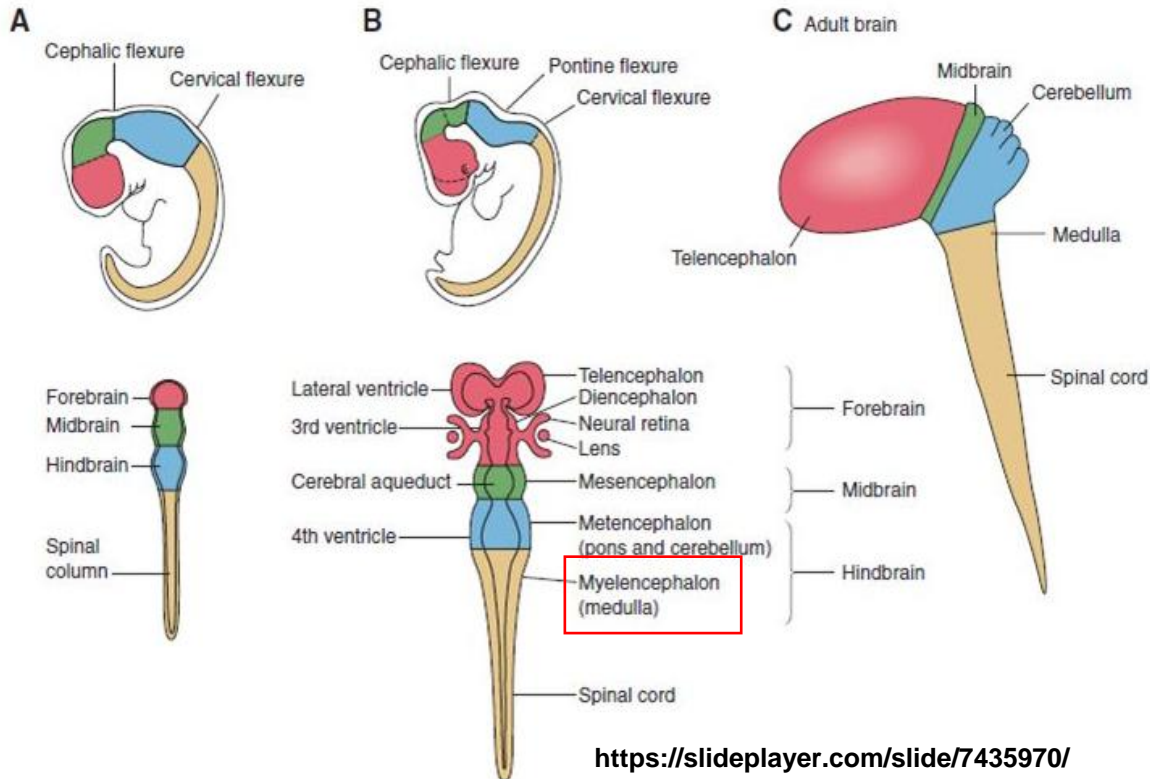


DEVELOPMENT OF BRAIN

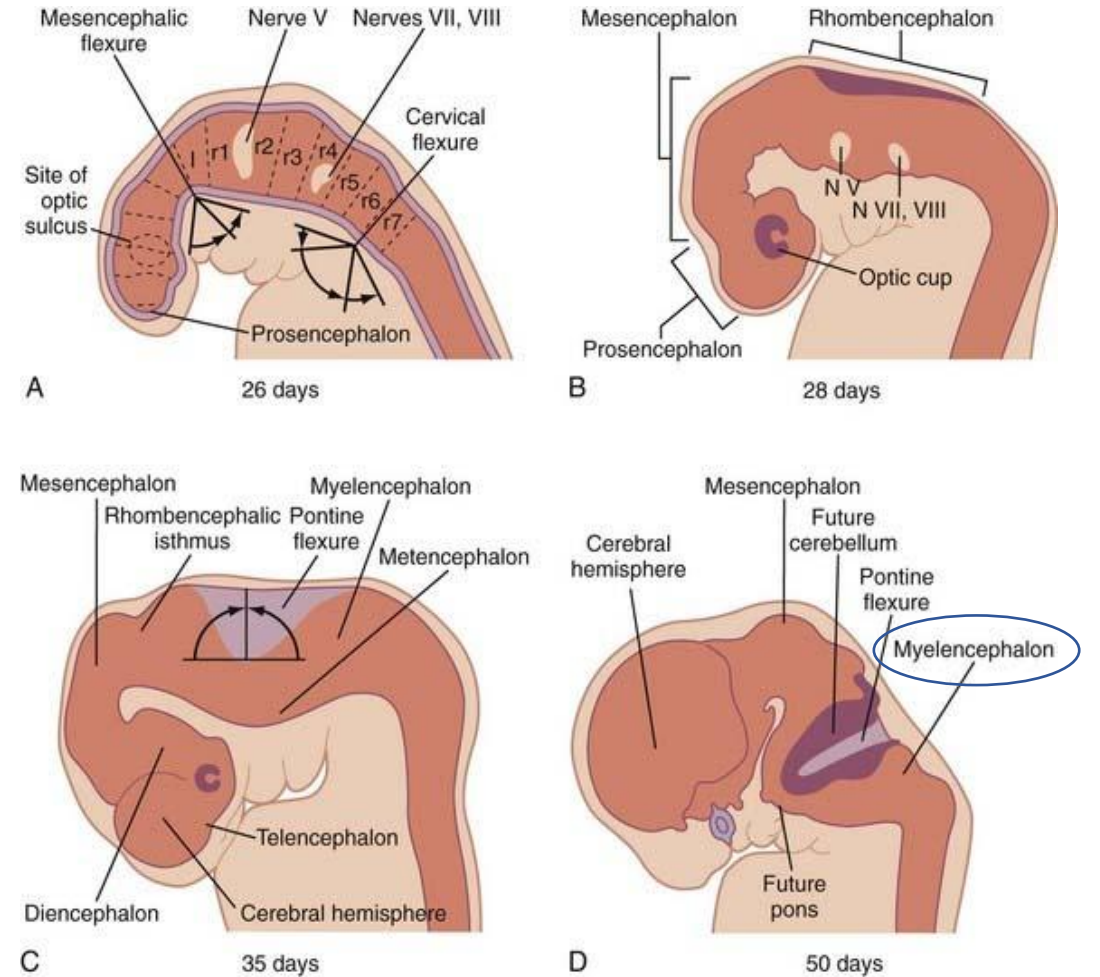
HINDBRAIN:

a. MYELENCEPHALON:

- becomes the MEDULLA OBLONGATA



<https://slideplayer.com/slide/7435970/>



<https://www.bilderbeste.com/foto/pontine-flexure-e4.html>

DEVELOPMENT OF BRAIN

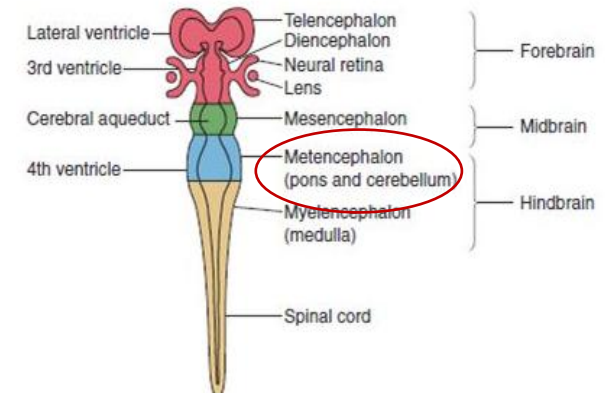
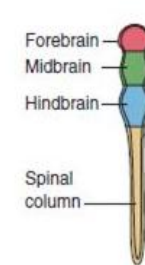
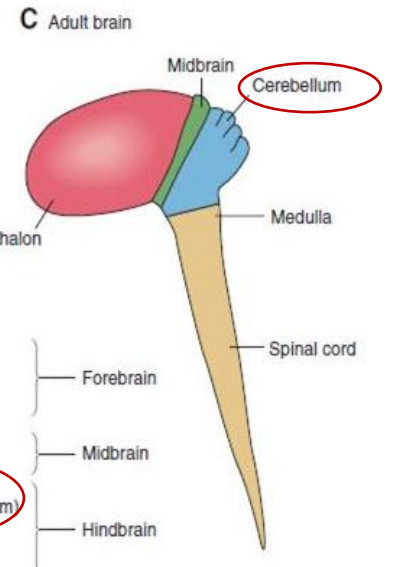
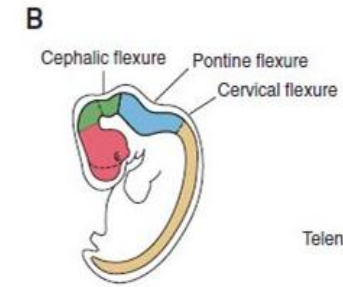
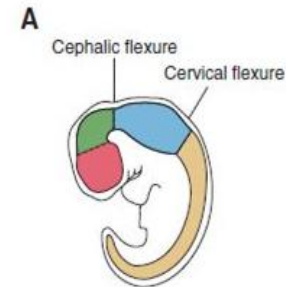
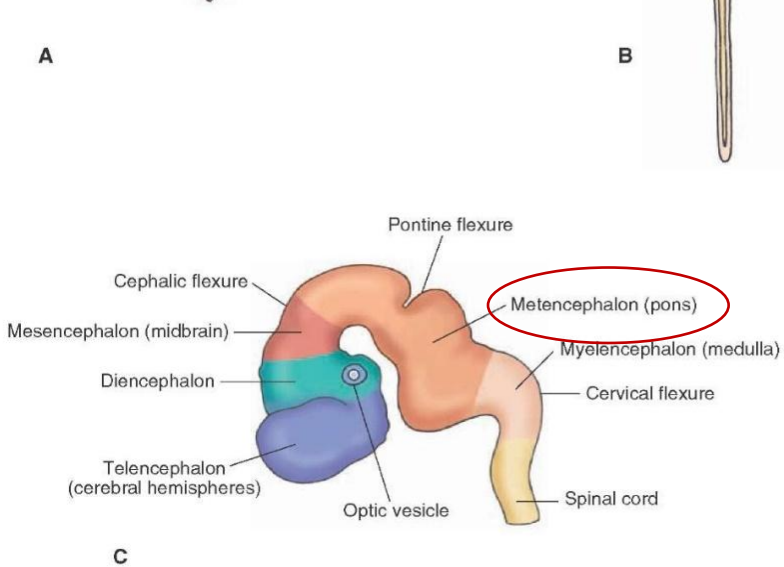
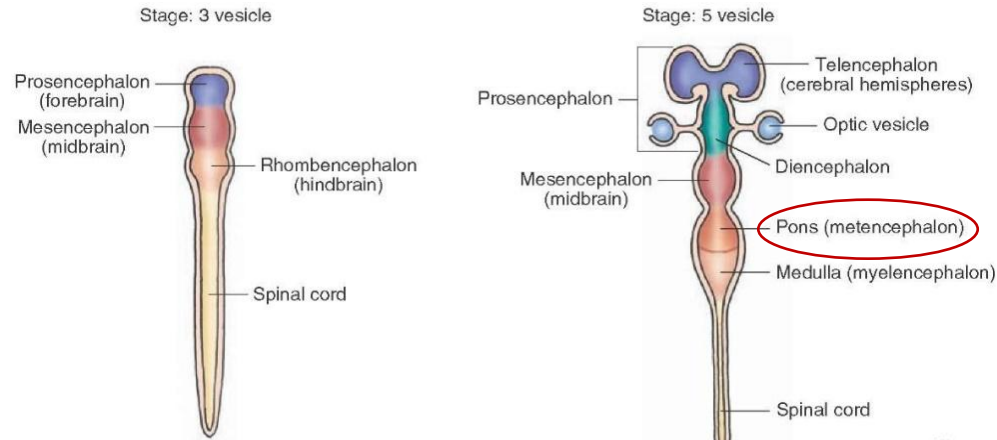
HINDBRAIN:

b. METENCEPHALON:

becomes the:

1. PONS

2. CEREBELLUM



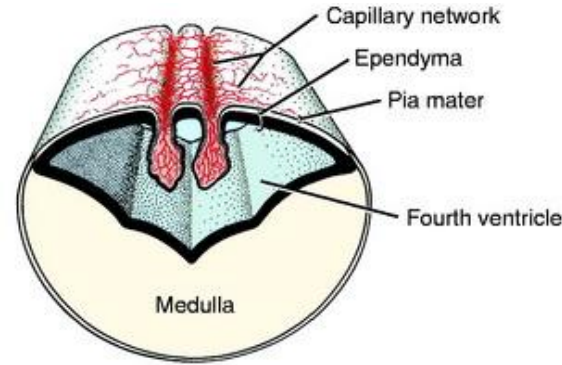
<http://what-when-how.com/neuroscience/development-of-the-nervous-system-gross-anatomy-of-the-brain-part-1/>

DEVELOPMENT OF BRAIN

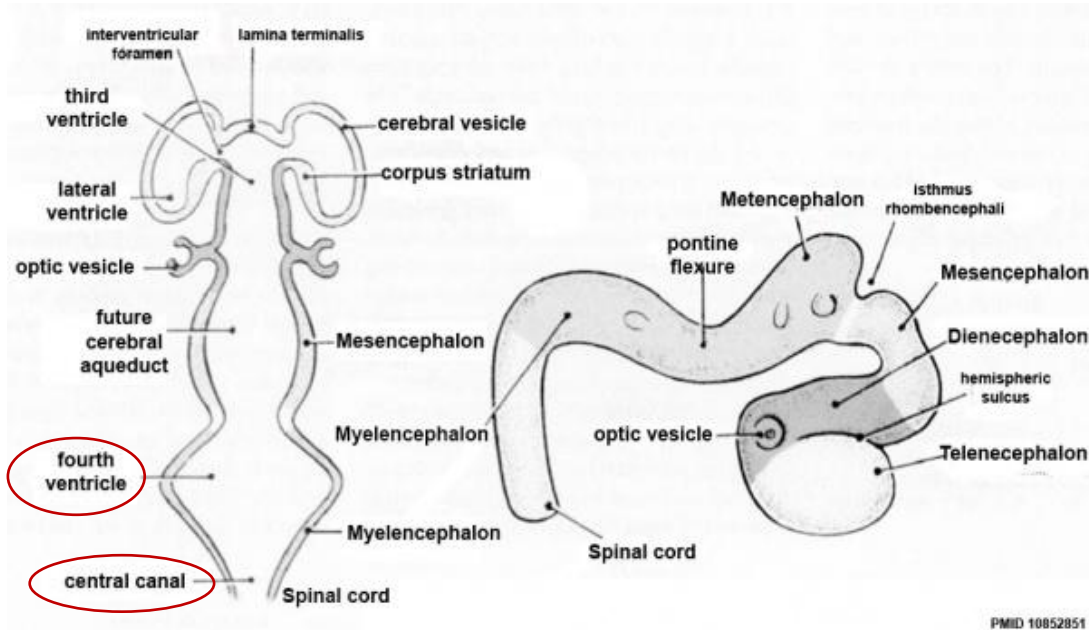
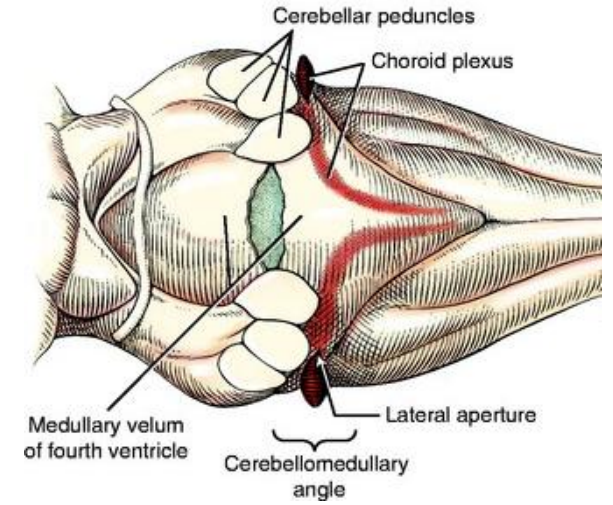
THE CAVITY OF THE HINDBRAIN:

becomes:

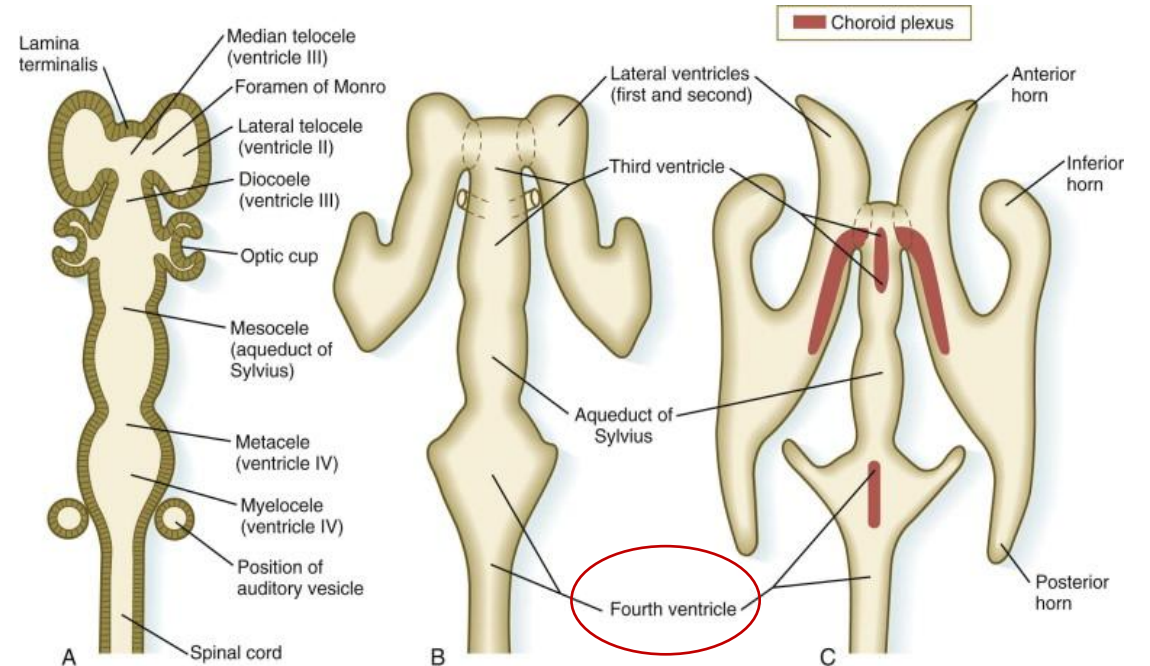
1. the **FOURTH VENTRICLE**
2. the **CENTRAL CANAL** in the caudal part of the medulla oblongata



<https://veteriankey.com/development-of-the-nervous-system-malformation/>



PMID 10852851



DEVELOPMENT OF BRAIN

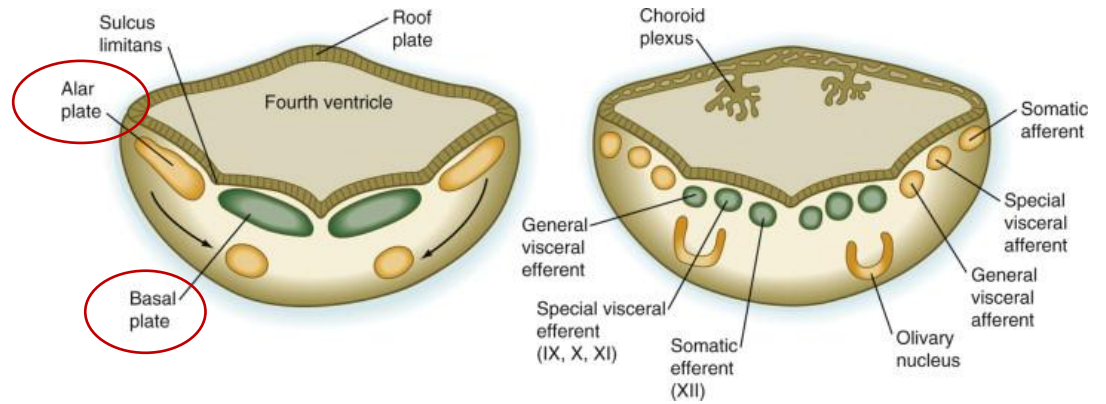
MYELENCEPHALON:

- neuroblasts from the alar plate migrate into the myelencephalon to form:

1. the GRACILE NUCLEI (medially)
 2. the CUNEATE NUCLEI (laterally)
- } **sensory nuclei**

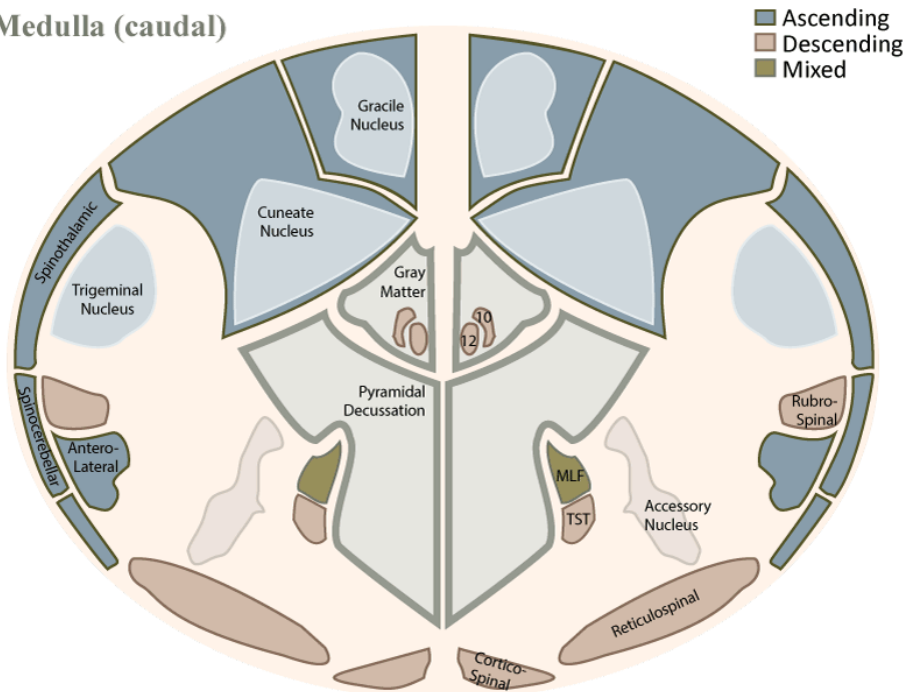
- the ventral area contained the PYRAMIDS = corticospinal fibers

- the **Pyramids are motoric** – innervate the skeletal muscles



<https://www.sciencedirect.com/topics/neuroscience/myelencephalon>

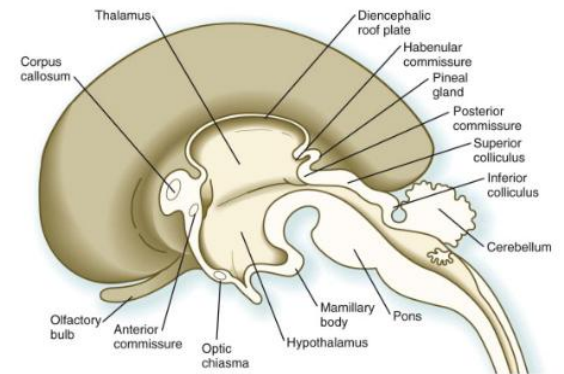
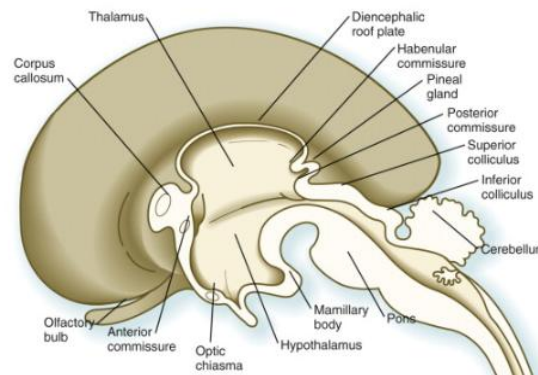
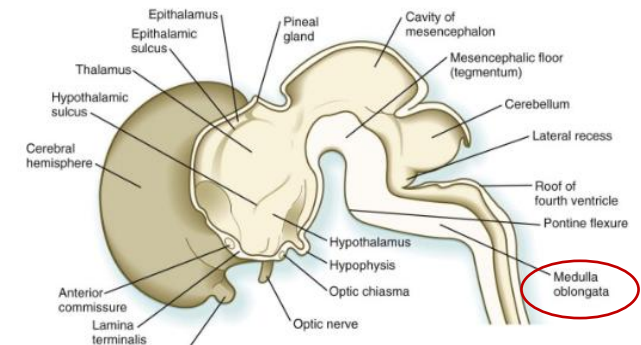
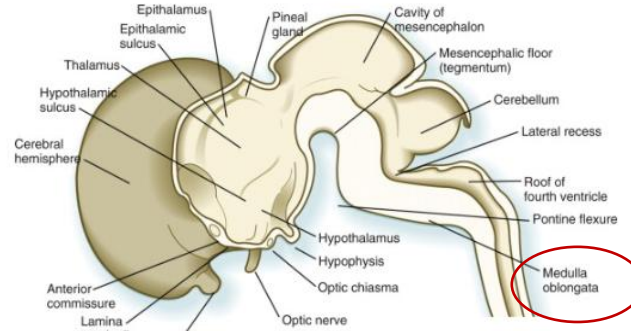
Medulla (caudal)



fpnotebook.com

from Haines (1987) Neuroanatomy, p. 79

<https://fpnotebook.com/Neuro/Anatomy/MdIOblngt.htm>



<https://www.sciencedirect.com/topics/neuroscience/myelencephalon>

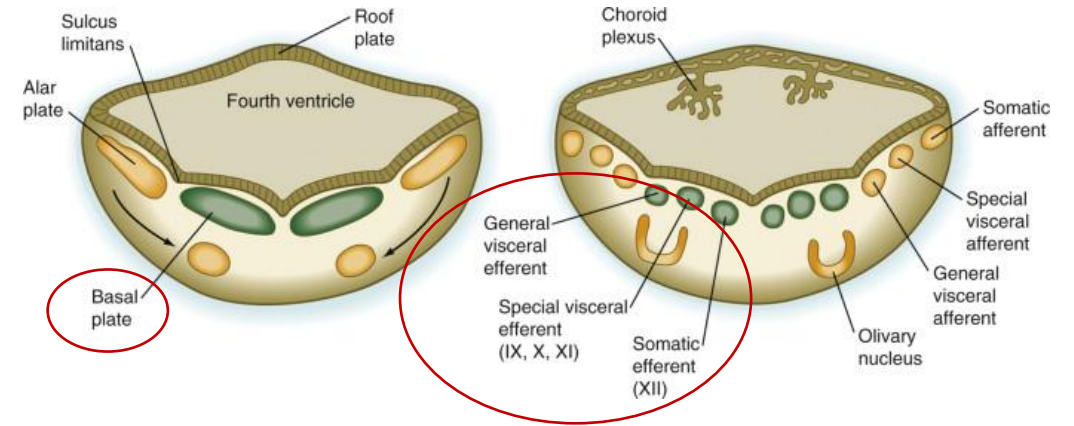
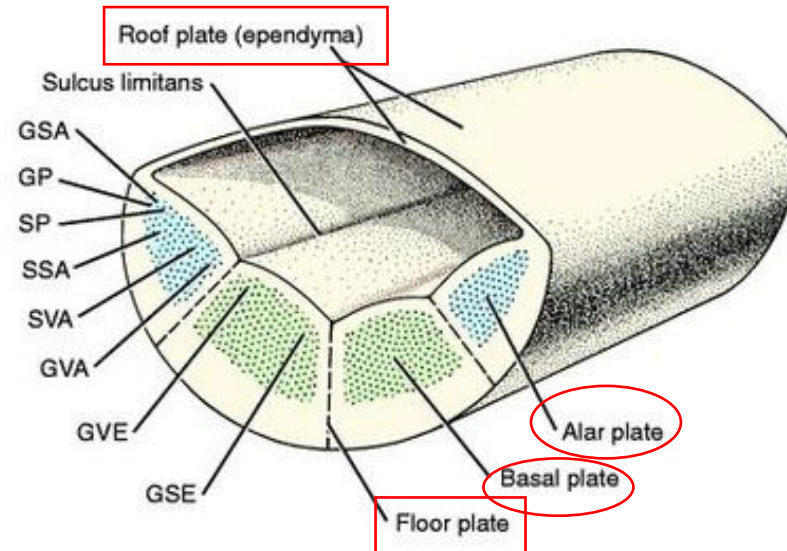
DEVELOPMENT OF BRAIN

MYELENCEPHALON:

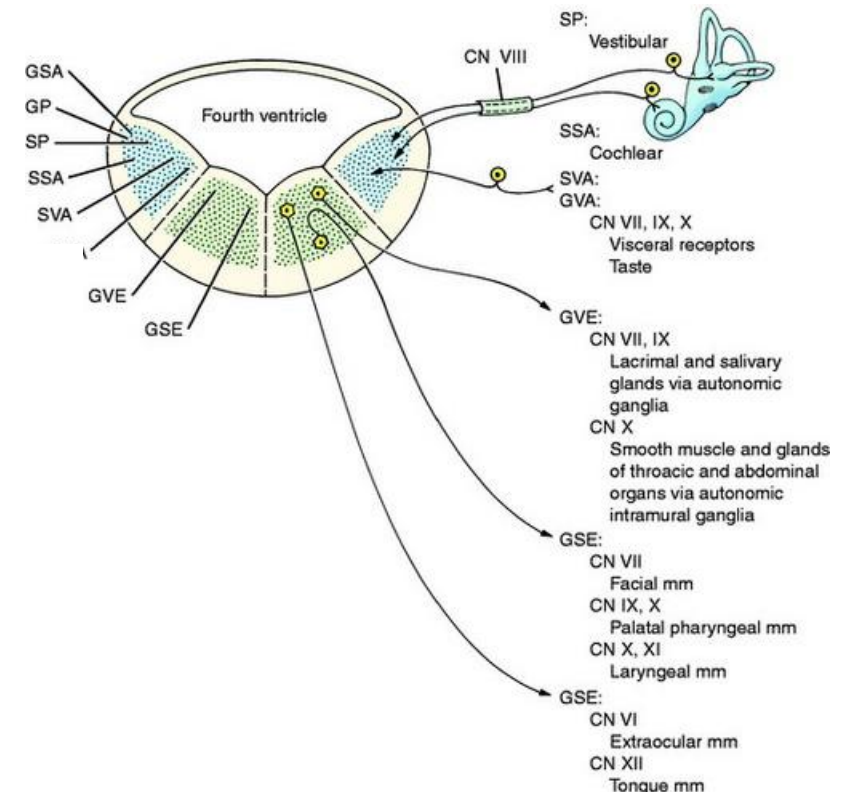
- neuroblasts in the **BASAL PLATE** of the medulla develop into **MOTOR NEURONS**
- the motor nuclei develop medial to the sensory nuclei

FROM MEDIAL TO LATERAL they are:

1. the general somatic efferent nuclei – represented by the neurons of the hypoglossal nerve
2. the special visceral efferent nuclei – represented by neurons innervating muscles derived from the pharyngeal arches
3. the general visceral efferent nuclei – represented by neurons of vagus and glossopharyngeal nerves



<https://www.sciencedirect.com/topics/neuroscience/myelencephalon>



<https://veteriankey.com/development-of-the-nervous-system-malformation/>

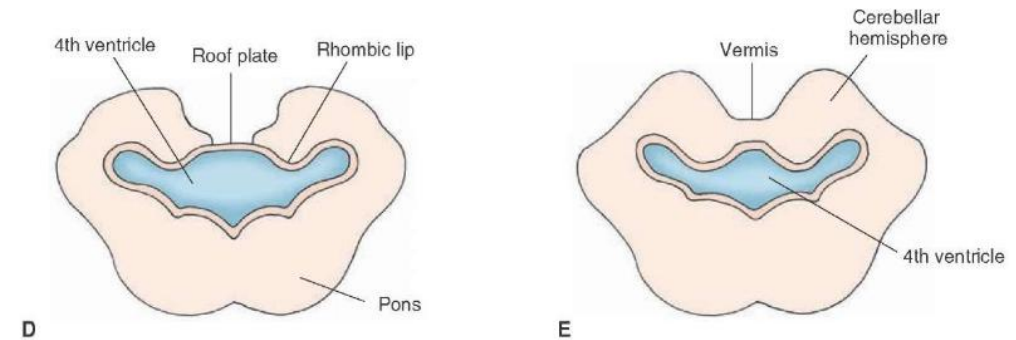
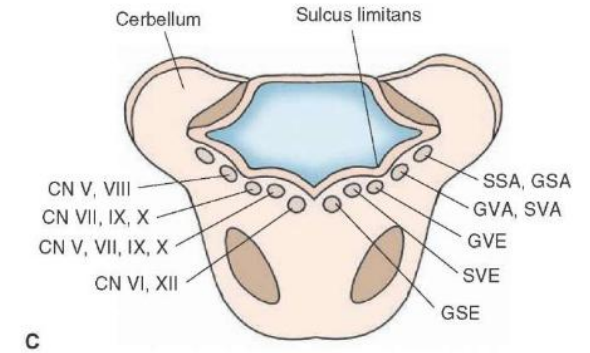
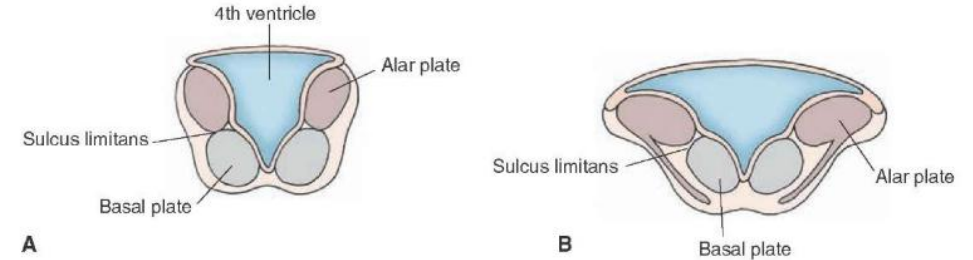
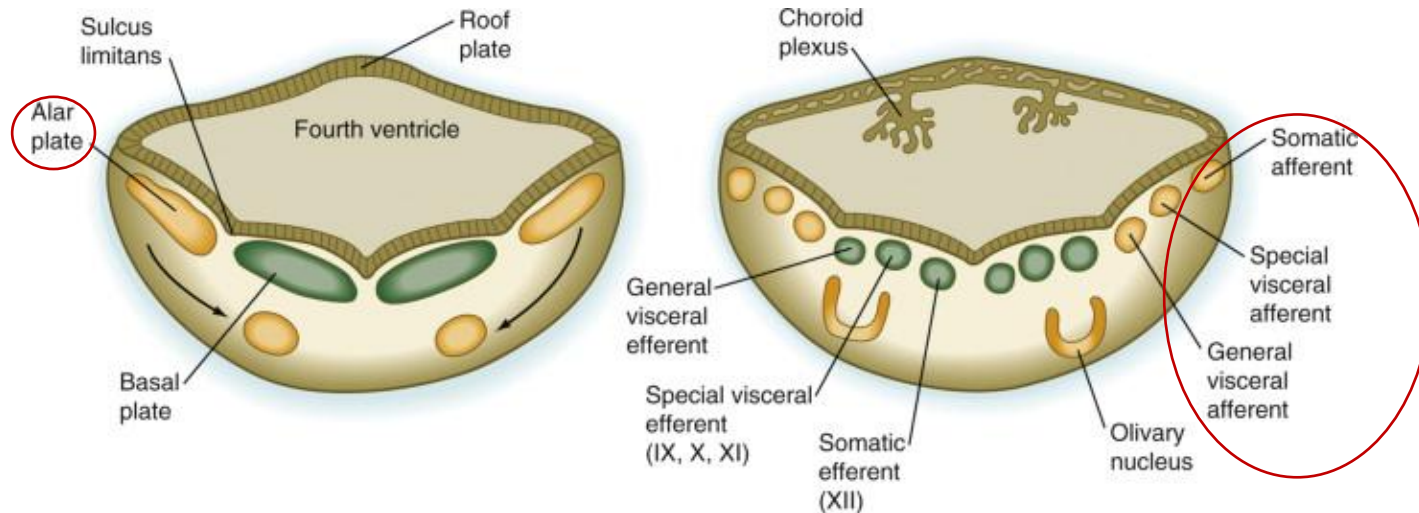
DEVELOPMENT OF BRAIN

MYELENCEPHALON:

- neuroblasts in the ALAR PLATE of the medulla develop into SENSORY NEURONS

FROM MEDIAL TO LATERAL they are:

1. the general visceral afferent nuclei – receiving impulses from the viscera
2. the special visceral afferent nuclei – receiving taste fibers
3. the general somatic afferent nuclei – receiving impulses from the surface of the head
4. the special somatic afferent nuclei – receiving impulses from the ear



<http://what-when-how.com/neuroscience/development-of-the-nervous-system-gross-anatomy-of-the-brain-part-2>

DEVELOPMENT OF BRAIN

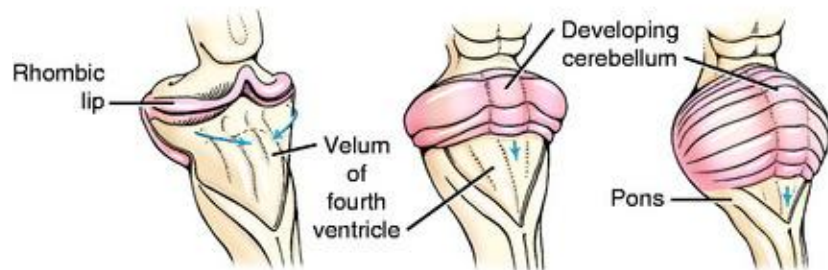
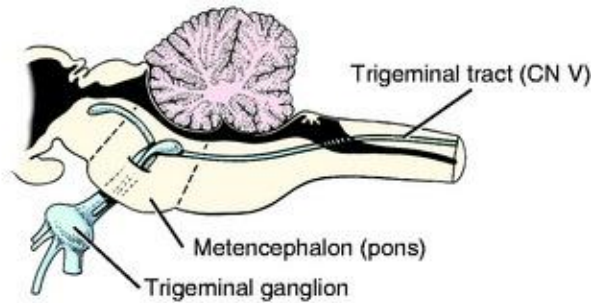
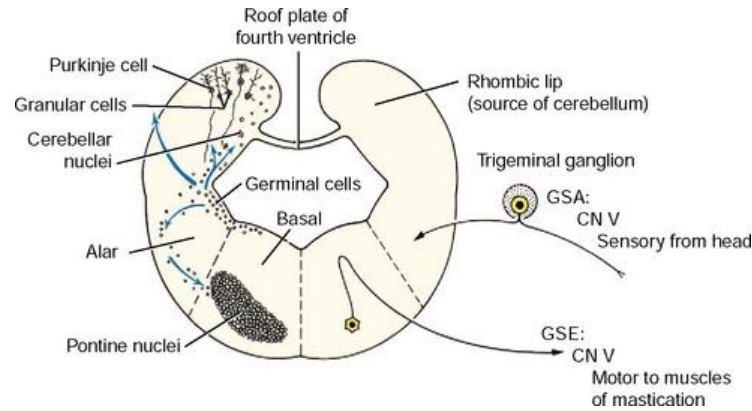
METENCEPHALON

CEREBELLUM:

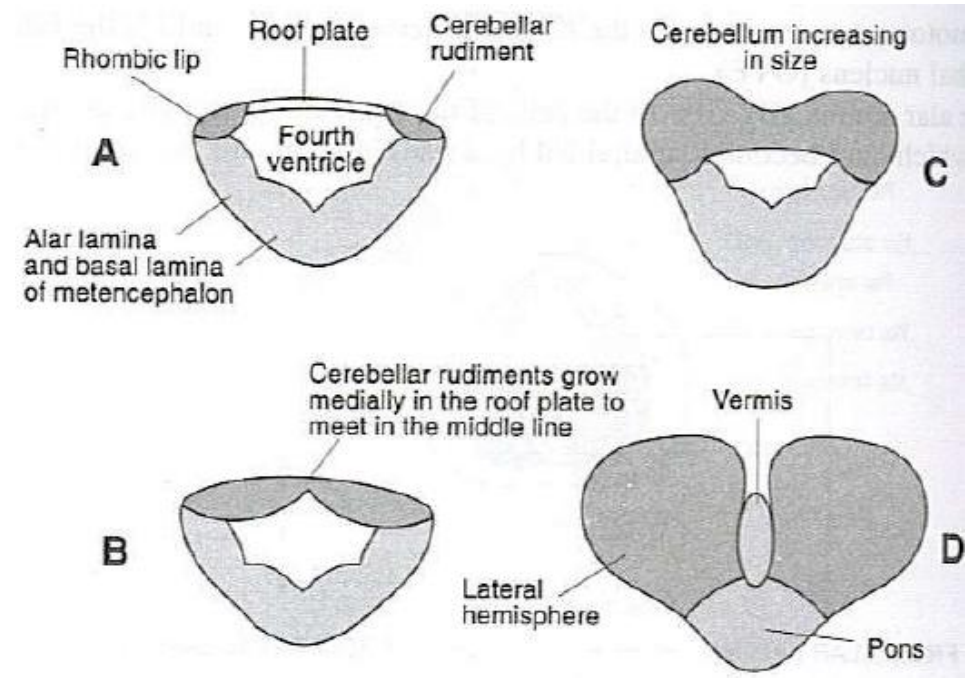
- develops from the dorsal part of the alar plate

the cerebellar swellings:

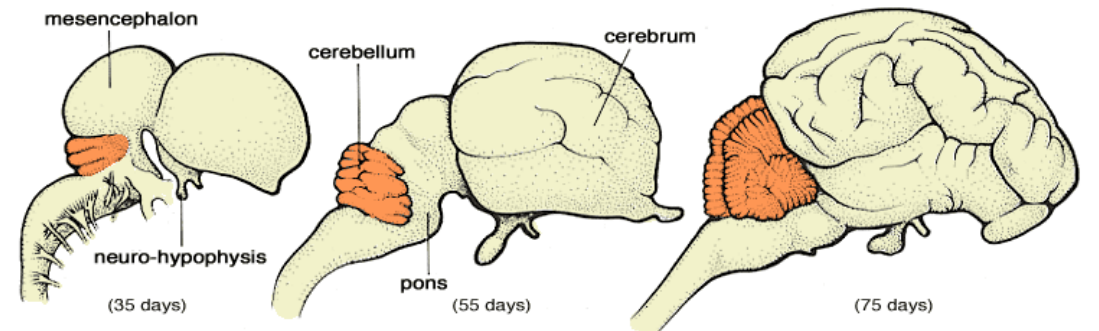
1. enlarge
2. fuse in the median plane
3. overlap the pons and the medulla



<https://veteriankey.com/development-of-the-nervous-system-malformation/>



<https://www.slideshare.net/anjupaed/embryology-of-brain>



Cerebellar Development (Pig)

<http://vanat.cvm.umn.edu/neurLab6/pages/PleaseClick.html>

DEVELOPMENT OF BRAIN

MIDBARIN (MESENCEPHALON):

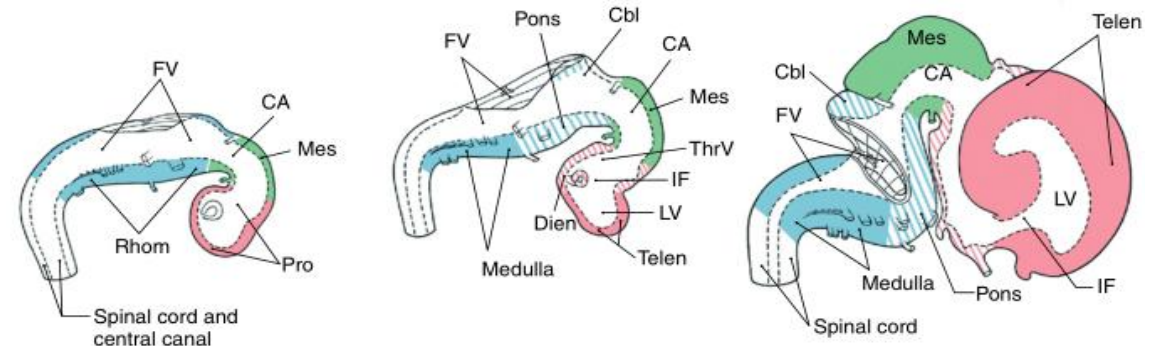
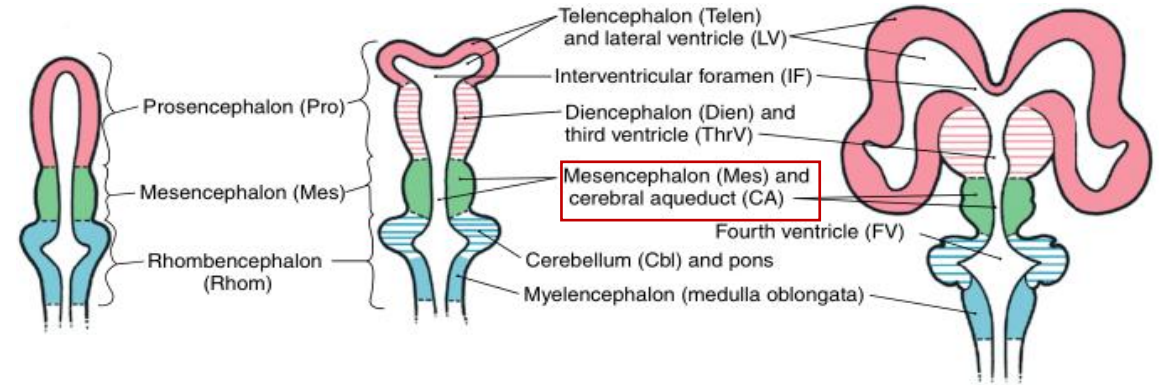
- the neural canal narrows - becomes the cerebral aqueduct

a. cerebral aqueduct – connects the 3rd and 4th ventricle

b. tectum mesencephali (roof):

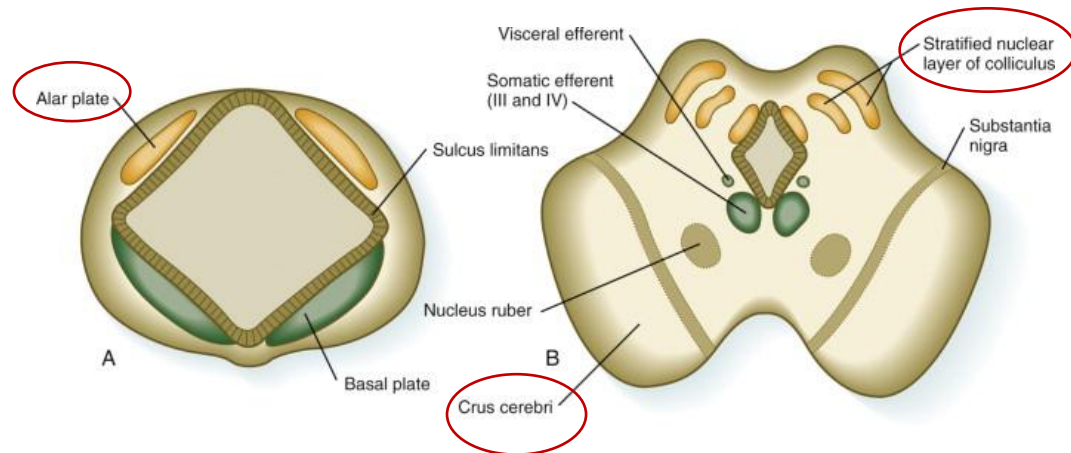
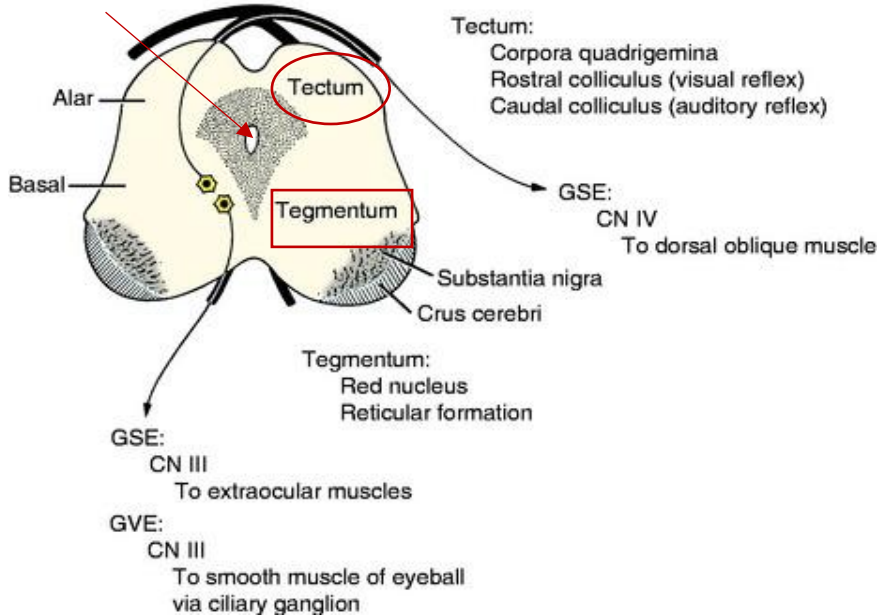
– neuroblasts from alar plate become the rostral and caudal COLLICULI

c. tegmentum mesencephali



<http://luckystarshotel.ru/str/nervous-system/ventricular-system/>

aqueductus



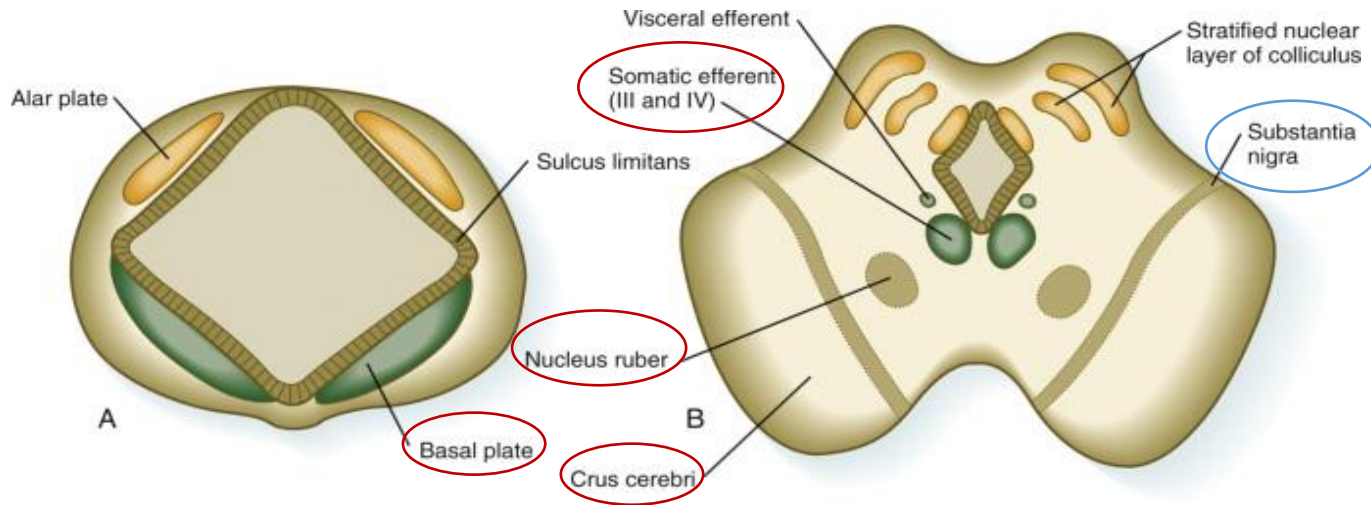
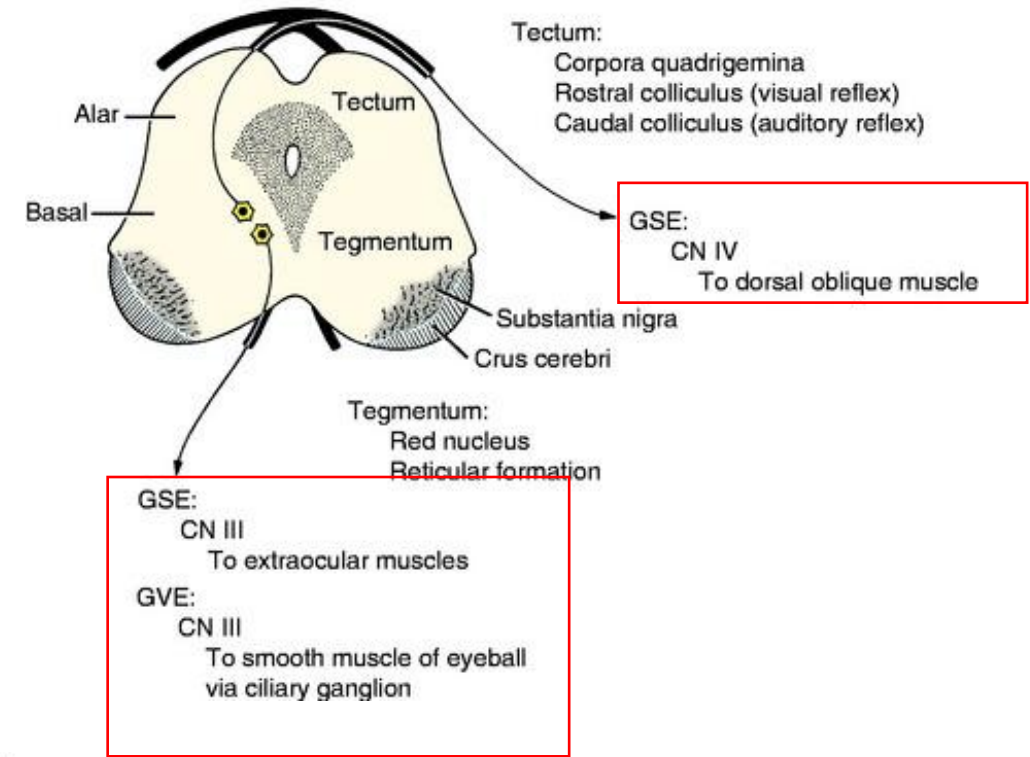
<https://www.sciencedirect.com/topics/agricultural-and-biological-sciences/midbrain>

DEVELOPMENT OF BRAIN

MIDBRAIN (MESENCEPHALON):

– neuroblasts from basal plate give rise to:

1. red nuclei
 2. nuclei of 3rd, 4th cranial nerve
 3. substantia nigra
- d. fibers from cerebrum form the cerebral peduncle (crus cerebri)



DEVELOPMENT OF BRAIN

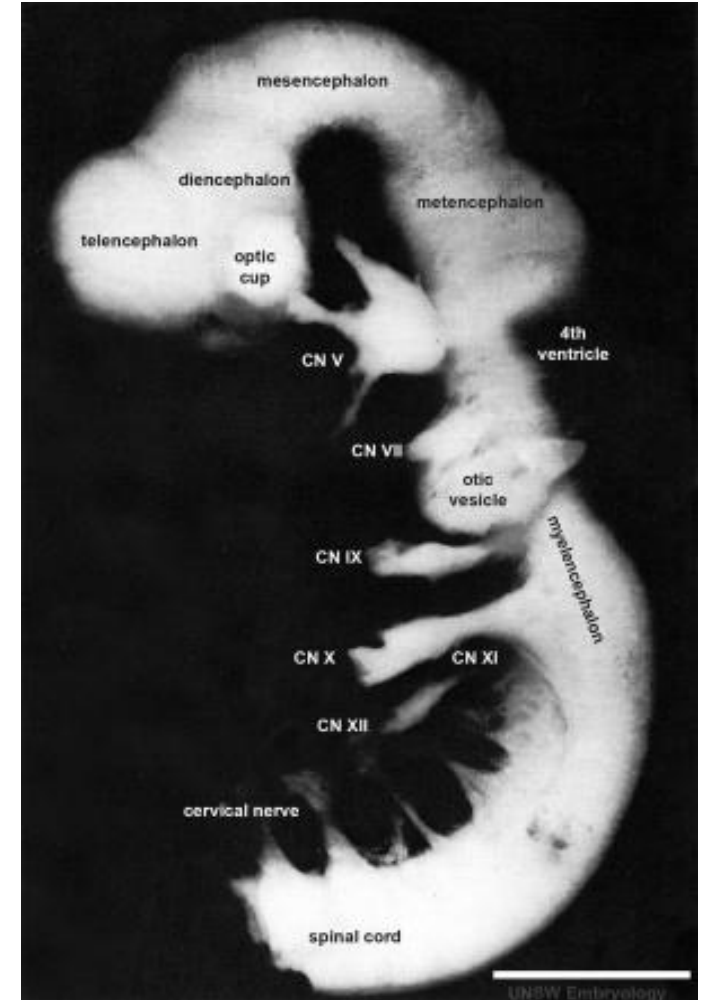
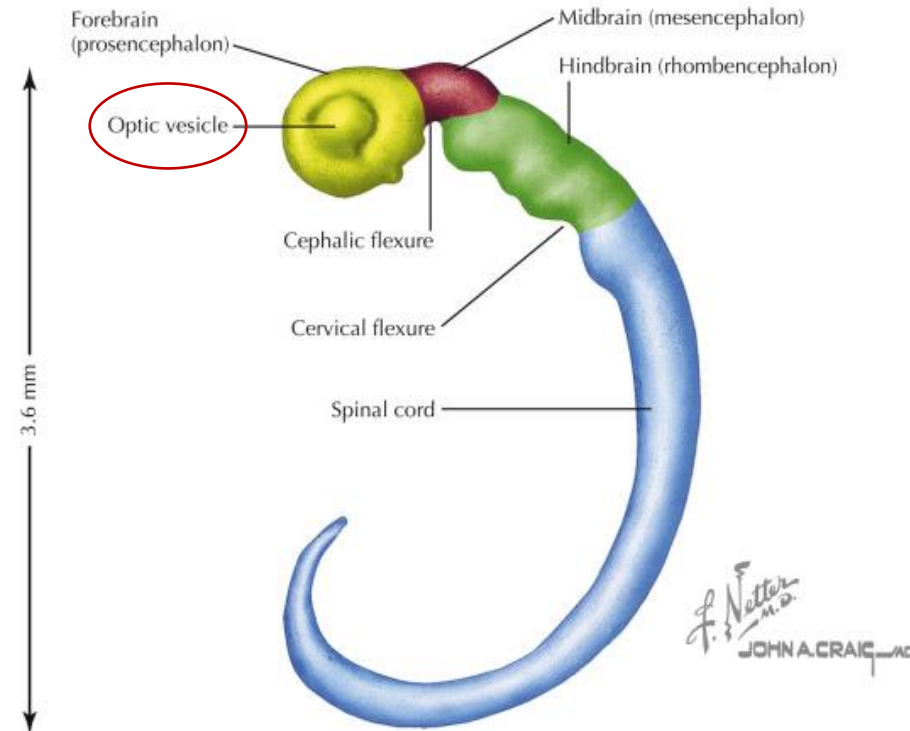
FOREBRAIN:

- at the rostral neuropore occurs – two lateral optic vesicles

OPTIC VESICLES:

- primordia of the retina and optic nerves

Central nervous system at 28 days



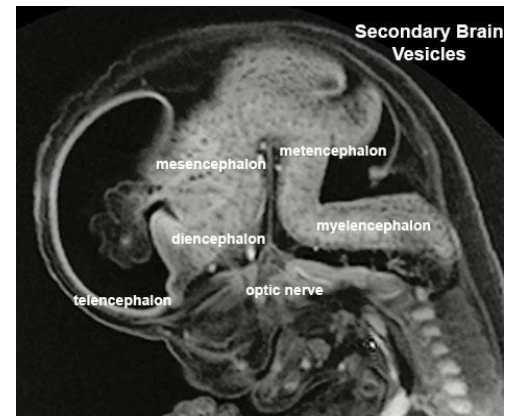
https://embryology.med.unsw.edu.au/embryology/index.php/Neural_System_Development

DEVELOPMENT OF BRAIN

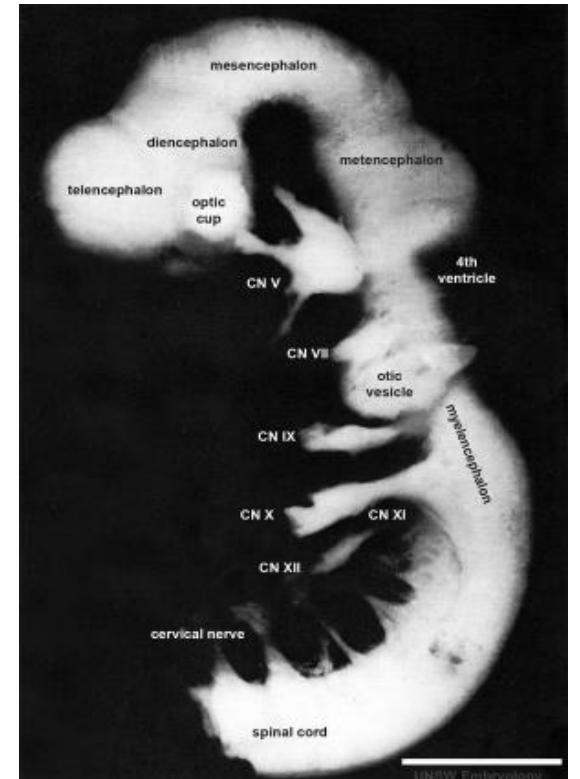
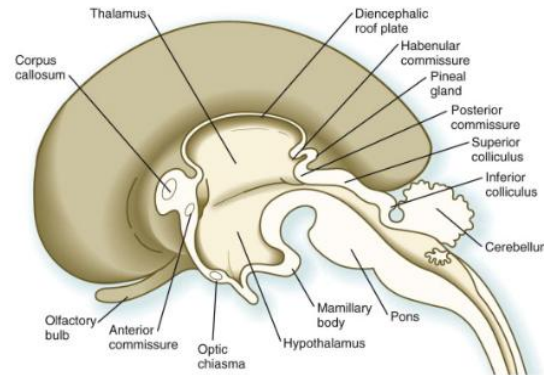
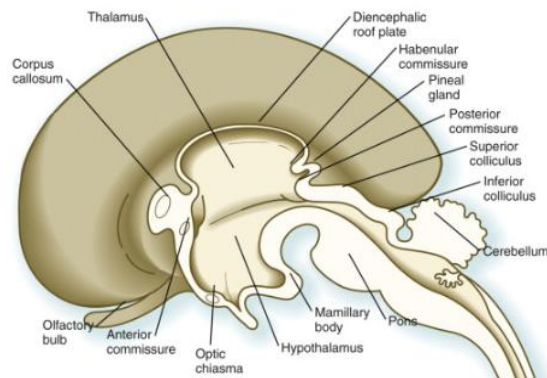
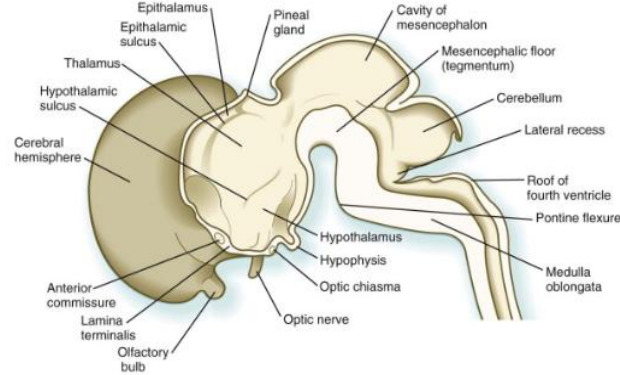
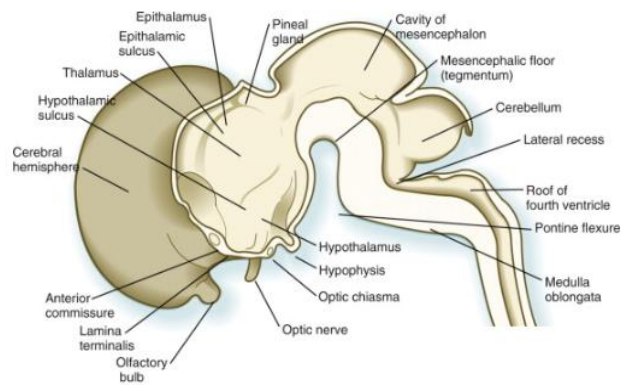
FOREBRAIN:

at the rostral neuropore occur:

- rostral (anterior) telencephalic vesicles
- dorsal (posterior) diencephalic vesicles



https://embryology.med.unsw.edu.au/embryology/index.php/Neural_System_Development



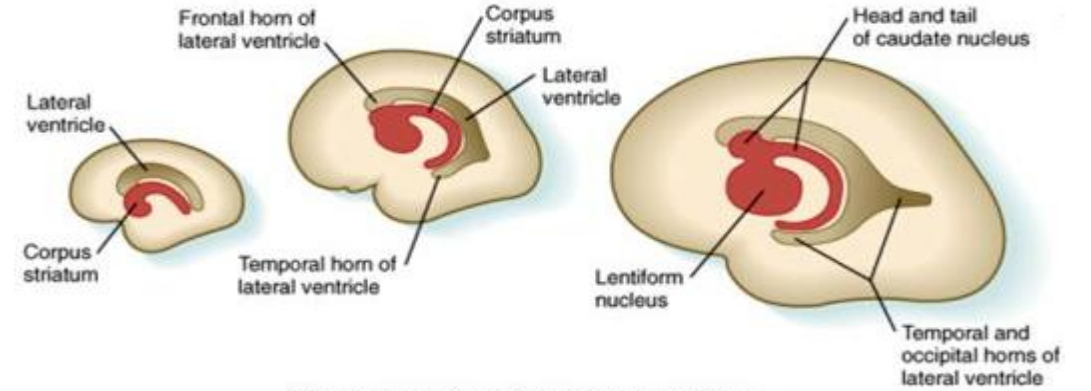
https://embryology.med.unsw.edu.au/embryology/index.php/Neural_System_Development

DEVELOPMENT OF BRAIN

FOREBRAIN:

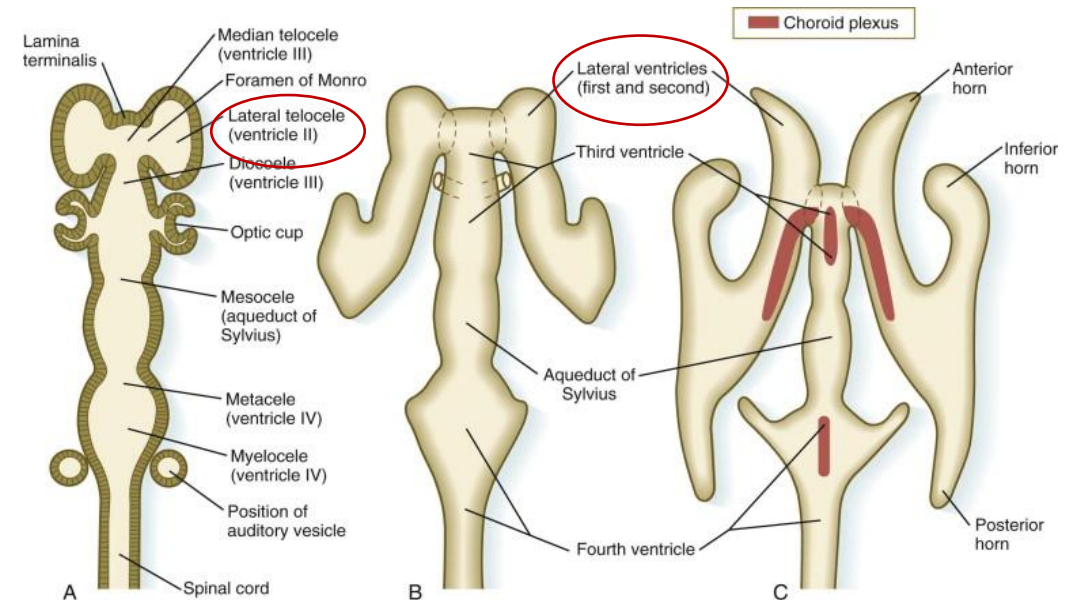
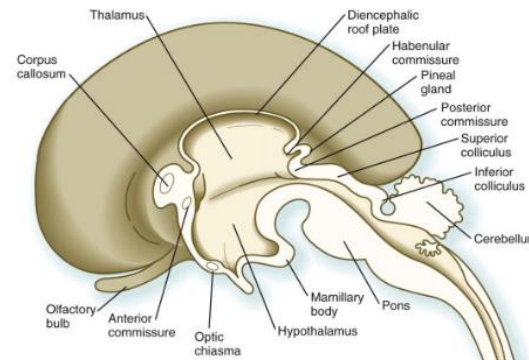
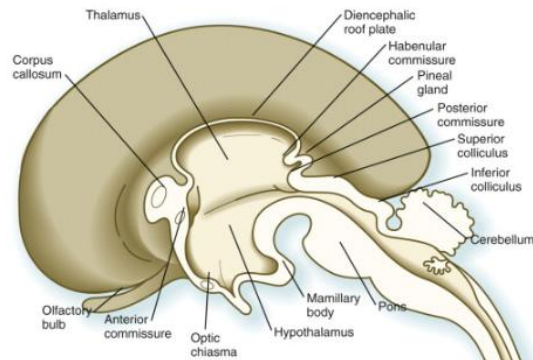
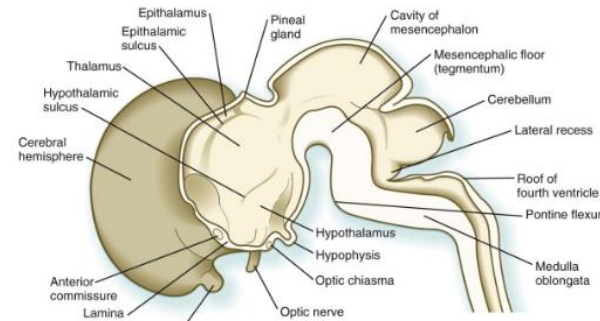
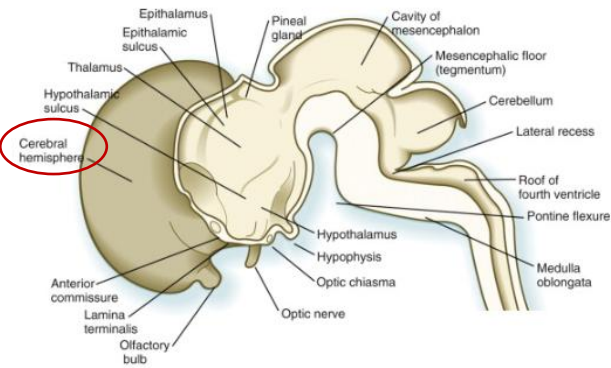
THELENCEPHALIC VESICLES:

- primordia of the cerebral hemispheres
- their cavity become the lateral ventricle
- known as telencephalon



Cartoon: Human Embryology and Developmental Biology, 4th Edition.
Copyright © 2009 by Mosby, an imprint of Elsevier, Inc. All rights reserved.

<https://slideplayer.com/slide/4492771/>



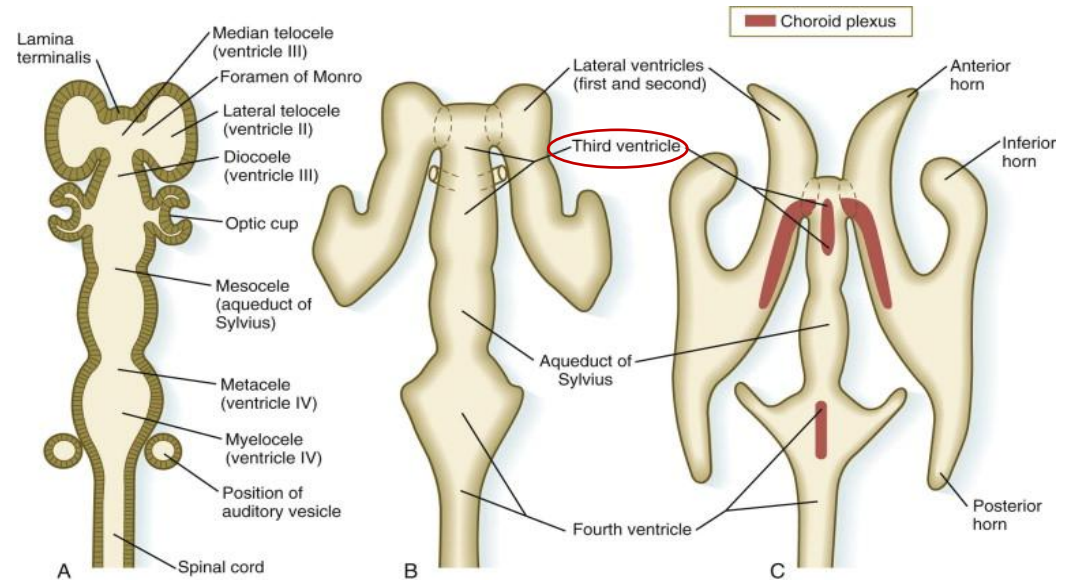
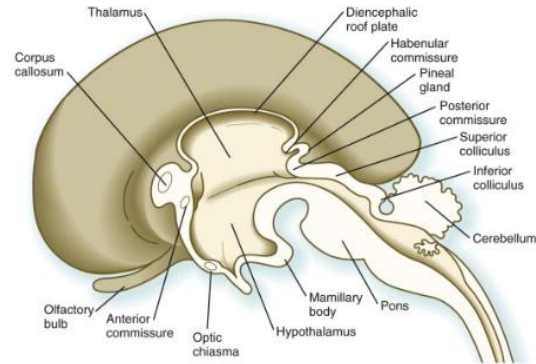
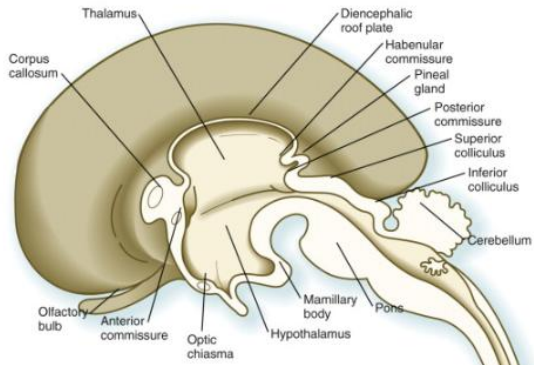
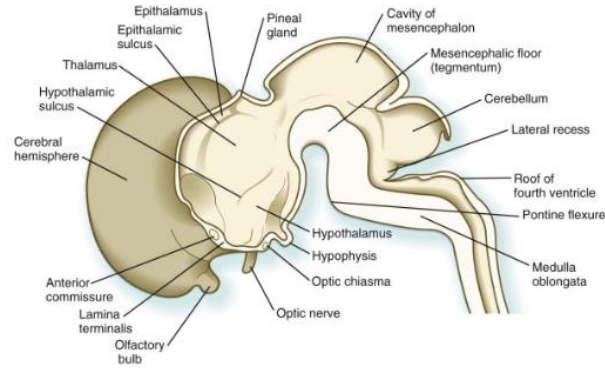
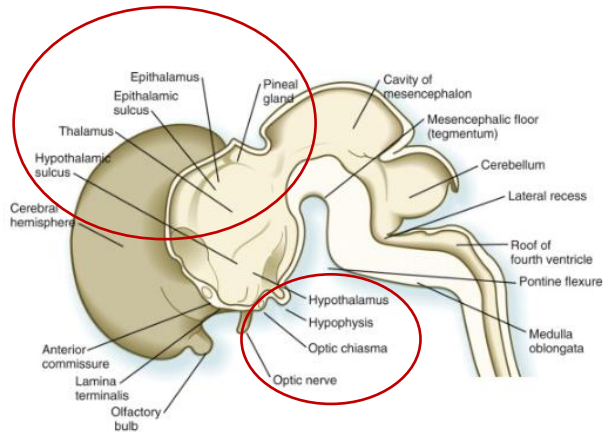
<https://www.sciencedirect.com/topics/neuroscience/myelencephalon>

DEVELOPMENT OF BRAIN

FOREBRAIN:

DIENCEPHALIC VESICLES:

- known as diencephalon
- their cavities become – 3rd ventricle

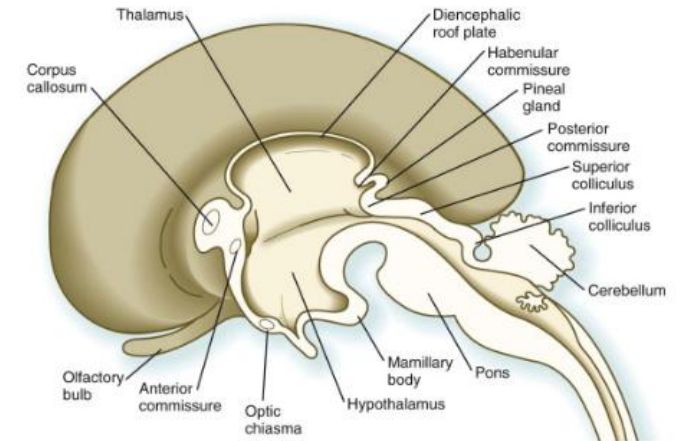
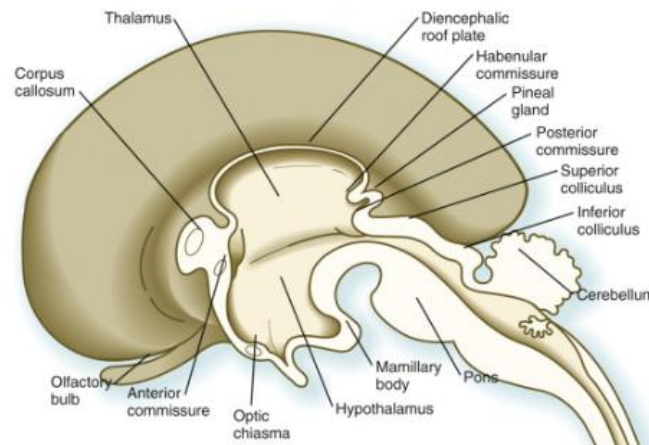
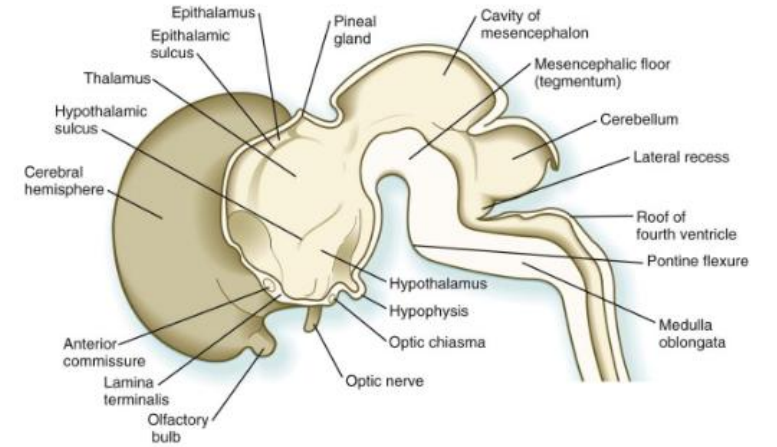
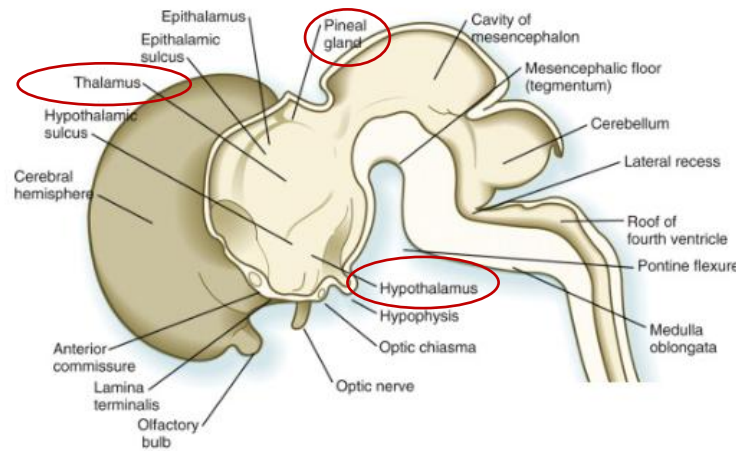


DEVELOPMENT OF BRAIN

DIENCEPHALON:

three swellings develop in the lateral walls of the 3rd ventricle, which later become the:

1. THALAMUS
2. HYPOTHALAMUS
3. EPITHALAMUS (pineal gland)

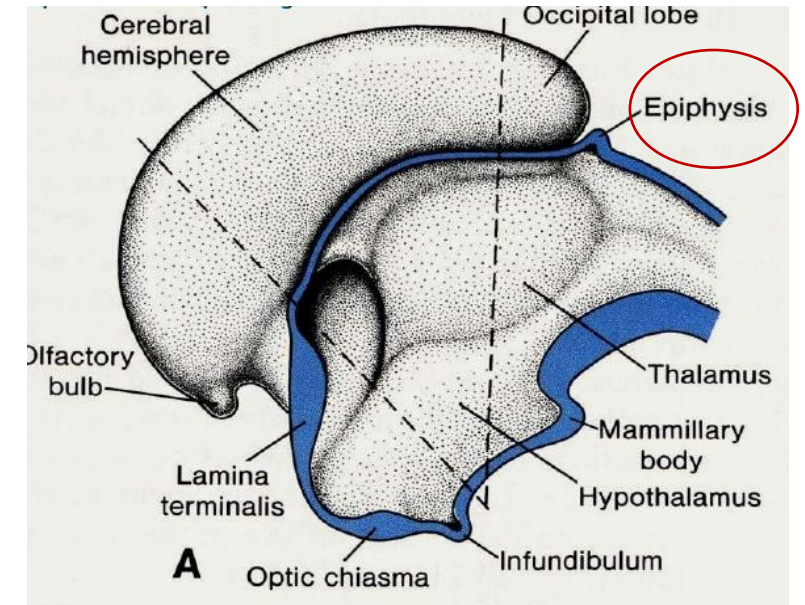


DEVELOPMENT OF BRAIN

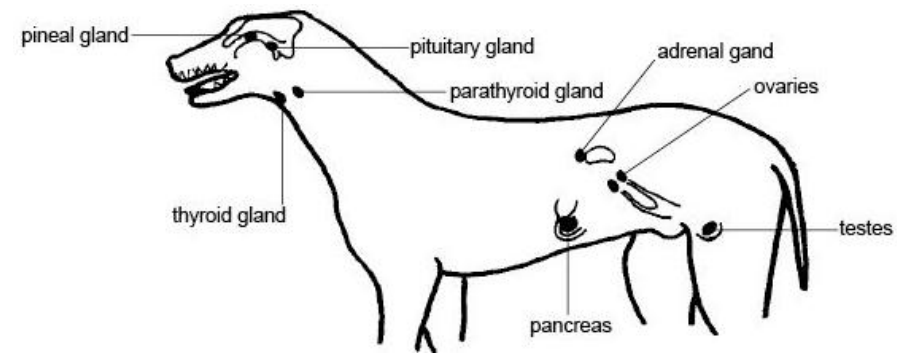
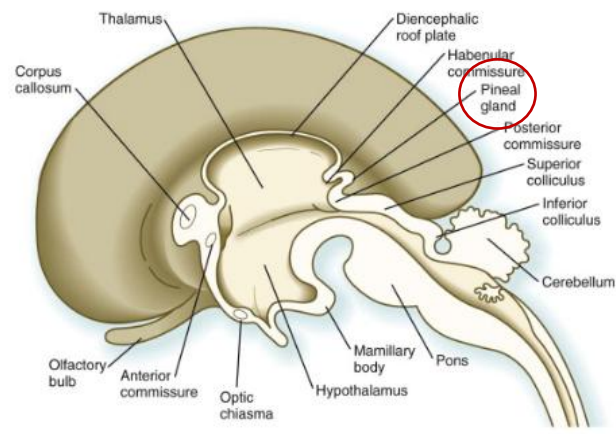
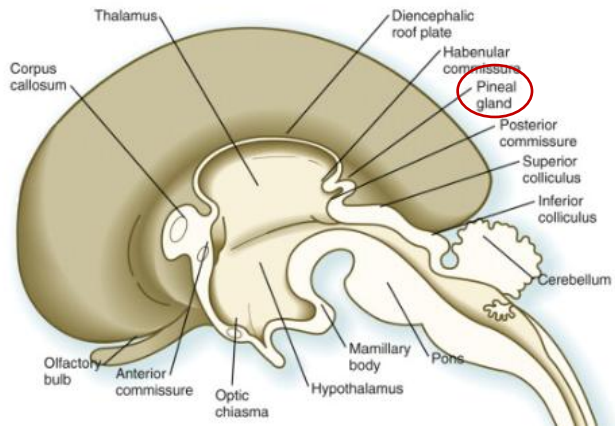
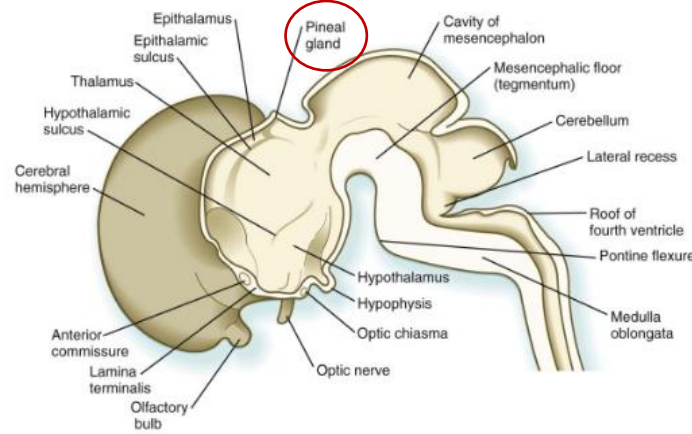
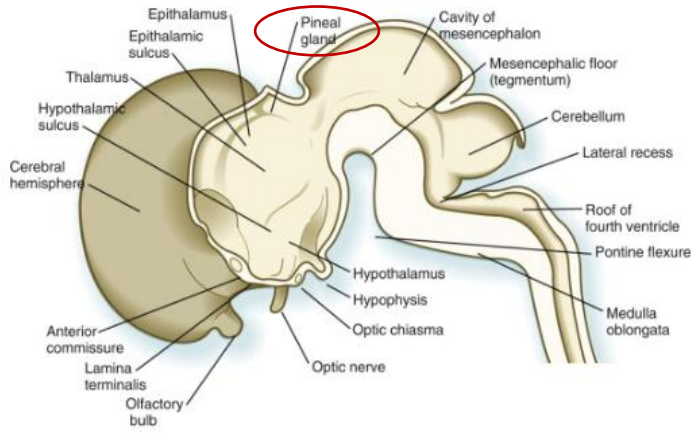
DIENCEPHALON:

EPIPHYSIS (PINEAL GLAND, pineal body):

- develops from as a median diverticulum of the caudal part of the roof of the diencephalon



<https://www.slideshare.net/MUBOSScz/lect7-endocrine-sy>



https://en.wikibooks.org/wiki/Anatomy_and_Physiology_of_Animals/Endocrine_System

<https://www.sciencedirect.com/topics/neuroscience/myelencephalon>

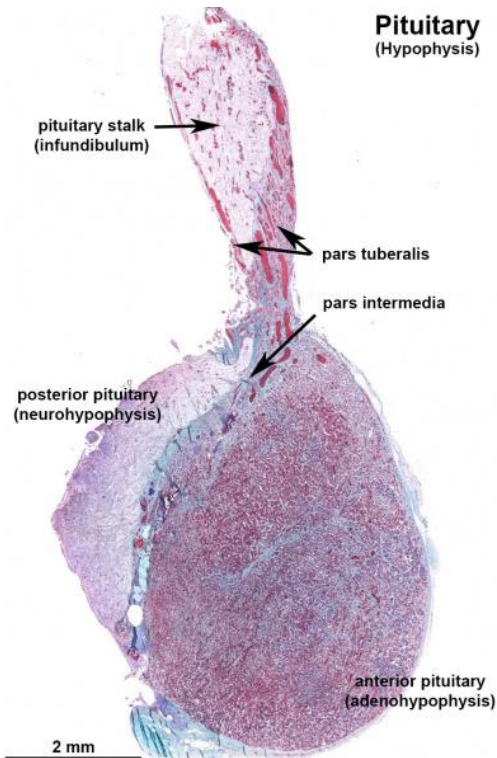
DEVELOPMENT OF BRAIN

DIENCEPHALON:

PITUITARY GLAND (hypophysis):

develops from two sources:

1. HYPOPHYSIAL DIVERTICULUM (RATHKE POUCH)
2. NEUROHYPOPHYSIAL DIVERTICULUM



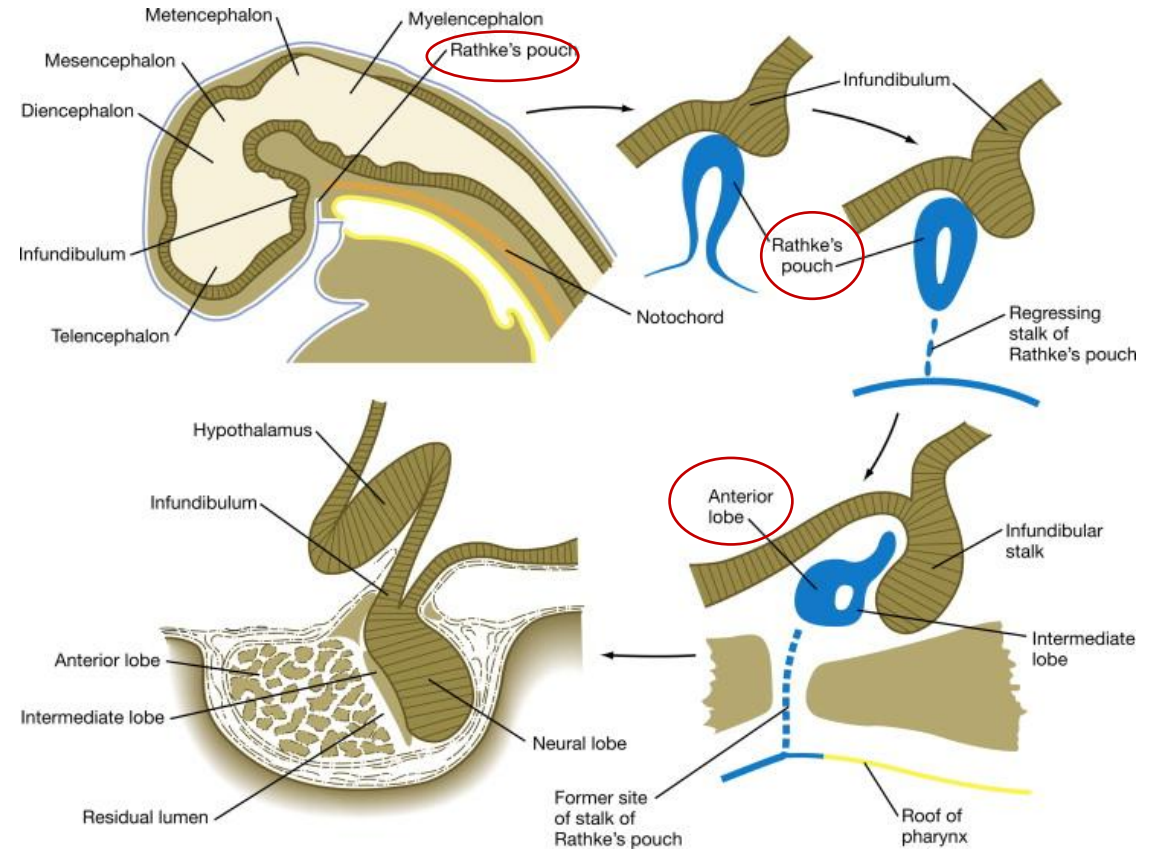
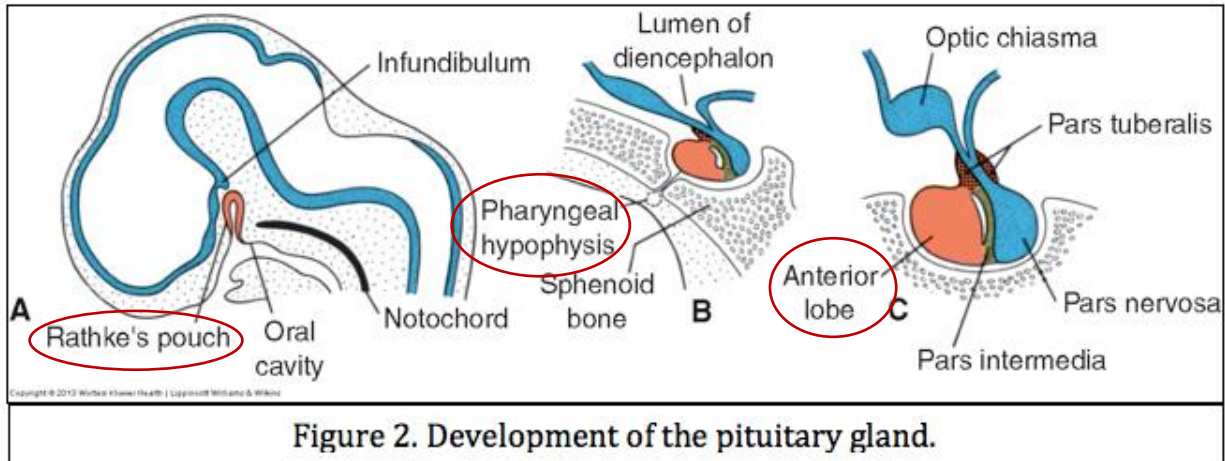
DEVELOPMENT OF BRAIN

DIENCEPHALON:

PITUITARY GLAND (hypophysis):

1. HYPOPHYSIAL DIVERTICULUM (RATHKE POUCH) :

- an upgrowth from the ectodermal roof of the stomodeum
- **adenohypophysis** (glandular part, anterior lobe) develops from this



<https://www.sciencedirect.com/topics/medicine-and-dentistry/hypophysis>

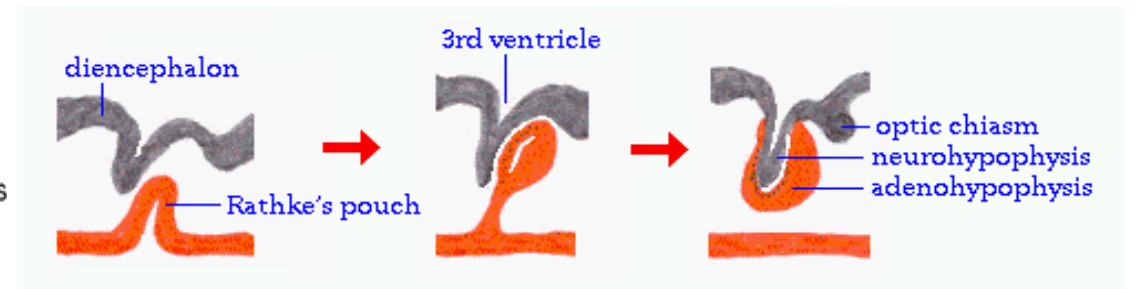
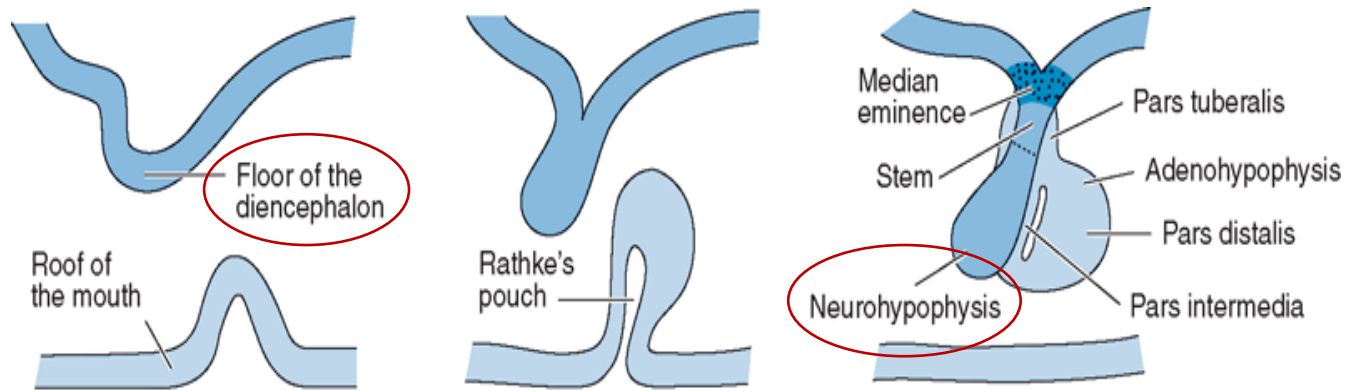
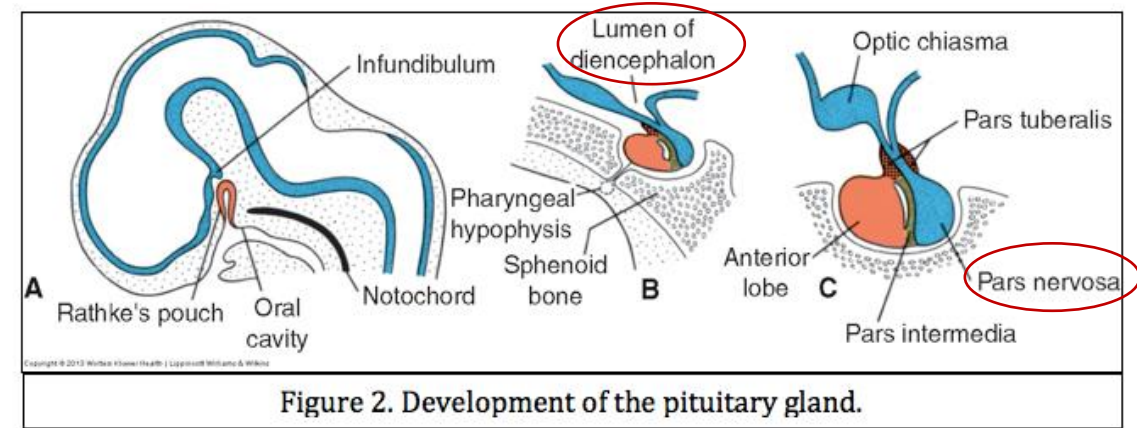
DEVELOPMENT OF BRAIN

DIENCEPHALON:

PITUITARY GALND (hypophysis):

2. NEUROHYPOPHYSIAL DIVERTICULUM:

- a downgrowth from the neuroectoderm of the diencephalon
- development of **neurohypophysis** (posterior lobe, nervous part, pars nervosa)



http://www.vivo.colostate.edu/hbooks/pathphys/endocrine/hypopit/histo_pit.html

Source: Paulsen DF: *Histology & Cell Biology: Examination & Board Review*, 5th Edition: www.accessmedicine.com

Copyright © The McGraw-Hill Companies, Inc. All rights reserved.

<https://accessmedicine.mhmedical.com/ViewLarge.aspx?figid=42047134&gbosContainerID=0&gbosid=0&groupID=0>

DEVELOPMENT OF BRAIN

DIENCEPHALON:

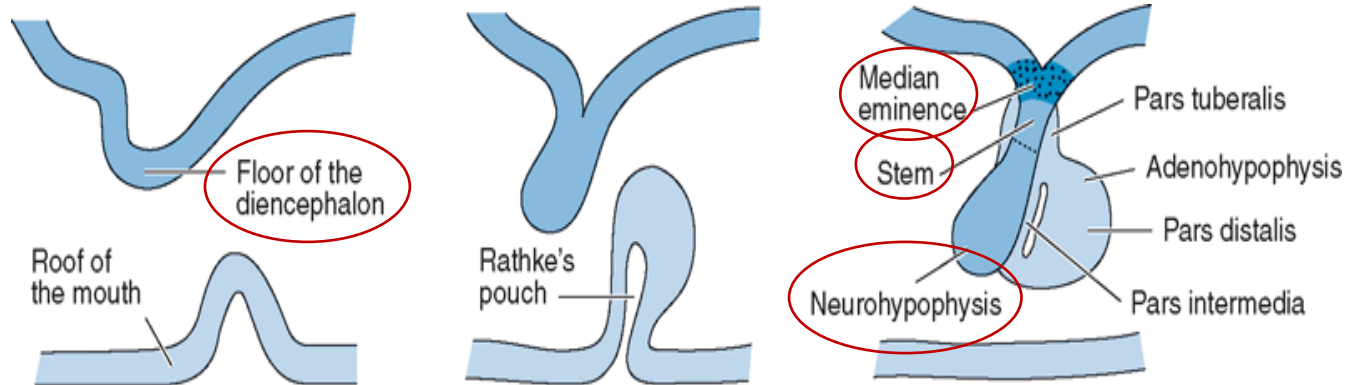
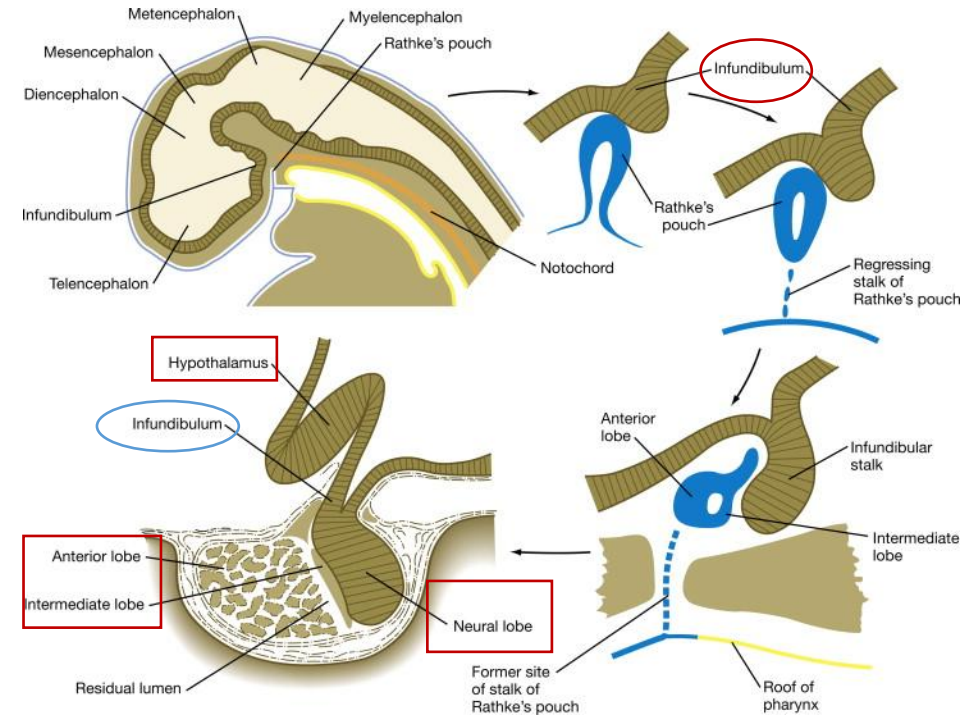
INFUNDIBULUM:

- connection between hypothalamus and hypophysis

- derived from neurohypophysial diverticulum

- gives rise to the:

1. median eminence (eminetia mediana)
2. infundibular stem
3. pars nervosa of hypophysis



Source: Paulsen DF: *Histology & Cell Biology: Examination & Board Review*, 5th Edition: www.accessmedicine.com

Copyright © The McGraw-Hill Companies, Inc. All rights reserved.

<https://accessmedicine.mhmedical.com/ViewLarge.aspx?figid=42047134&gbosContainerID=0&gbosid=0&groupID=0>

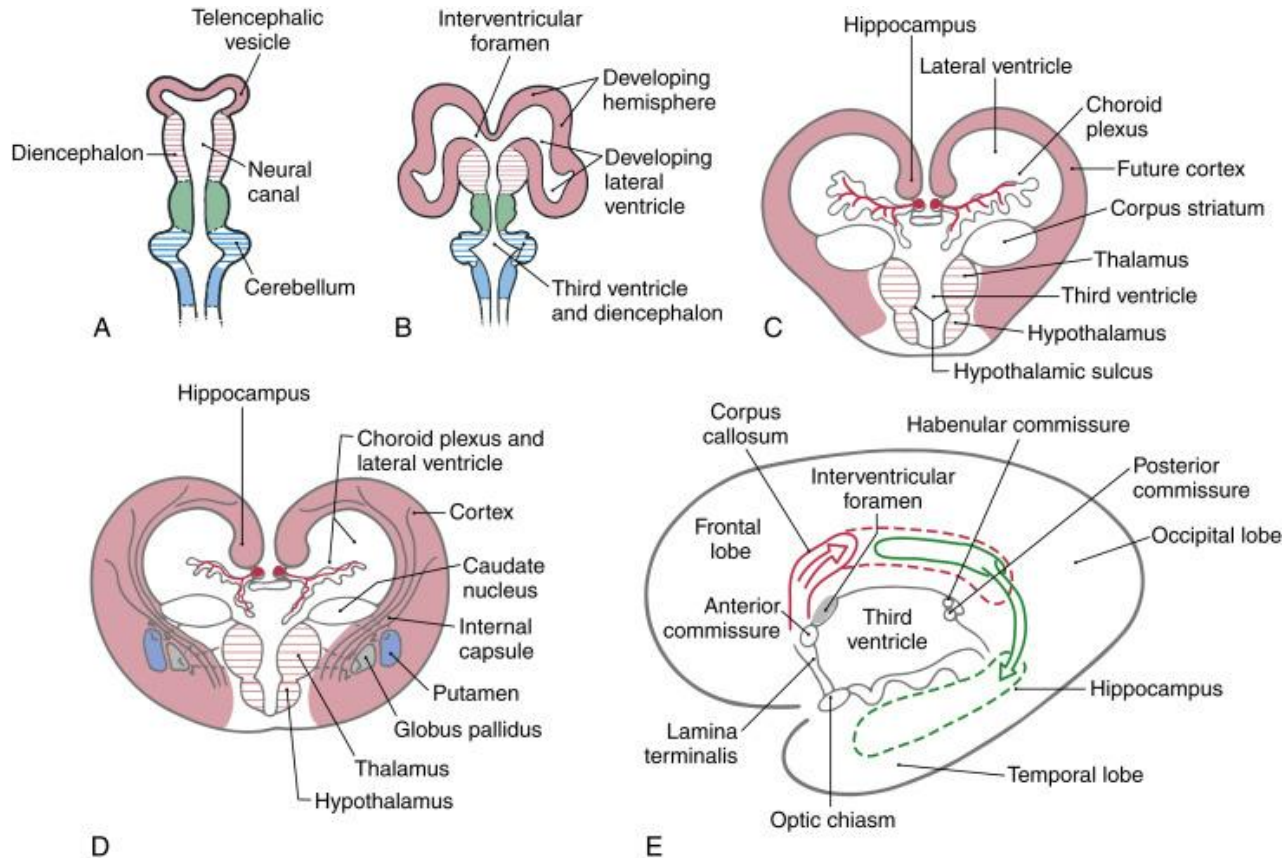
DEVELOPMENT OF BRAIN

TELENCEPHALON:

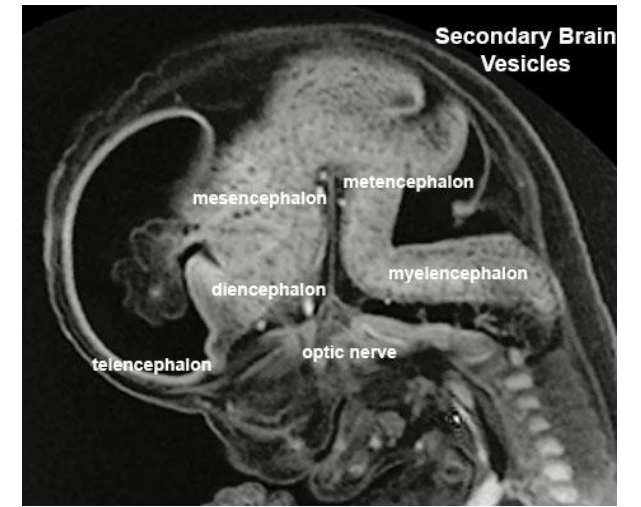
consists of:

1. median part

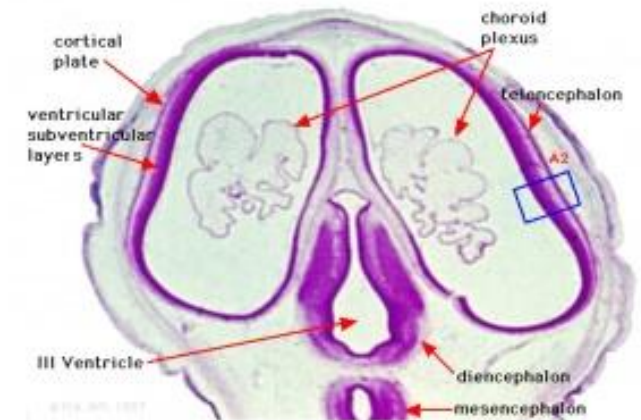
2. two lateral diverticula



<https://www.sciencedirect.com/topics/neuroscience/prosencephalon>



https://embryology.med.unsw.edu.au/embryology/index.php/Neural_System_Development



Human Embryo (Week 8, Stage 22) developing head section

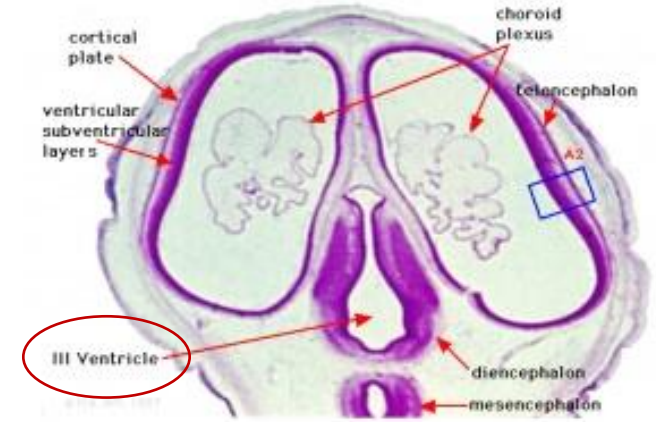
https://embryology.med.unsw.edu.au/embryology/index.php/Neural_System_Development

DEVELOPMENT OF BRAIN

TELENCEPHALON:

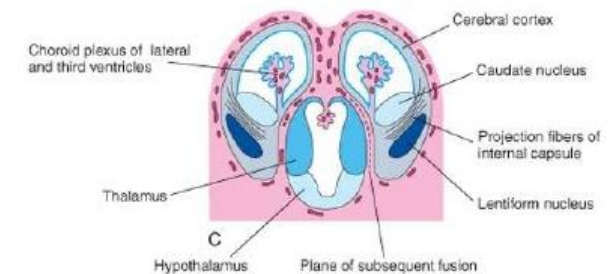
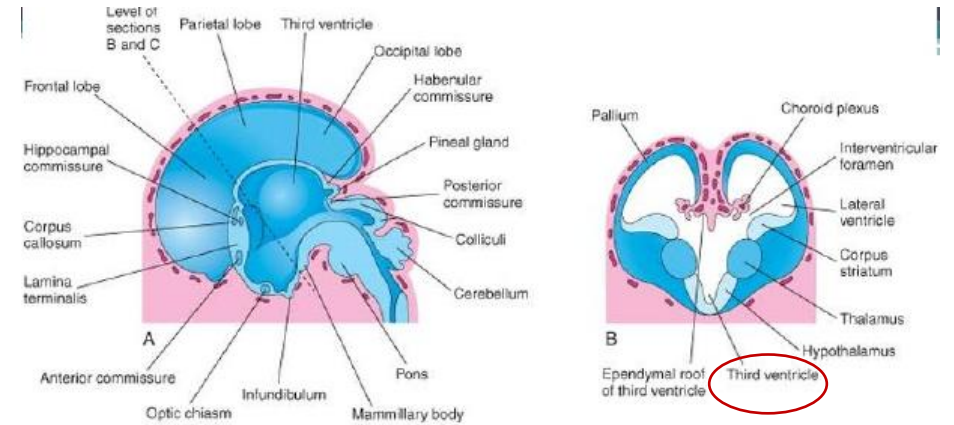
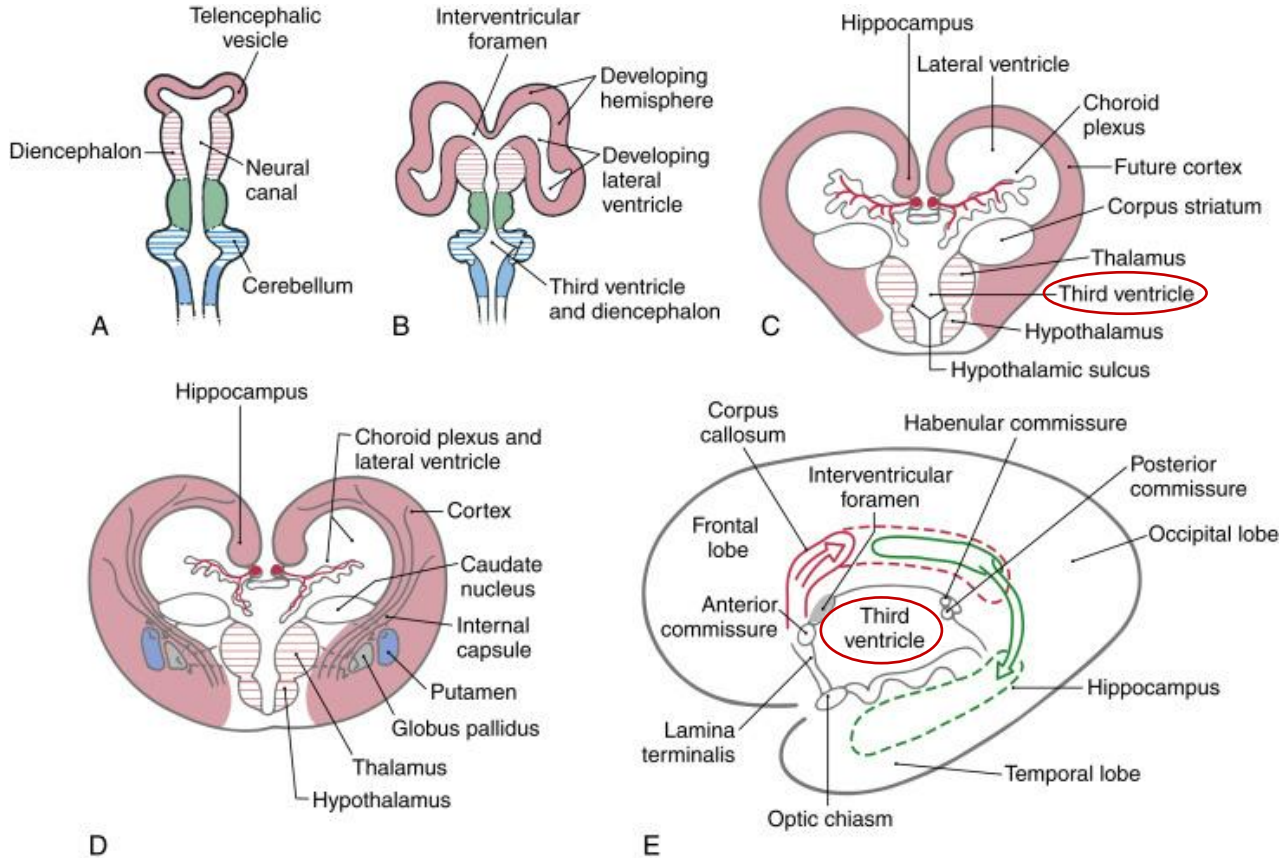
1. median part:

- the cavity of median part – forms the extreme anterior part of the 3rd ventricle



Human Embryo (Week 8, Stage 22) developing head section

https://embryology.med.unsw.edu.au/embryology/index.php/Neural_System_Development

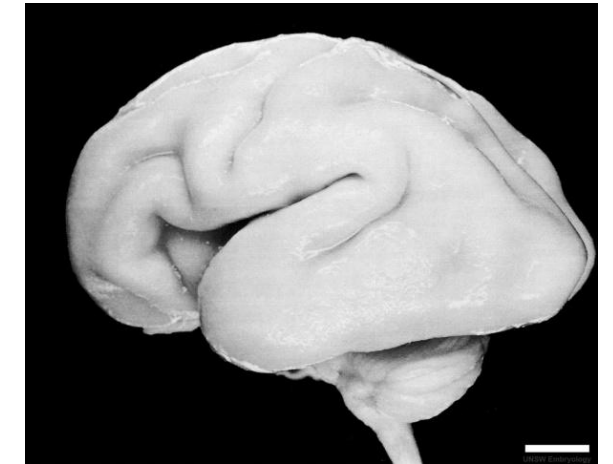
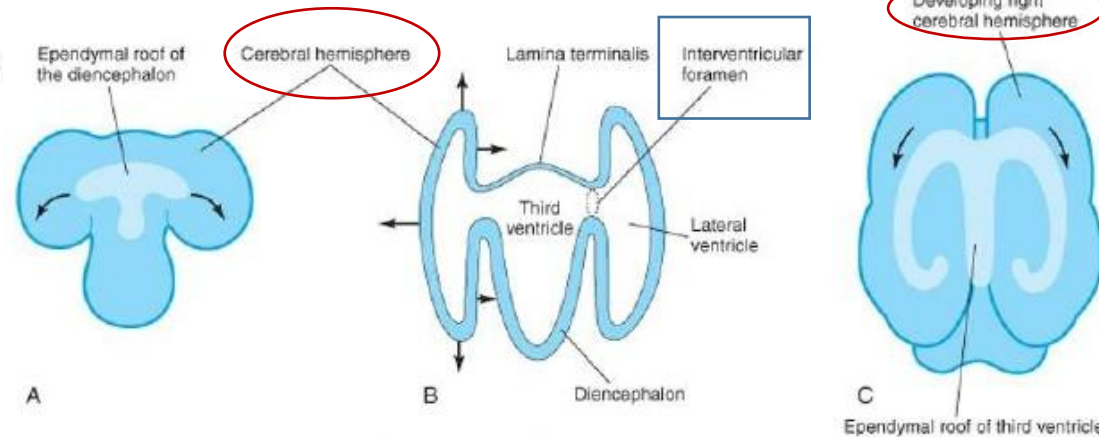
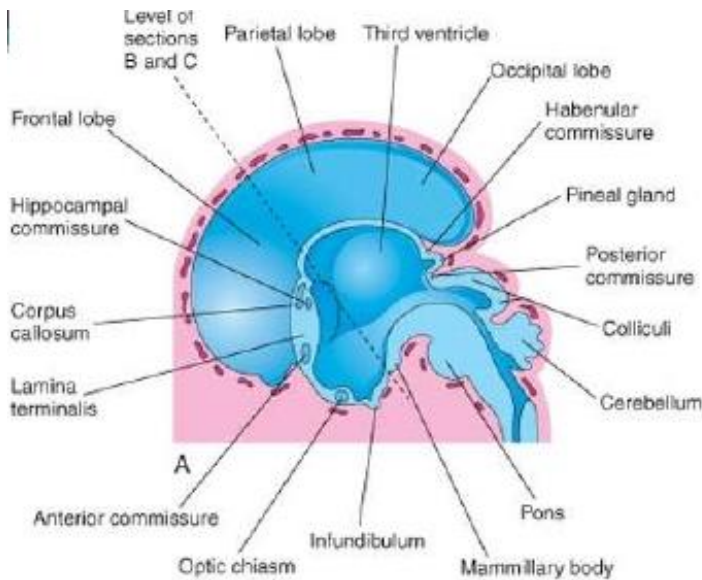
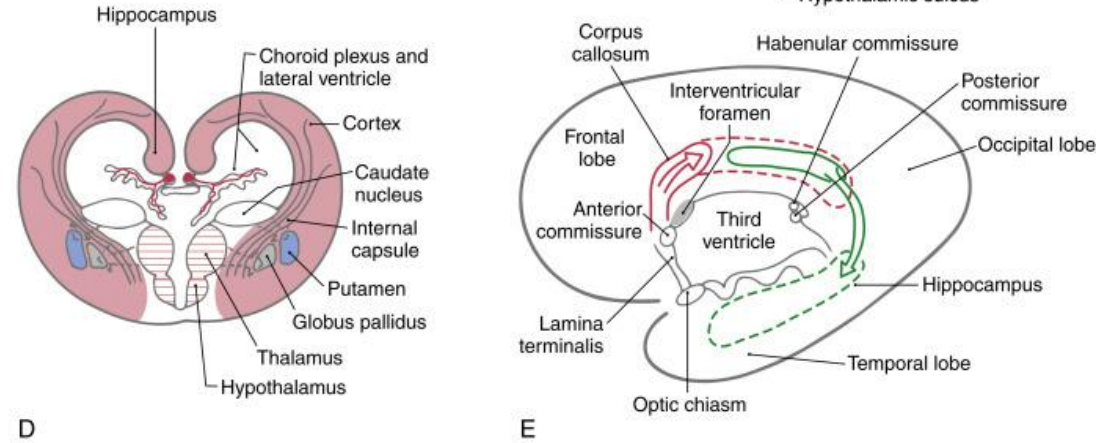
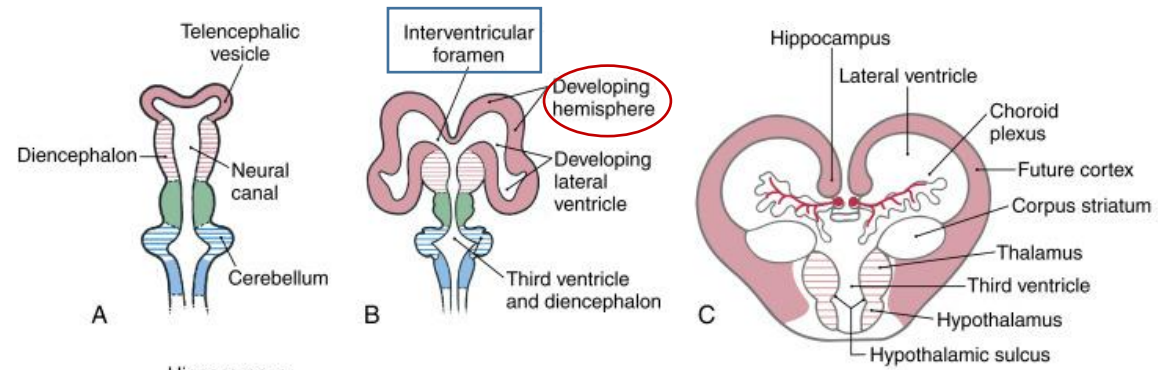


DEVELOPMENT OF BRAIN

TELENCEPHALON:

2. two lateral diverticula:

- primordia for the cerebral hemispheres



Human Fetus (CRL 240mm) Brain (left dorsolateral view)

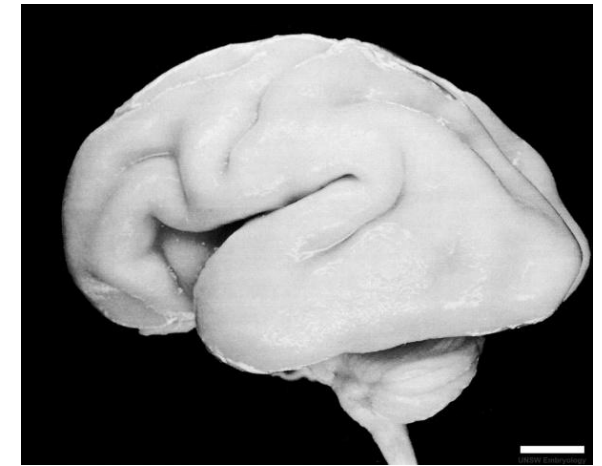
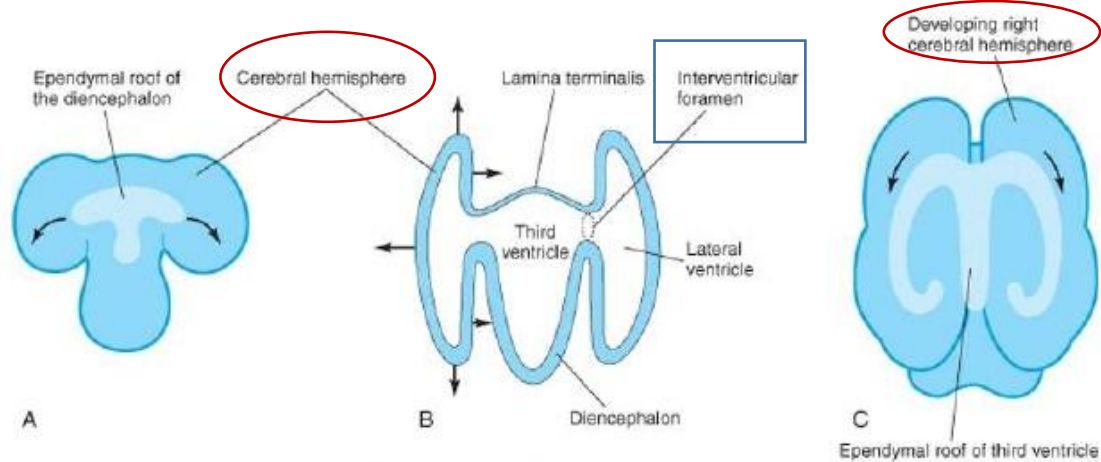
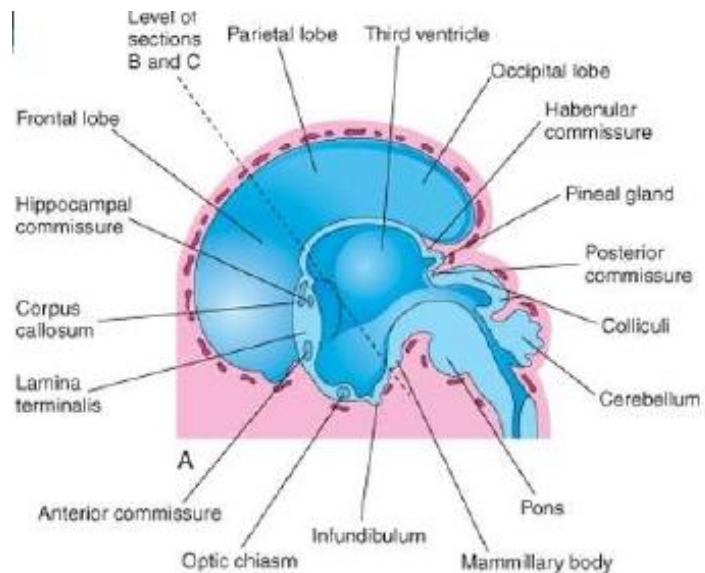
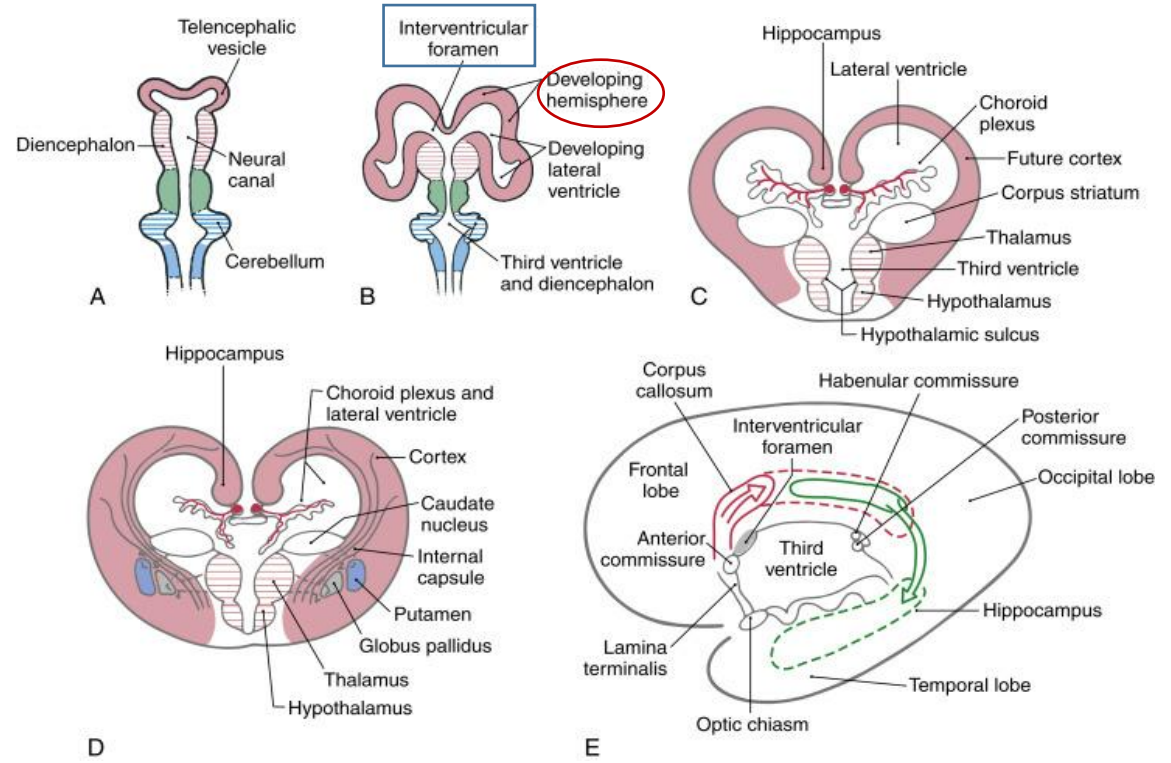
DEVELOPMENT OF BRAIN

TELENCEPHALON:

2. two lateral diverticula:

AT FIRST the cerebral hemispheres:

1. are in communication with the 3rd ventricle via the interventricular foramen
2. expand
3. cover the diencephalon, midbrain and hindbrain
4. meet each other in the midline

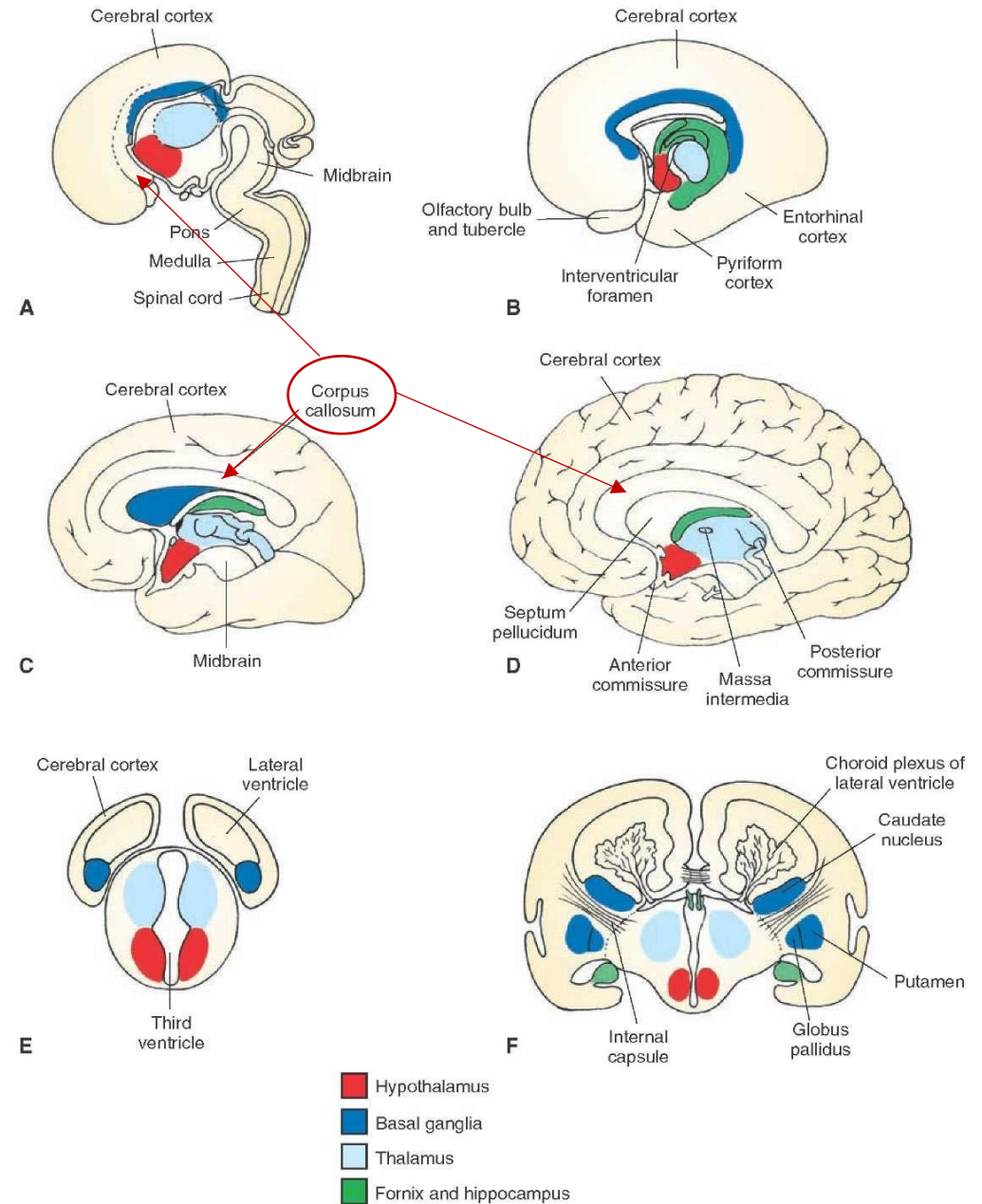


DEVELOPMENT OF BRAIN

TELENCEPHALON:

CORPUS CALLOSUM:

- prominent swelling in the floor of each cerebral hemisphere
- largest cerebral commissure
- connects the hemispheres together



DEVELOPMENT OF BRAIN

TELENCEPHALON:

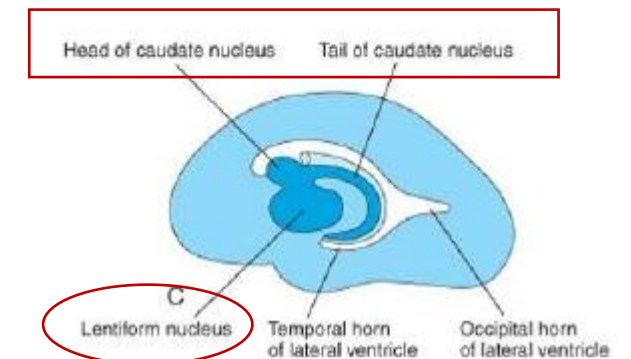
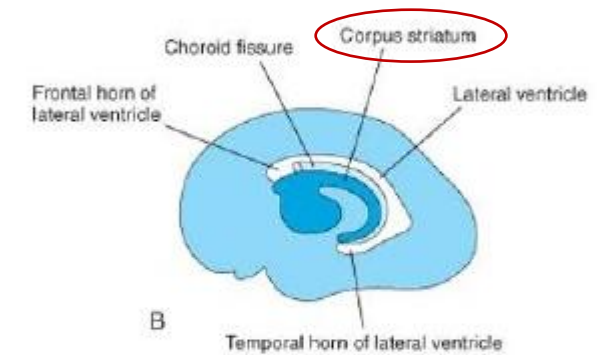
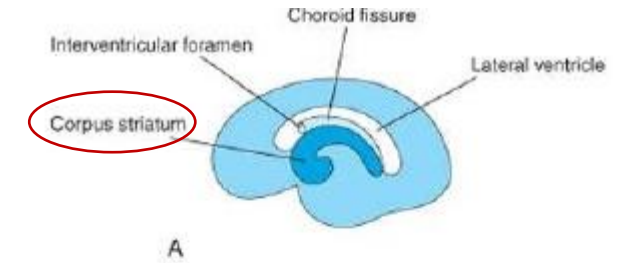
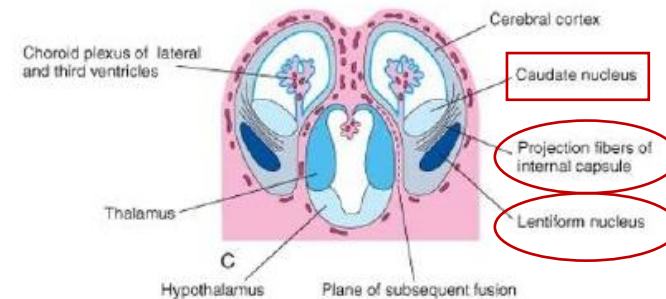
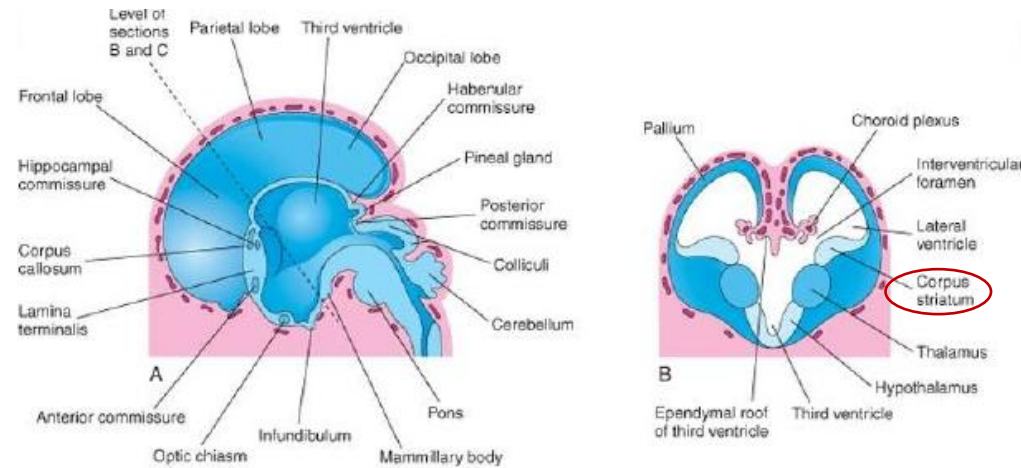
CORPUS STRIATUM:

- the cerebral hemisphere become „C” – shaped
- as the cerebral cortex differentiates – fibers passing to and from it – these fiber pathway the **INTERNAL CAPSULE**

INTERNAL CAPSULE (CAPSULA INTERNA):

- separates the corpus striatum into:

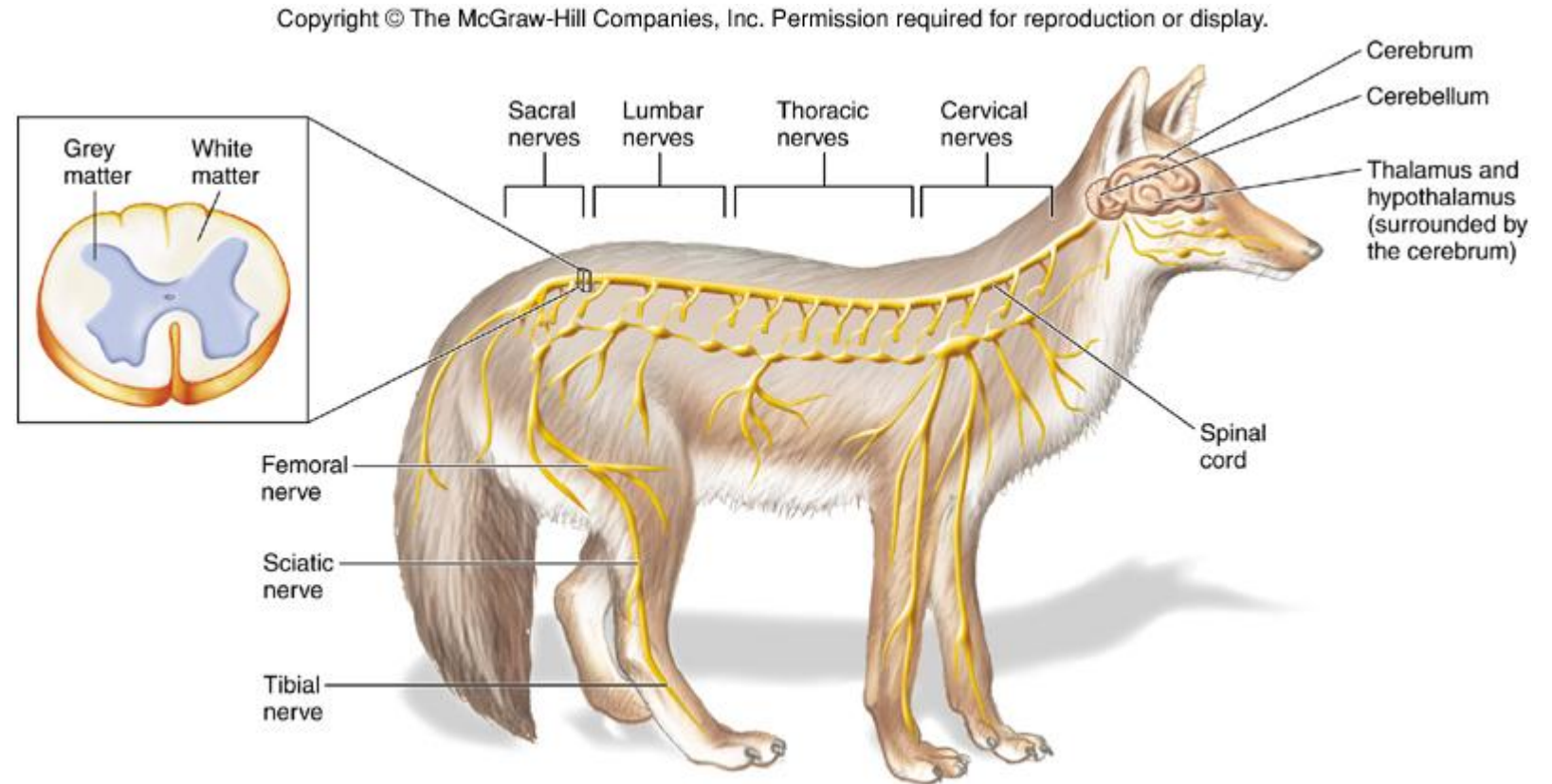
1. caudate nuclei (nucleus caudatus)
2. lentiform nuclei (nucleus lentiformis)



DEVELOPMENT OF PERIPHERAL NERVOUS SYSTEM

the peripheral nervous system consists of:

1. cranial nerves
2. spinal nerves
3. visceral nerves
4. cranial ganglia
5. spinal ganglia
6. autonomic ganglia

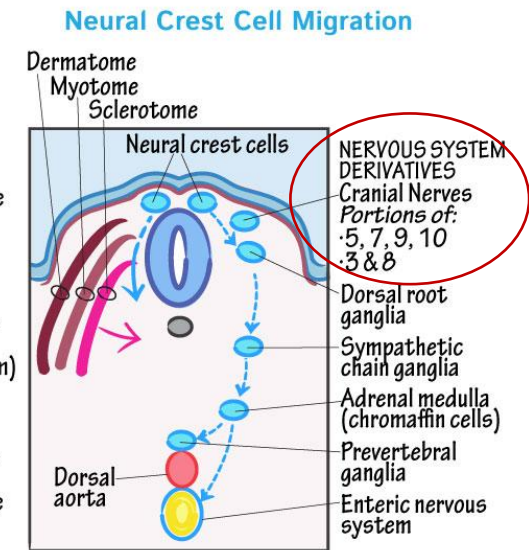
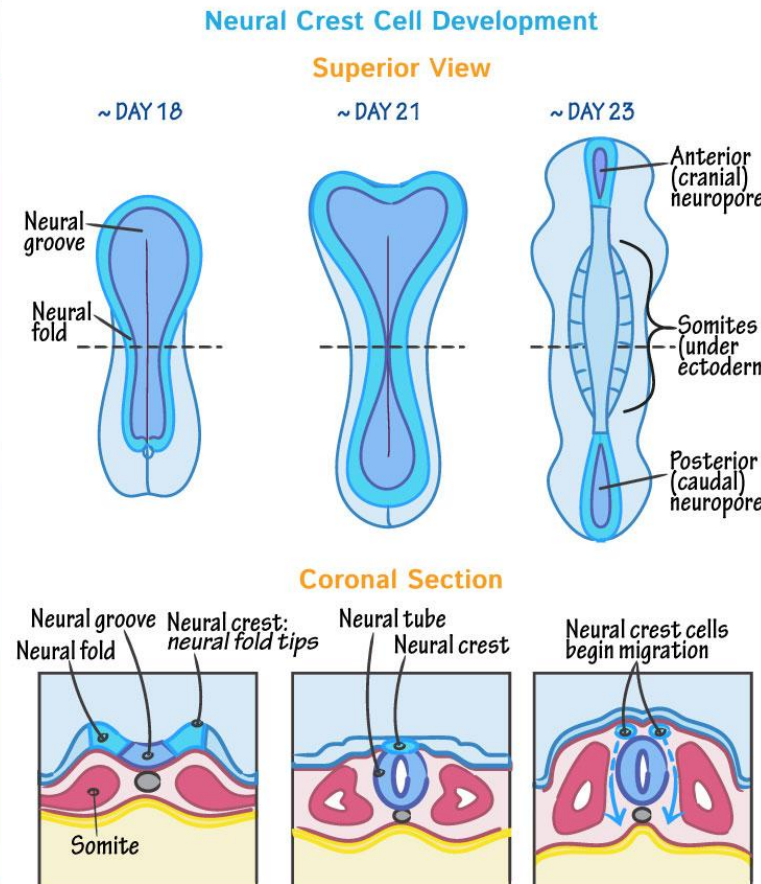
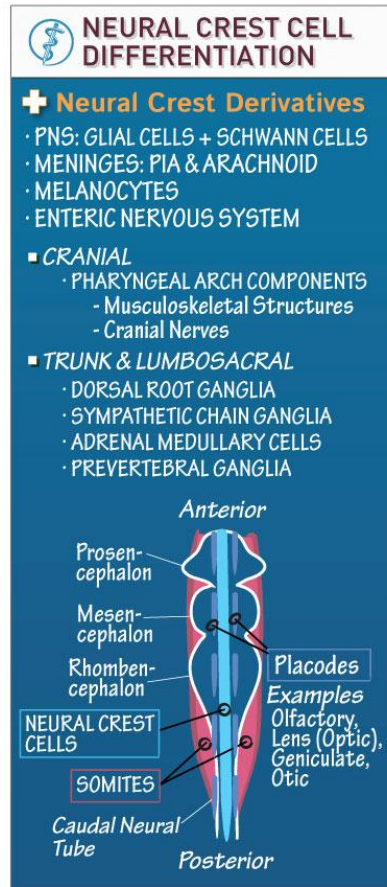


DEVELOPMENT OF PERIPHERAL NERVOUS SYSTEM

NEURAL CREST CELLS migrate to form:

I. SENSORY GANGLIA in relation to the:

1. trigeminal nerve
2. facial nerve
3. vestibulocochlear nerves
4. glossopharyngeal nerves
5. vagus nerves



☺ But don't forget....

PNS ELEMENTS

MELANOCYTES

MENINGES

MUSCULOSKELETAL ELEMENTS OF THE HEAD & NECK

DEVELOPMENT OF PERIPHERAL NERVOUS SYSTEM

NEURAL CREST CELLS differentiate into:

II. MULTIPOLAR (AUTONOMIC) GANGLIA including:

1. ganglia of the sympathetic trunks
2. ganglia of parasympathetic system

NEURAL CREST CELL DIFFERENTIATION

+ Neural Crest Derivatives

- PNS: GLIAL CELLS + SCHWANN CELLS
- MENINGES: PIA & ARACHNOID
- MELANOCYTES
- ENTERIC NERVOUS SYSTEM

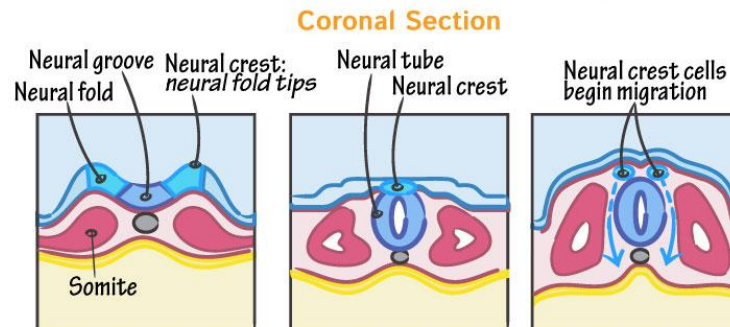
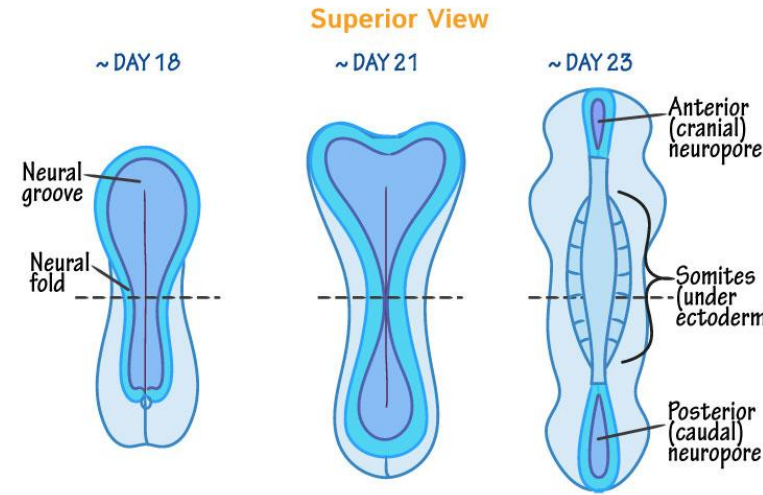
■ **CRANIAL**

- PHARYNGEAL ARCH COMPONENTS
 - Musculoskeletal Structures
 - Cranial Nerves

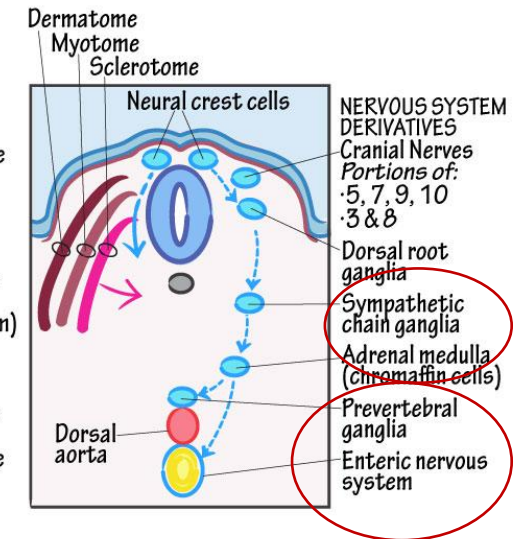
■ **TRUNK & LUMBOSACRAL**

- DORSAL ROOT GANGLIA
- SYMPATHETIC CHAIN GANGLIA
- ADRENAL MEDULLARY CELLS
- PREVERTEBRAL GANGLIA

Neural Crest Cell Development



Neural Crest Cell Migration



⦿ But don't forget....

PNS ELEMENTS
MELANOCYTES
MENINGES
MUSCULOSKELETAL ELEMENTS OF THE HEAD & NECK

DEVELOPMENT OF PERIPHERAL NERVOUS SYSTEM

NEURAL CREST CELLS differentiate into:

III. Chromaffin cells of the suprarenal glands

NEURAL CREST CELL DIFFERENTIATION

+ Neural Crest Derivatives

- PNS: GLIAL CELLS + SCHWANN CELLS
- MENINGES: PIA & ARACHNOID
- MELANOCYTES
- ENTERIC NERVOUS SYSTEM

■ **CRANIAL**

- PHARYNGEAL ARCH COMPONENTS
 - Musculoskeletal Structures
 - Cranial Nerves

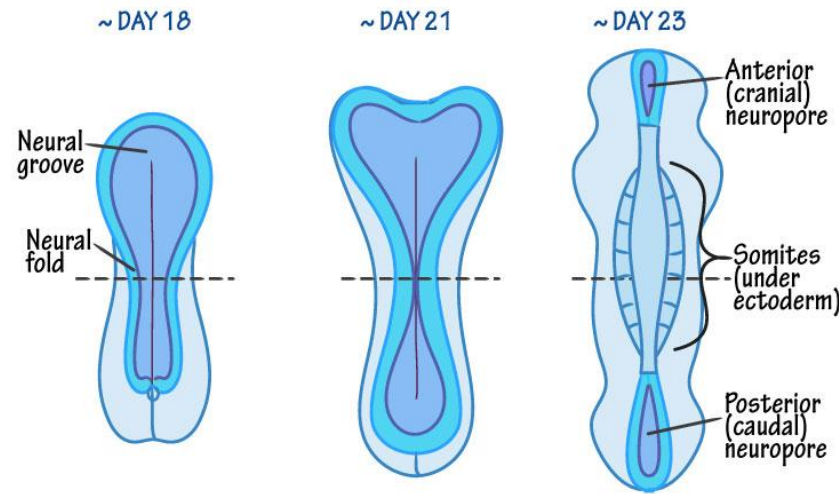
■ **TRUNK & LUMBOSACRAL**

- DORSAL ROOT GANGLIA
- SYMPATHETIC CHAIN GANGLIA
- ADRENAL MEDULLARY CELLS
- PREVERTEBRAL GANGLIA

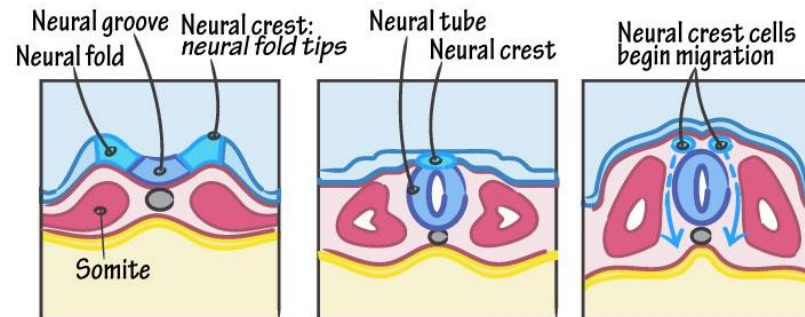
Examples: Olfactory, Lens (Optic), Geniculate, Otic

Neural Crest Cell Development

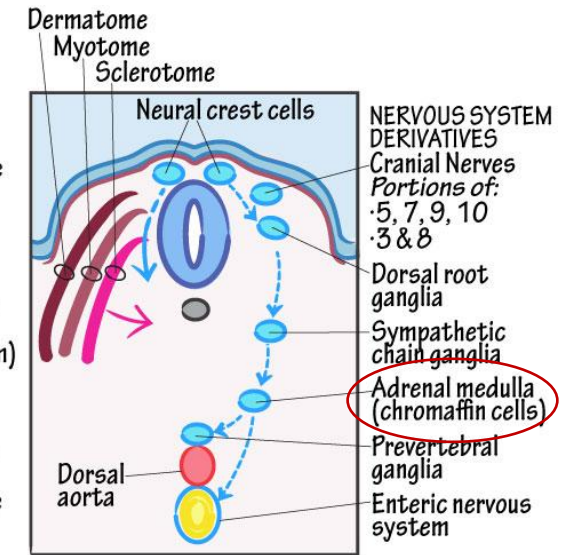
Superior View



Coronal Section



Neural Crest Cell Migration

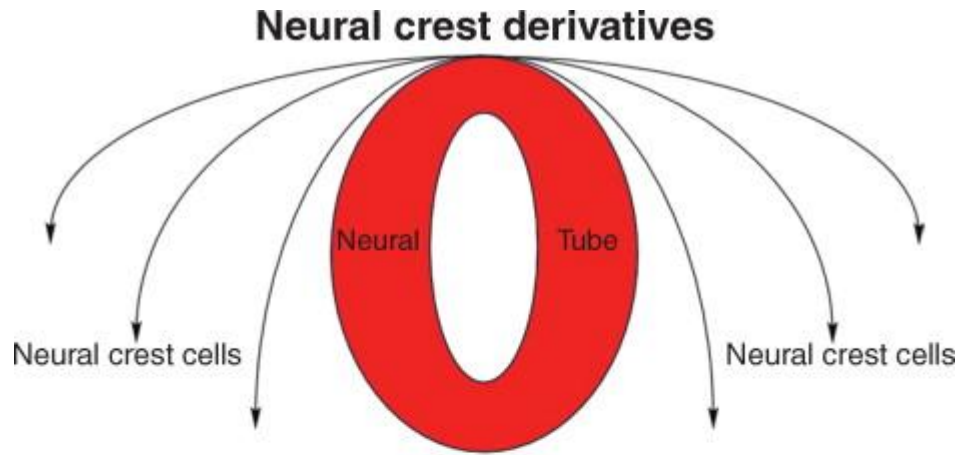


☞ But don't forget....

PNS ELEMENTS
MELANOCYTES
MENINGES
MUSCULOSKELETAL ELEMENTS OF THE HEAD & NECK

DEVELOPMENT OF PERIPHERAL NERVOUS SYSTEM

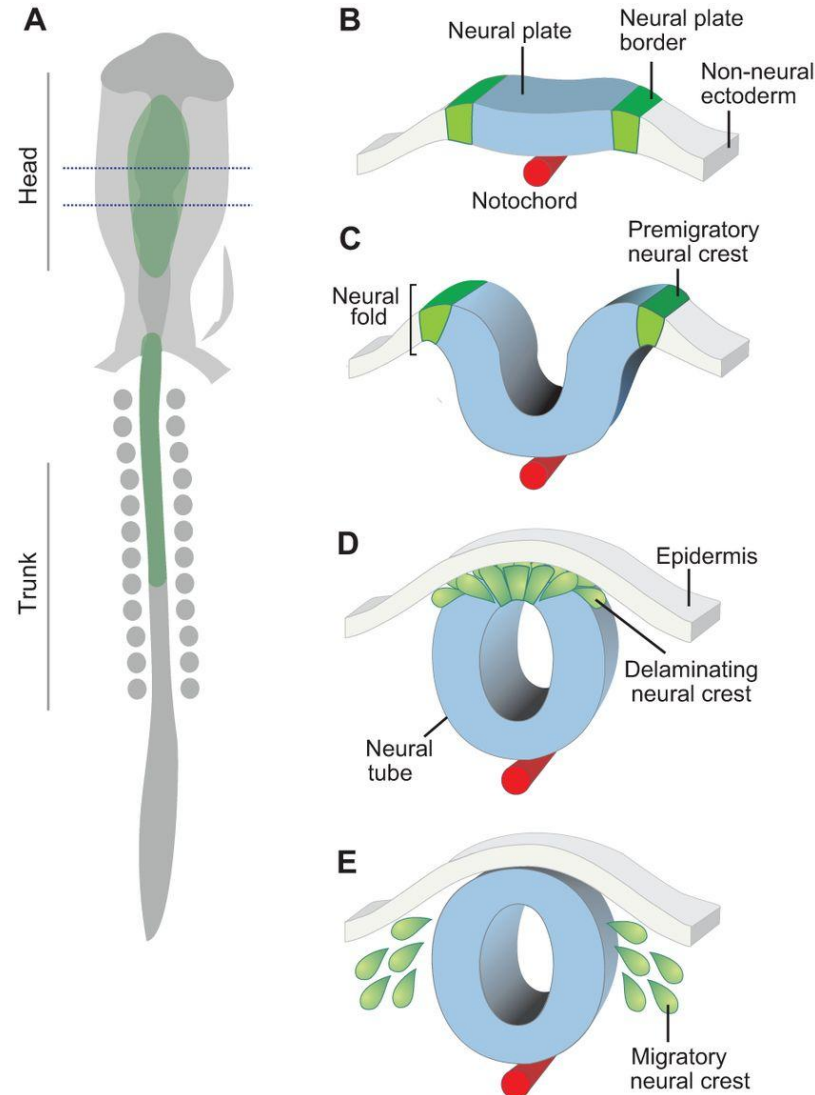
NEURAL CREST CELLS DERIVATES:



Cell type and tissue contributions

Sensory neurons
Cholinergic neurons
Adrenergic neurons
Rohon-Beard cells
Schwann cells
Glial cells
Chromaffin cells
Parafollicular cells
Calcitonin producing cells
Melanocytes
Chondroblasts, chondrocytes
Osteoblasts, osteocytes
Odontoblasts
Fibroblasts
Cardiac mesenchyme
Striated myoblasts

Spinal ganglia
Thyroid gland
Ultimobranchial body
Adrenal gland
Teeth
Dentine
Connective tissue
Adipose tissue
Smooth muscles
Cardiac septa
Dermis
Cornea
Endothelia
Adipocytes
Mesenchymal cells
Smooth myoblasts



F Neural crest derivatives

Mesenchymal cells
Chondroblasts/chondrocytes
Osteoblasts/osteocytes
Fibroblasts
Odontoblasts
Cardiac mesenchyme
Myoblasts
Adipocytes

Neuronal cells
Sensory neurons
Cholinergic neurons
Adrenergic neurons
Satellite cells
Schwann cells
Glial cells

Secretory cells
Chromaffin cells
Parafollicular cells
Calcitonin-producing cells

Pigmented cells
Melanocytes

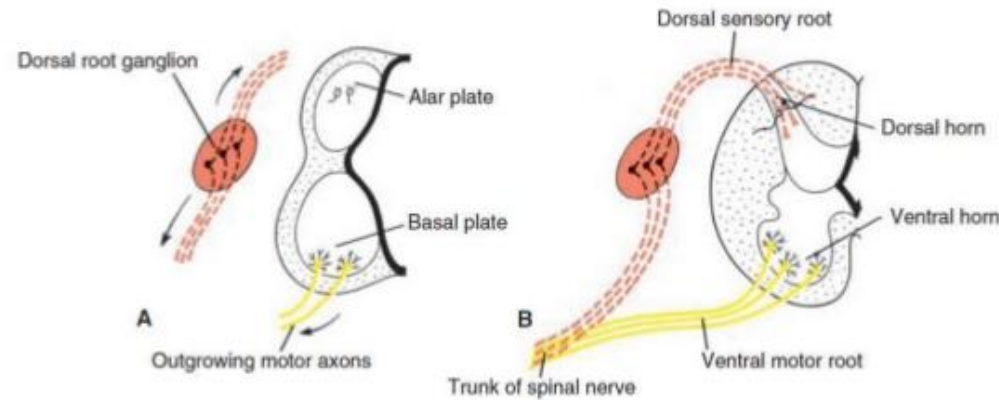
<http://dev.biologists.org/content/142/2/242>

SPINAL NERVES

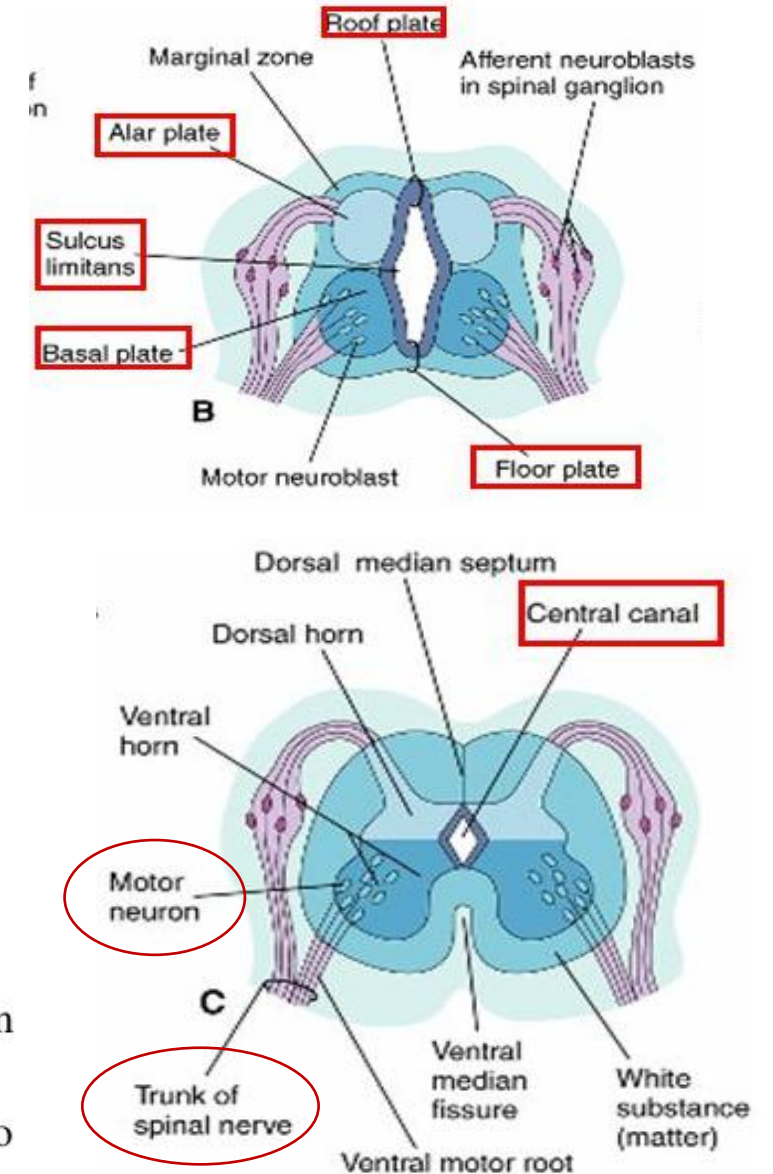
MOTOR nerve fibers:

- arising from the spinal cord
- at the end of the 4th week
- arise from the cells in the basal plates of the spinal cord (alpha – motoneurons)
- form the ventral nerve root

DEVELOPMENT OF SPINAL NERVE



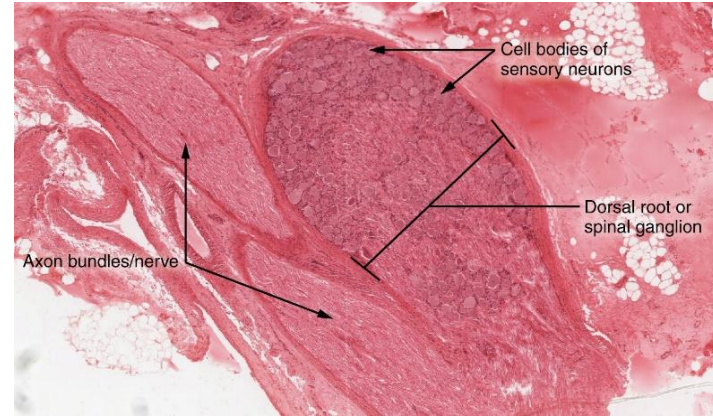
- Motor axons growing out from neurons in the basal plate
- Sensory components arise centrally and peripherally from growing fibers of nerve cells in the dorsal root ganglion.
- Nerve fibers of the ventral motor and dorsal sensory roots join to form the trunk of the spinal nerve.



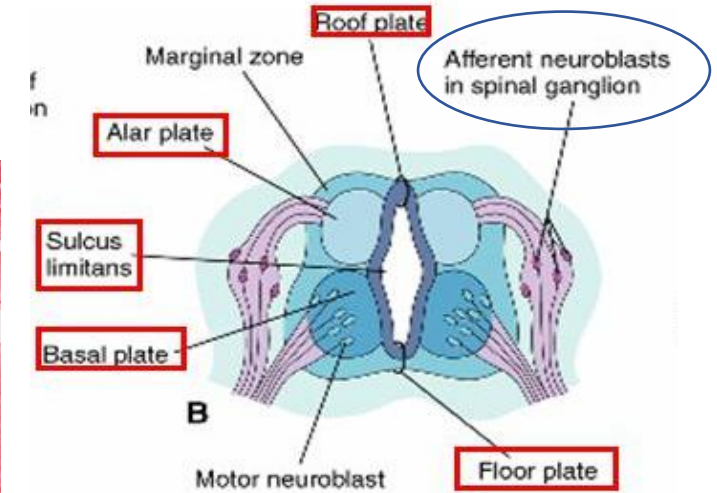
SPINAL NERVES

SENSORY nerve fibers:

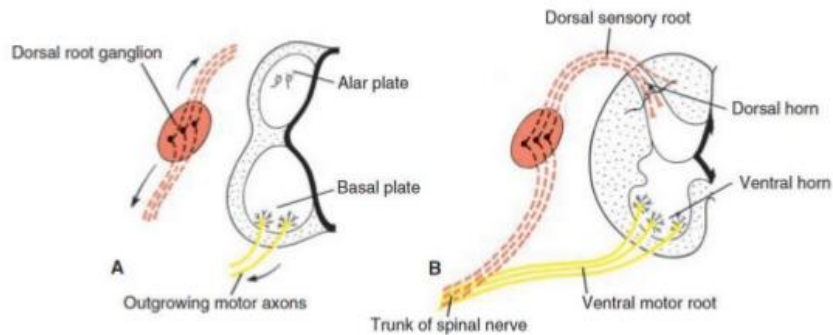
- axons derived from the neural crest cells (later as the spinal ganglion cells)
- these neural crest cells become spinal ganglion cells
- fibers from the dorsal nerve root



<http://oerpub.github.io/epubjs-demo-book/content/m46553.xhtml>

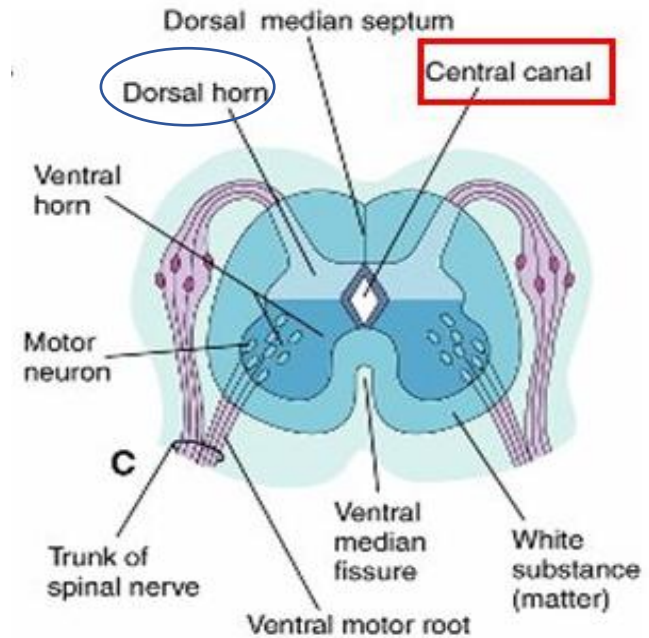
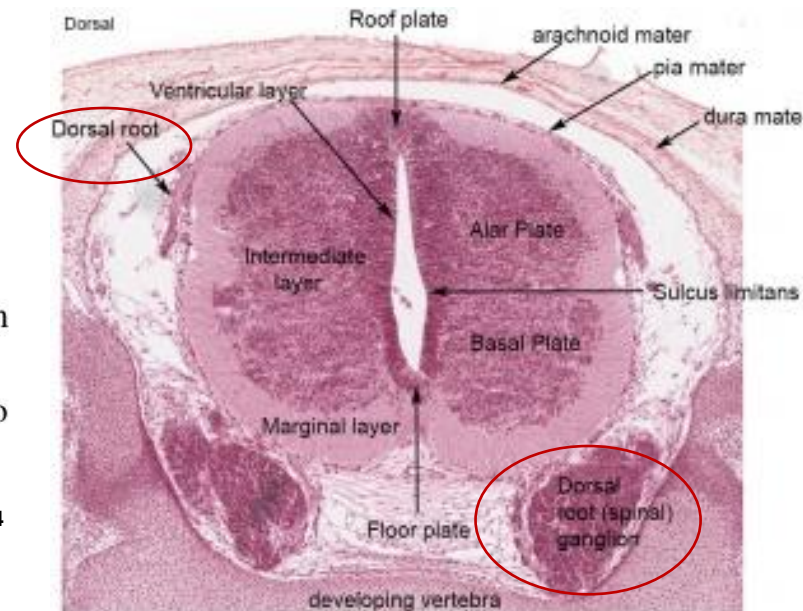


DEVELOPMENT OF SPINAL NERVE



- Motor axons growing out from neurons in the basal plate
- Sensory components arise centrally and peripherally from growing fibers of nerve cells in the dorsal root ganglion.
- Nerve fibers of the ventral motor and dorsal sensory roots join to form the trunk of the spinal nerve.

<https://www.slideshare.net/DrMohammadMahmoud/development-of-nervous-system-73615684>



BIBLIOGRAPHY

The developing human : clinically oriented embryology by Moore, Keith L

Langman's Medical Embryology Thomas W. Sadler

Essentials of Domestic Animal Embryology, 1st Edition, Poul Hyttel, Fred Sinowatz, Morten Vejlsted, Keith Betteridge

YOUTUBE VIDEO:

<https://www.youtube.com/watch?v=Cu4IQYbOzzY>

<https://www.youtube.com/watch?v=JV0INvrpvJ0>

<https://www.youtube.com/watch?v=vvBBFOu9h1w>

https://www.youtube.com/watch?v=4Swn8_Jnlss