

# **DEVELOPMENT OF THE HEART**

**Andrea Heinzlmann**

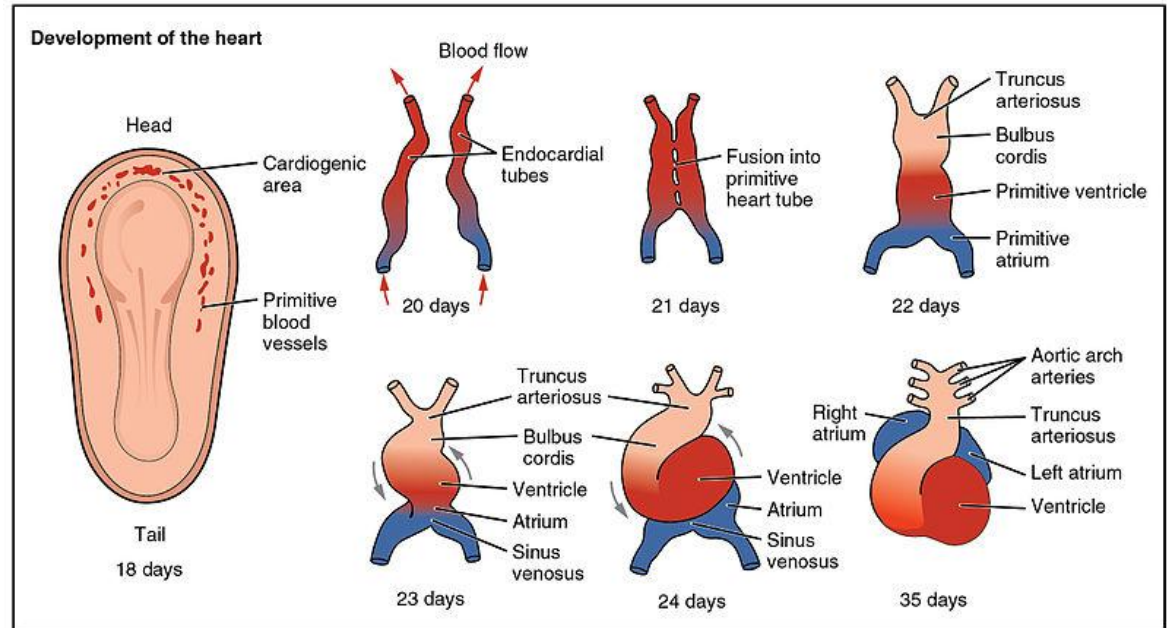
**University of Veterinary Medicine, Budapest**

**Department of Anatomy and Histology**

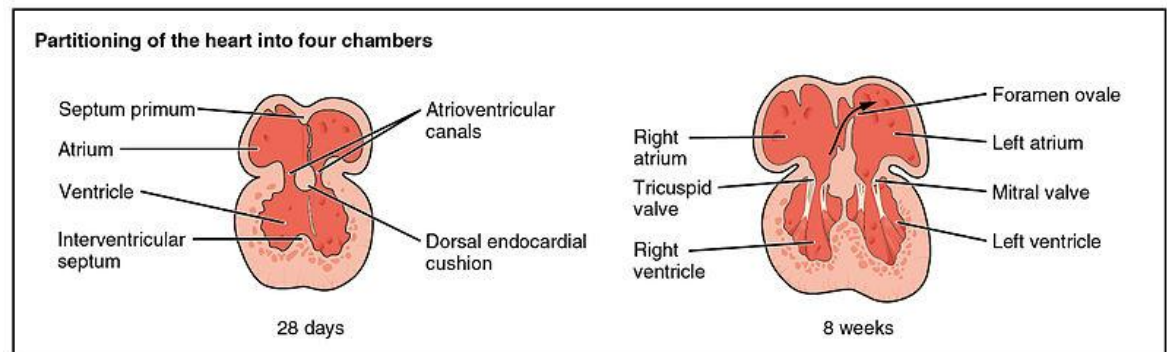
**Embryology Course**

# EARLY DEVELOPMENT

- the adult heart is a modified blood vessel
- its tunica media is primarily cardiac muscle

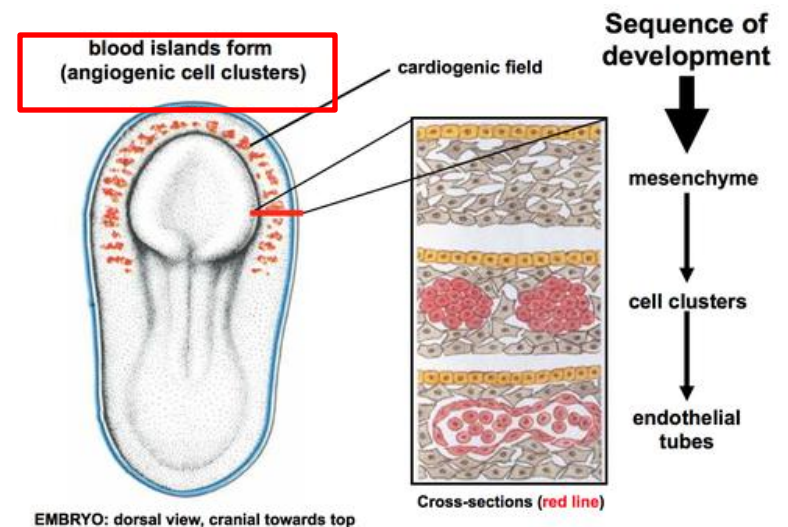
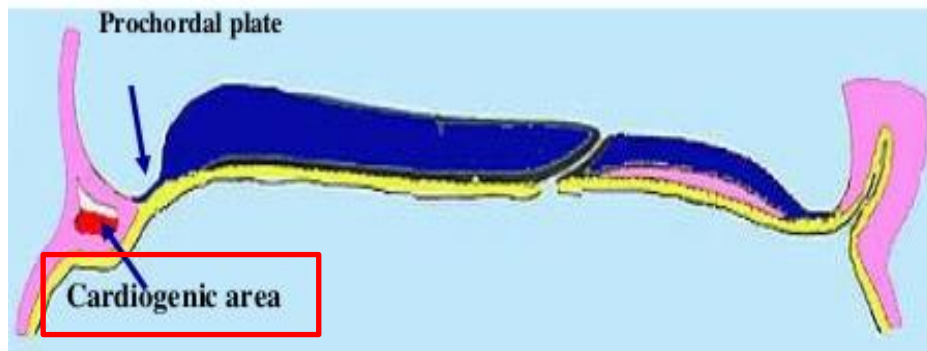

Development of the human heart during the first eight weeks (top), and the formation of the heart chambers (bottom). In this figure, the blue and red colors represent blood inflow and outflow (not venous and arterial blood). Initially, all venous blood flows from the tail/atria to the ventricles/head, a very different pattern from that of an adult.

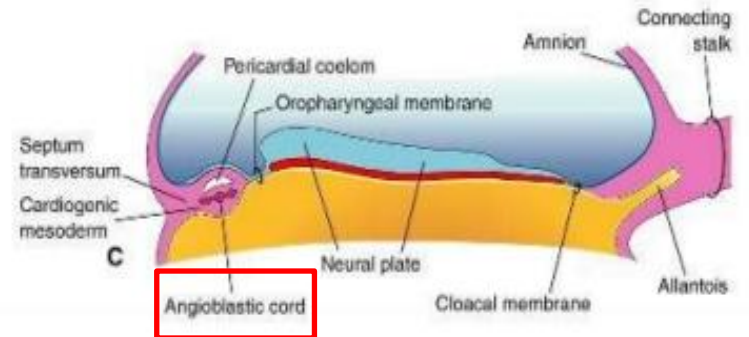
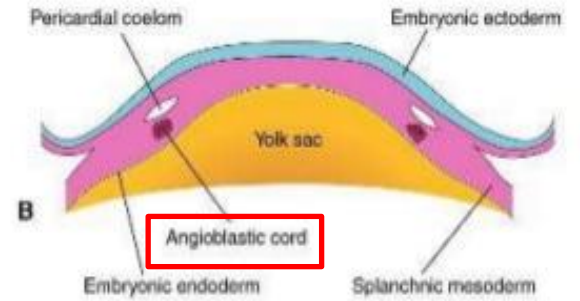
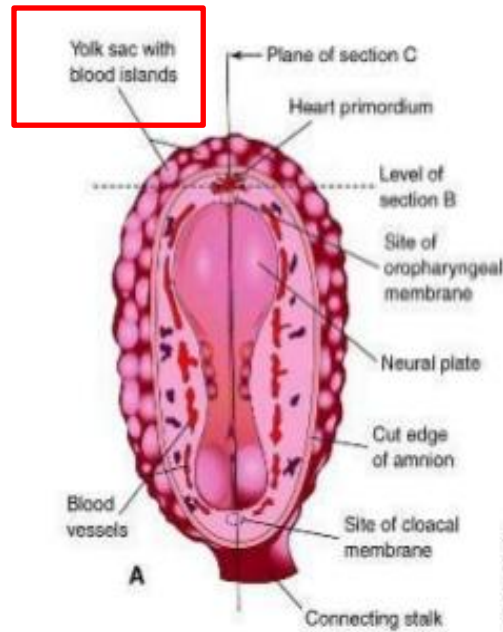
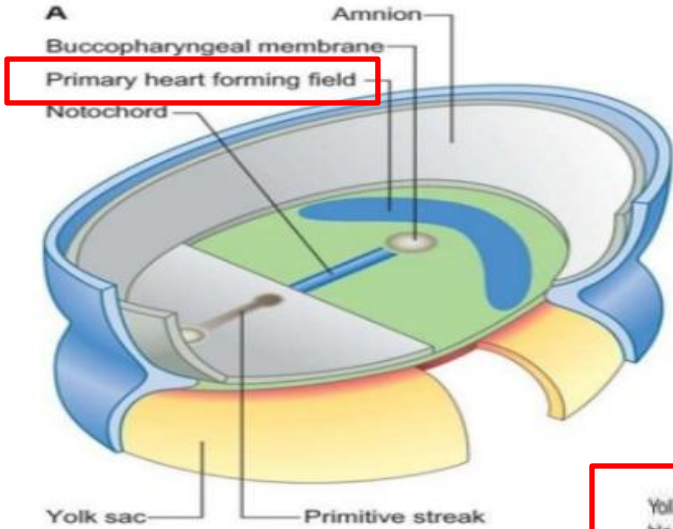


# FORMATION OF PRIMITIVE HEART TUBE

1. the primordia of the heart first appears as clusters of angioblastic cells between the mesoderm of the common pleural – pericardial cavity (coelom – body cavity) and the underlying mesoderm
2. these primordia referred to as the cardiogenic mesoderm appear around the 4 – 5 somite stage
3. the angioblastic cells are near the underlying endoderm
4. by the 6 – 7 somite stage, more angioblastic cells have joined the cardiogenic mesoderm – and the clusters of cells formed into cords
5. such cords of cells form the aorta and the vitelline veins in the future embrionic area
6. the cords of angioblastic cells are bilaterally symmetric – they form vesicles – they fused to form tubes lined by endothelium

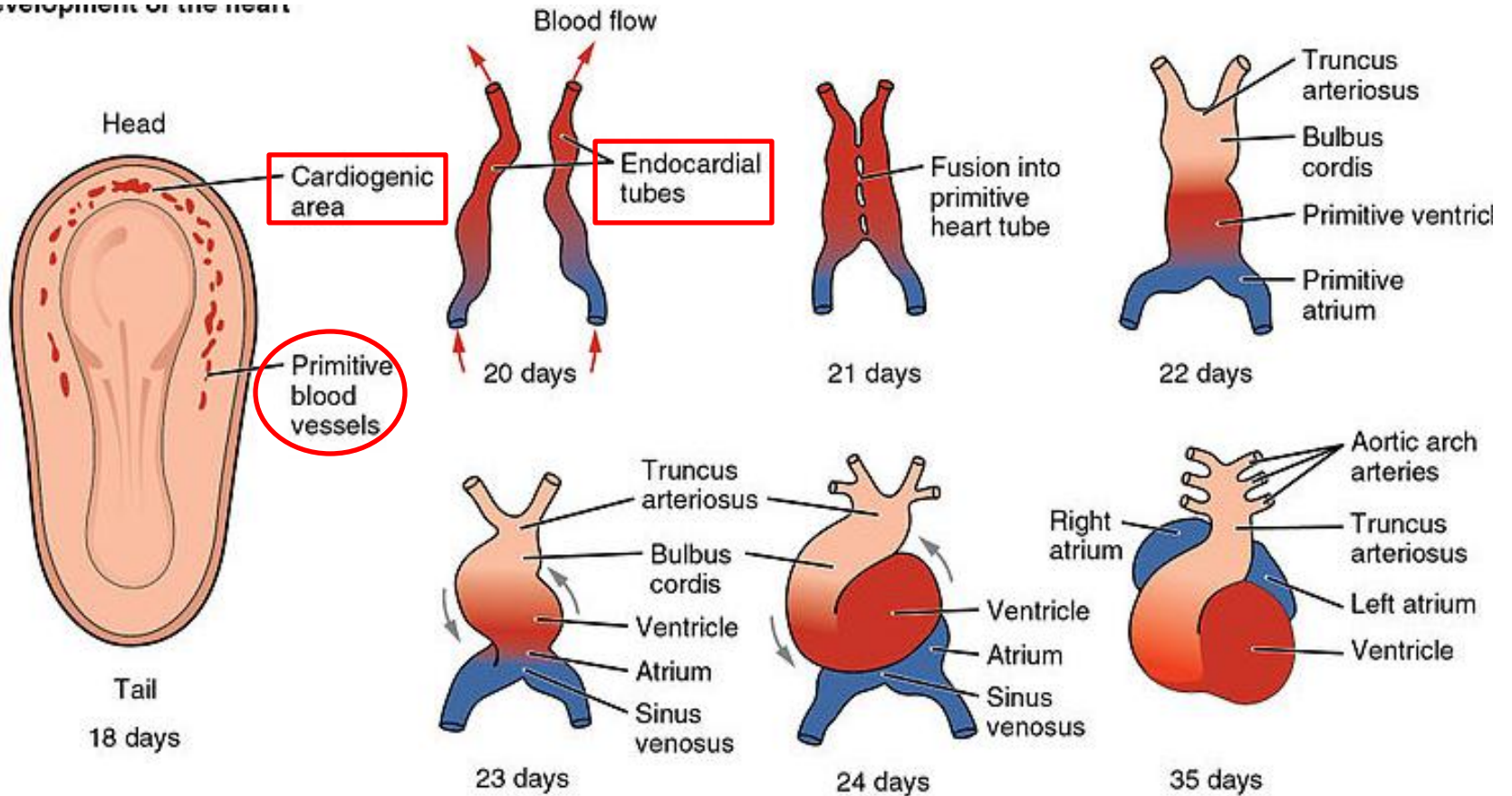


# FORMATION OF PRIMITIVE HEART TUBE



# FORMATION OF PRIMITIVE HEART TUBE

Development of the heart



# FORMATION OF PRIMITIVE HEART TUBE

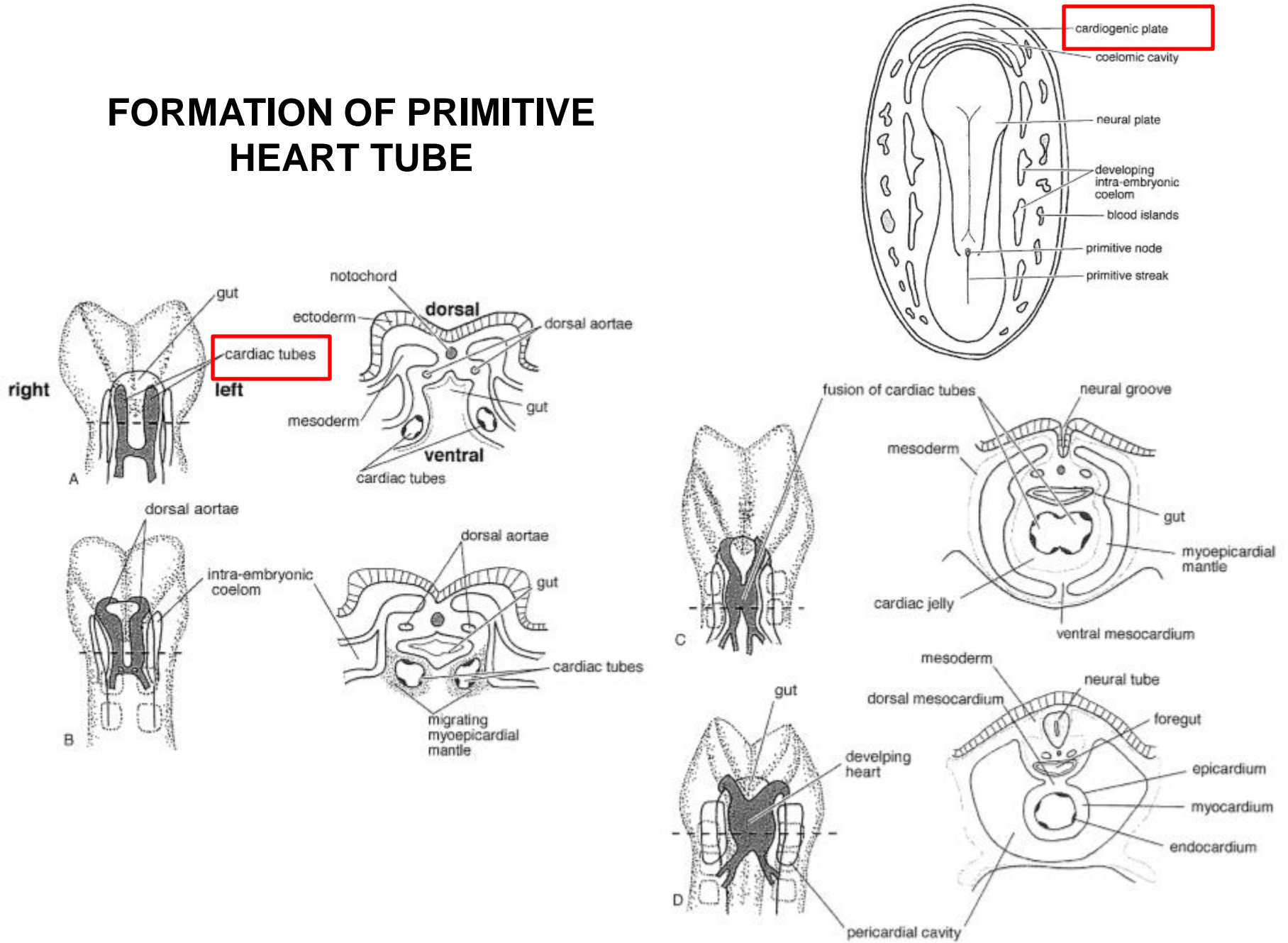
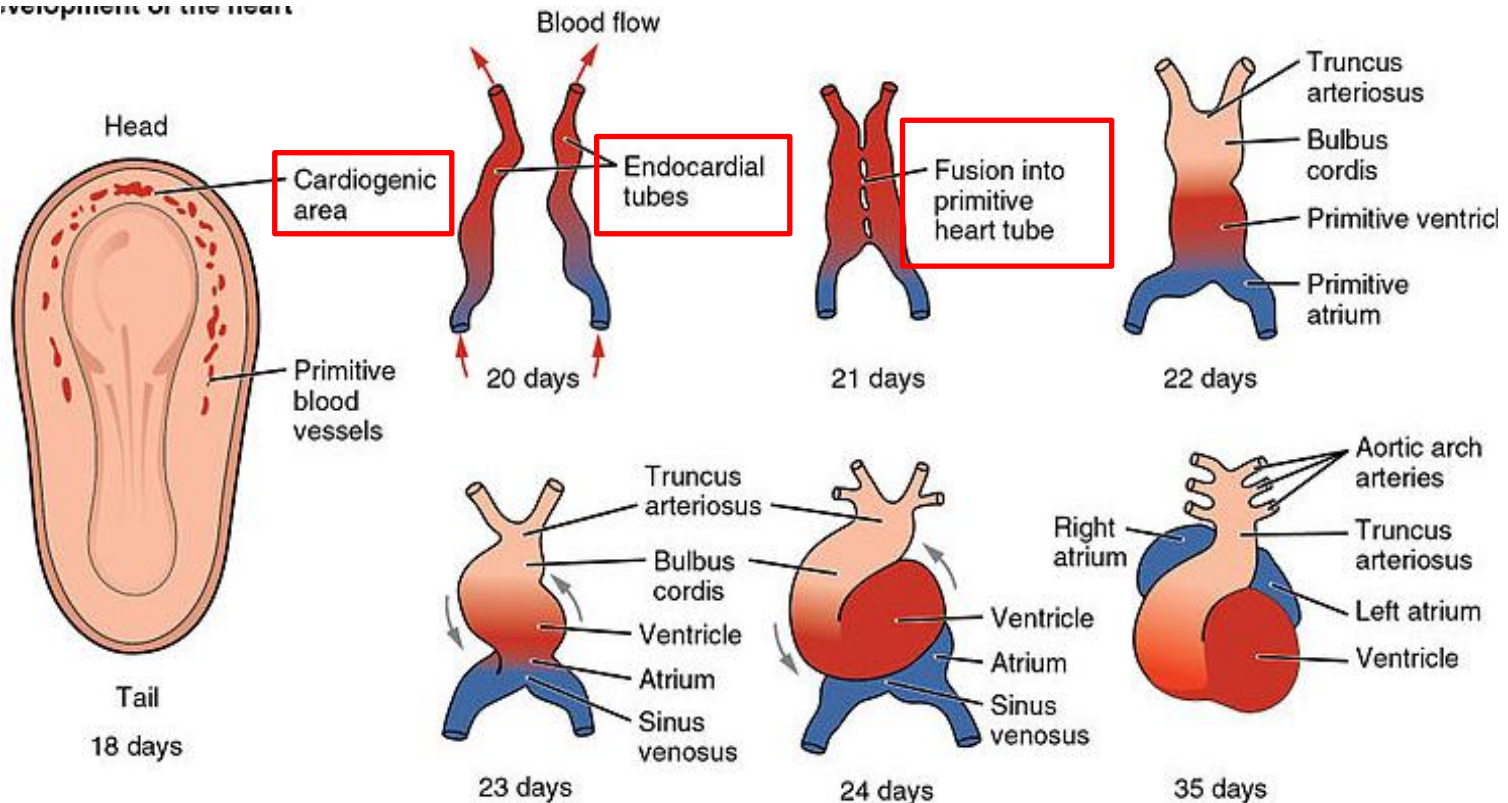


Figure 11.7 Ventral views of the developing cardiac tubes and coelom with corresponding cross-sections.

# FORMATION OF PRIMITIVE HEART TUBE

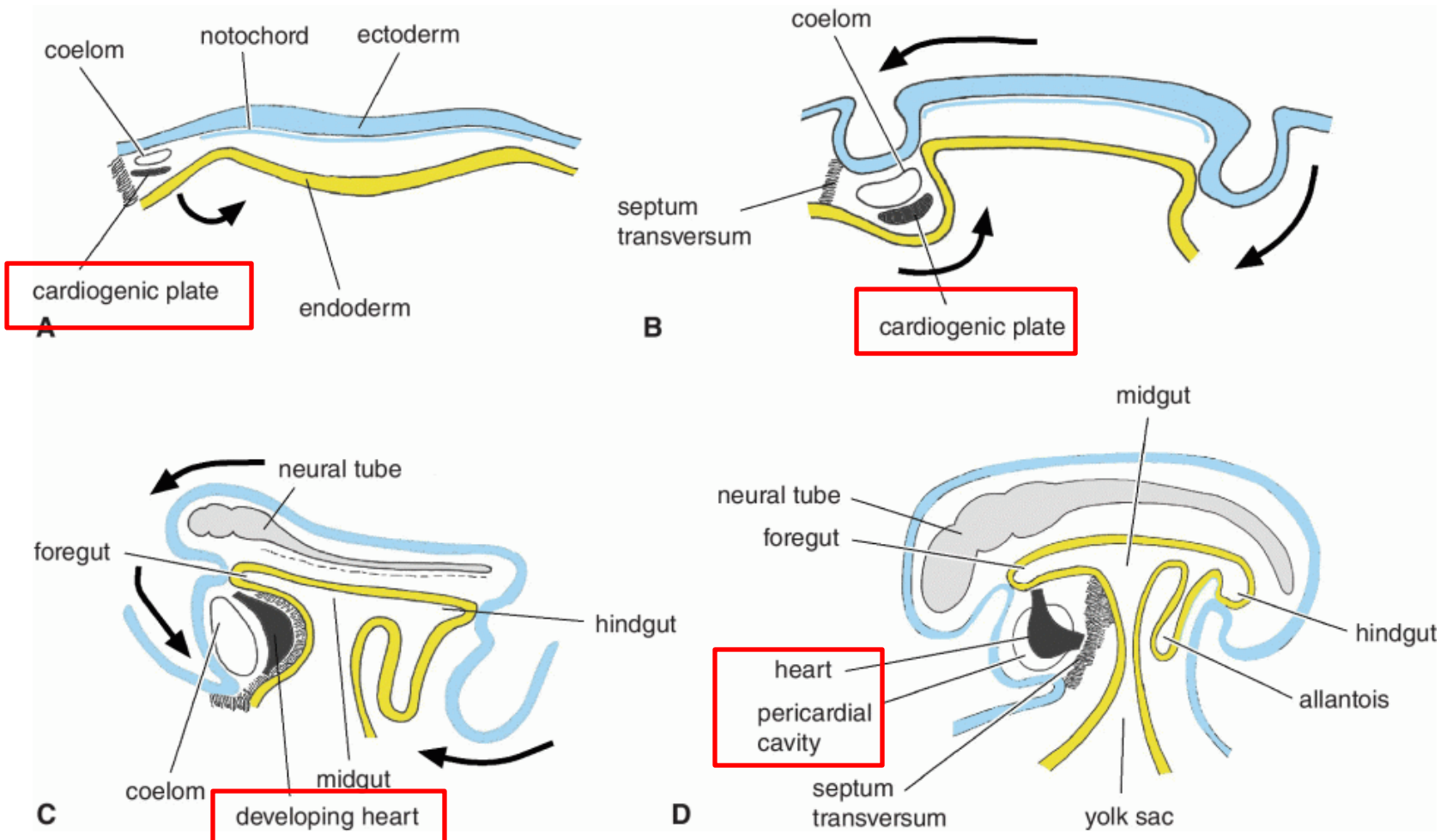
7. the paired tubes in the cardiogenic mesoderm form the primitive heart
8. the mesoderm surrounds the endothelial tubes and differentiates into the myocardium
9. the surrounding mesenchyme is the epimyocardium
10. the endothelial lining of the tubes constitutes the embryonic endocardium

Development of the heart



# FORMATION OF PRIMITIVE HEART TUBE

11. as the head of the embryo forms – the forming heart comes to lie ventral to the foregut



# FORMATION OF PRIMITIVE HEART TUBE

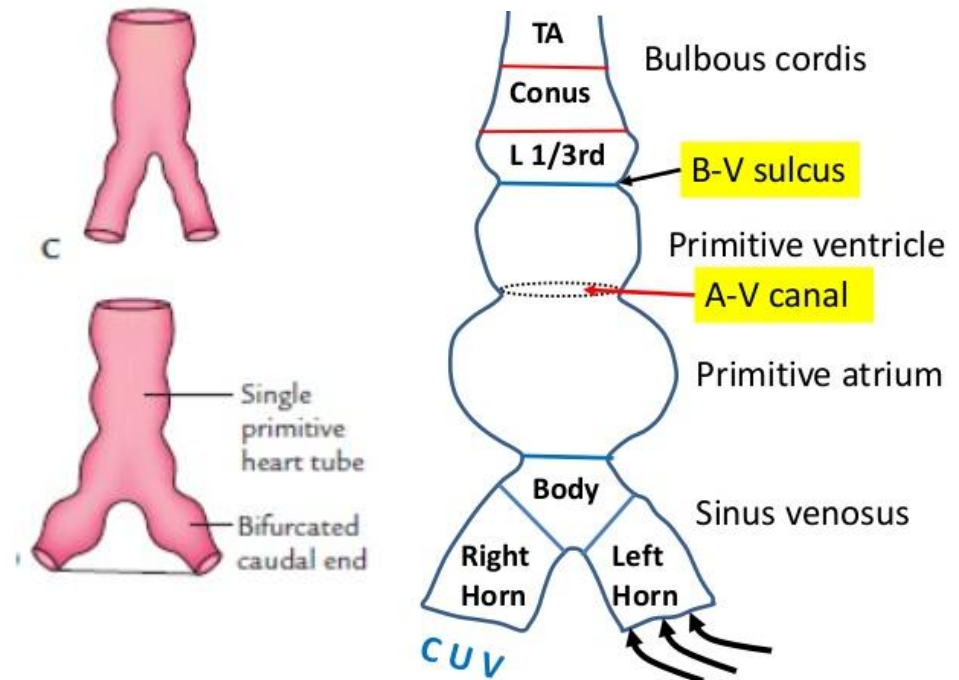
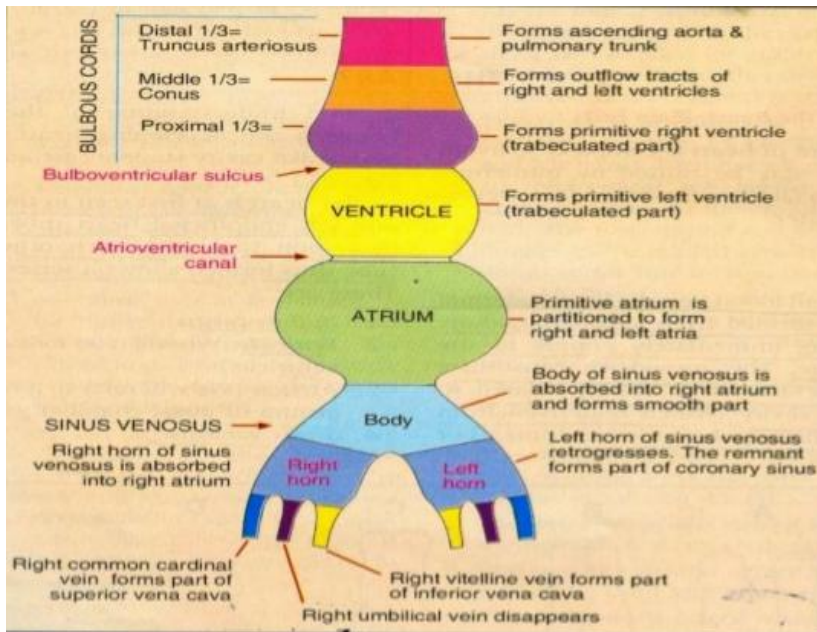
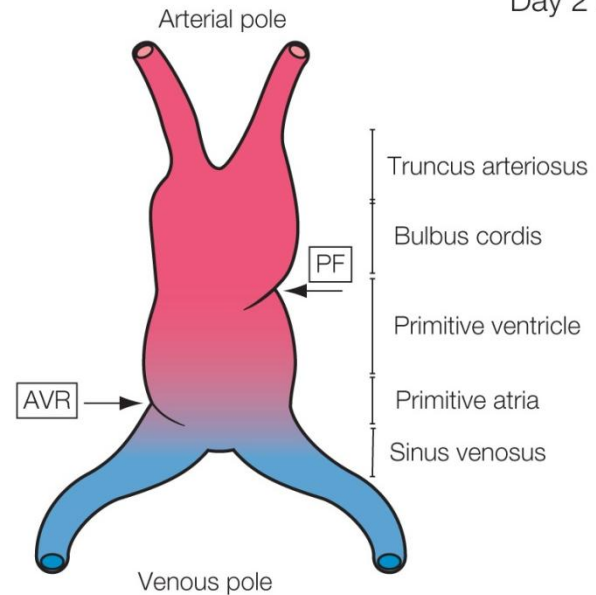
Day 21

## PARTS OF THE HEART TUBE cranial to caudal:

1. **truncus arteriosus**
2. **bulbus cordis**
3. **primitive ventricle**
4. **primitive atrium**
5. **sinus venosus**

the atrioventricular ring (AVR) forming the future atrioventricular valves and the primary fold (PF) forming the future interventricular septum.

<https://obgynkey.com/embryology-of-the-heart/>



<https://www.slideshare.net/RohitPaswan/development-of-heart-i>

# FORMATION OF PRIMITIVE HEART TUBE

- 12. the paired heart tubes begin to fuse with each other
- 13. the fusion begins at the area of the bulbus and ventricle
- 14. the fusion proceeds caudally to include the atrial area
- 15. the fusion of the heart tubes results in a single tube
- 16. the single heart tube is suspended from the top of the coelom by the dorsal mesocardium
- the mesocardium is a temporary structure and disappears within a short time

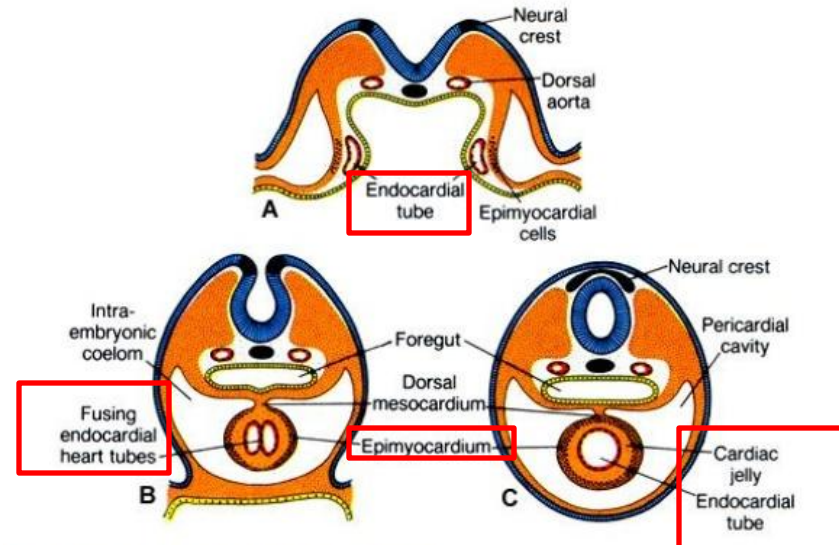
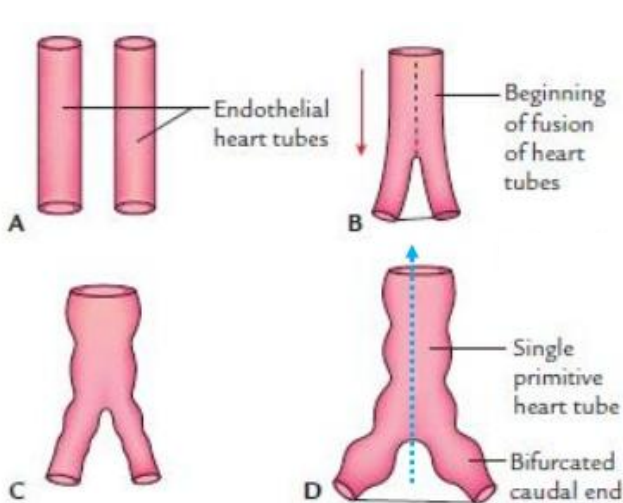
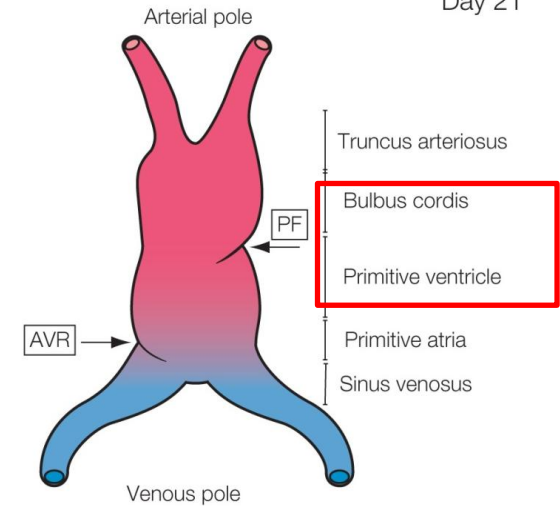


Fig. 18.2 Fusion of the endothelial heart tubes.

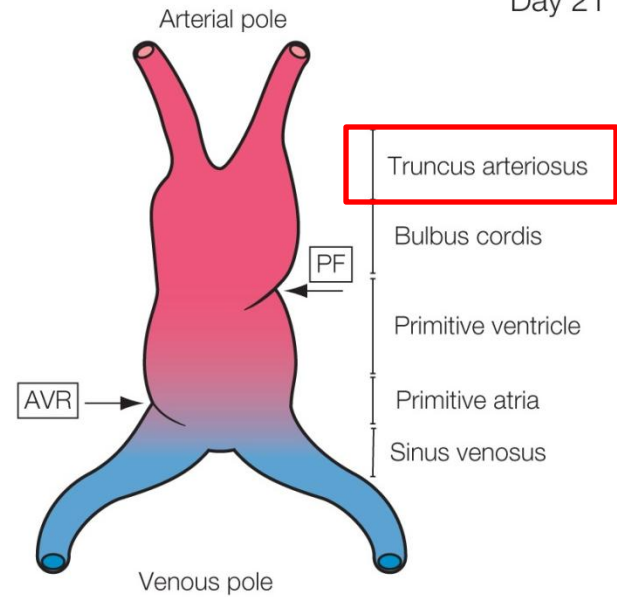
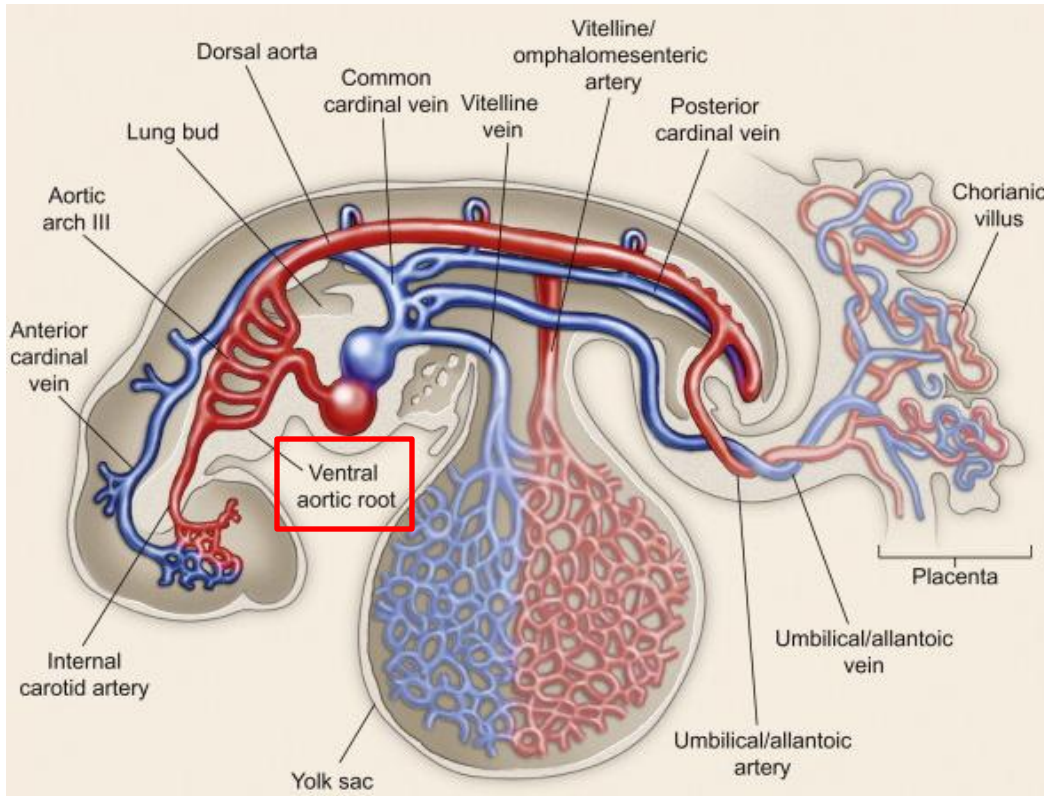
Fusion of heart tubes during lateral folding of embryo.

# PRIMITIVE FOUR CHAMBERED HEART

Day 21

## TRUNCUS ARTERIOSUS:

- considered to be a part of the atrial system
- communicates cranially with the ventral aorta

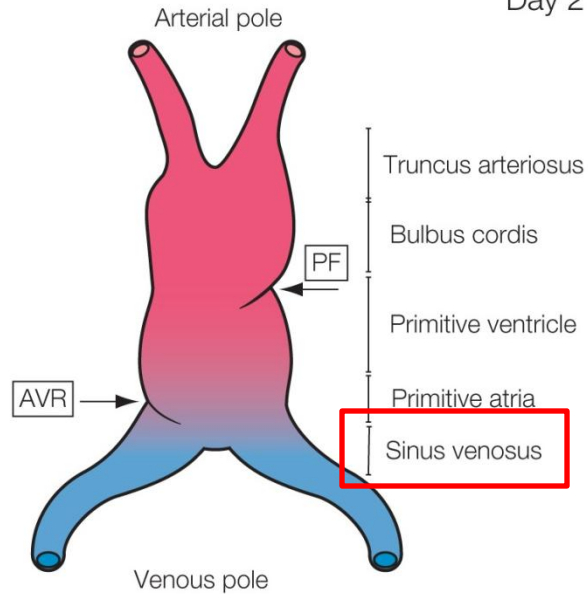


# PRIMITIVE FOUR CHAMBERED HEART

## SINUS VENOSUS:

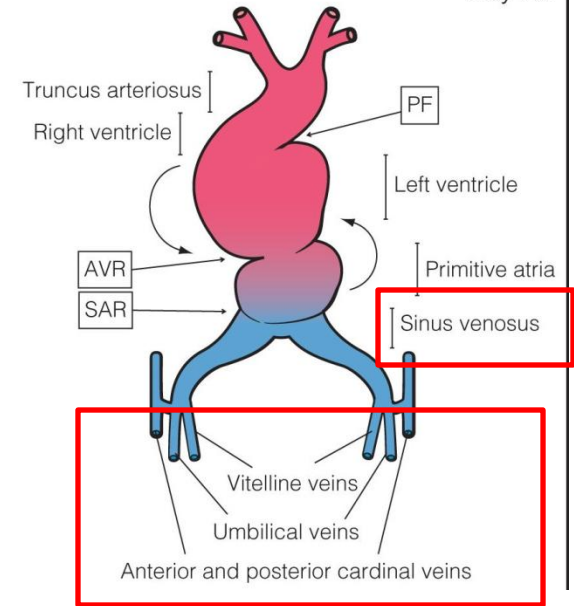
### receives:

- caudally the vitelline veins
- the cardinal veins
- the umbilical veins

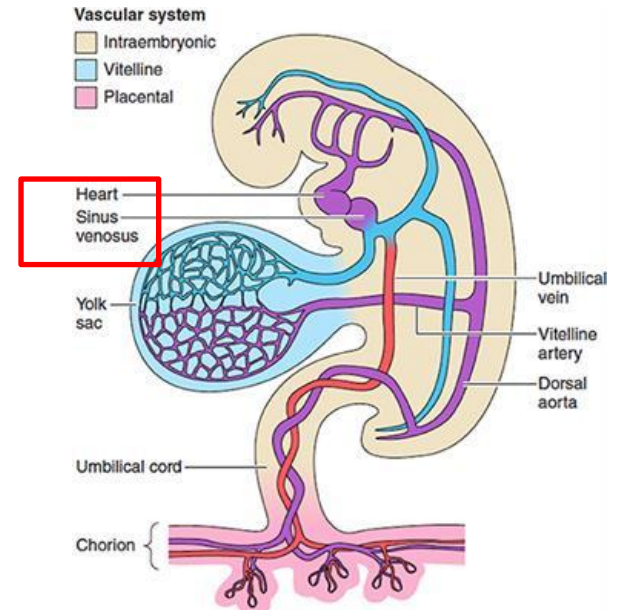
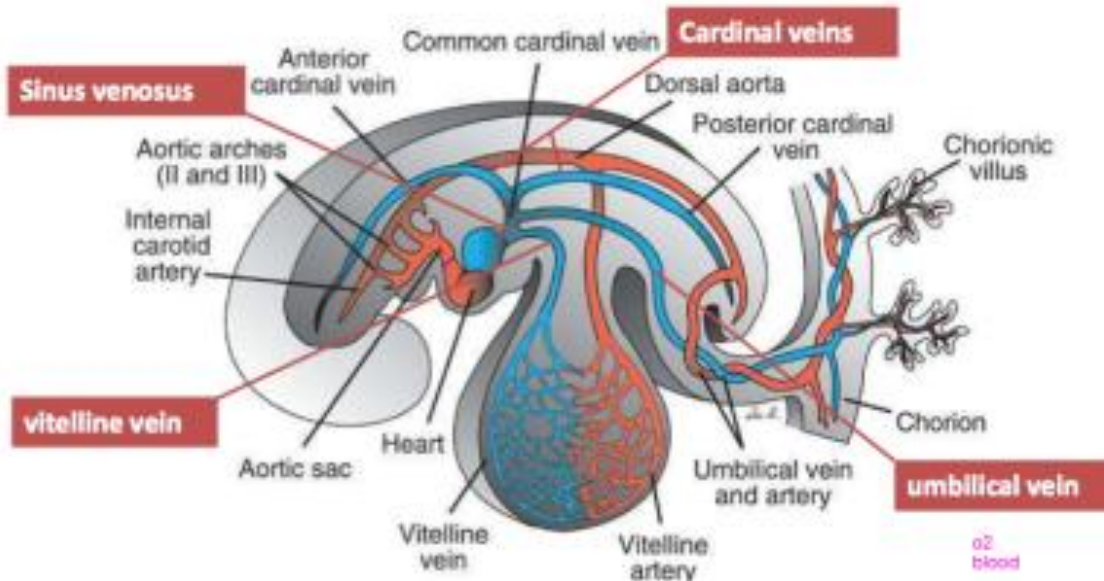


Day 21

Day 23

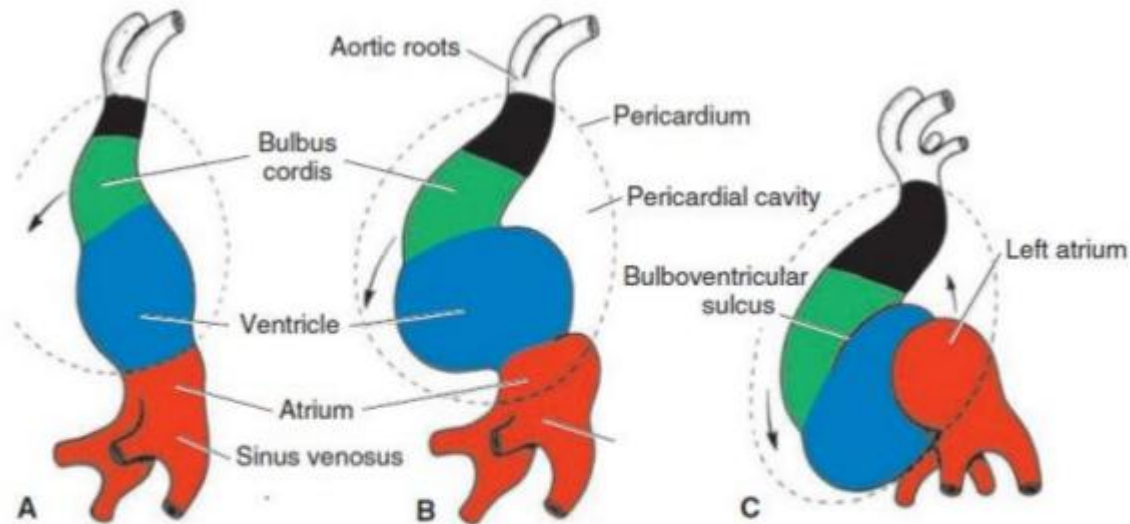


<https://obgynkey.com/embryology-of-the-heart/>



# PRIMITIVE FOUR CHAMBERED HEART

- the heart tube undergo a series of growth and position changes
- this changes transform the simple heart tube into structures – that has the basic relationships of the adult heart



**Cardiac looping:** *cephalic portion* bends **ventrally, caudally and toward right side**. Caudal end loops in exactly opposite direction.

- From day 23 to 28

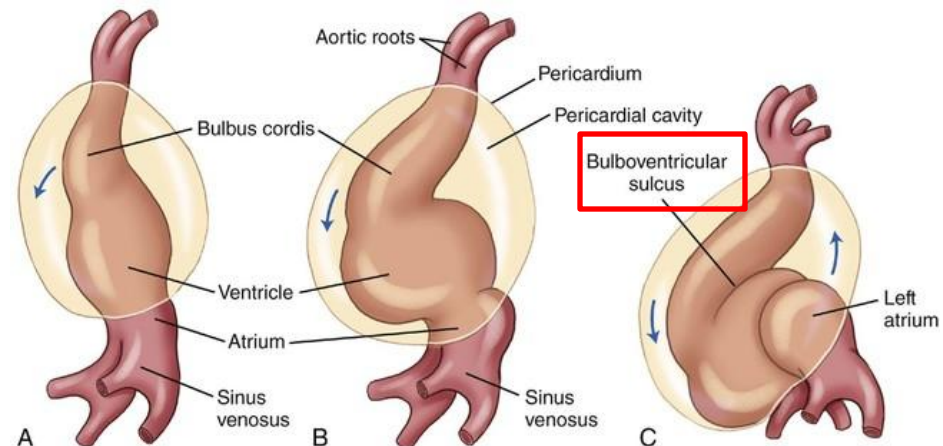
# PRIMITIVE FOUR CHAMBERED HEART

## FIRST CHANGE OF THE SIMPLE HEART TUBE:

### 1. involves the formation of the bulboventricular loop

## BULBOVENTRICULAR LOOP:

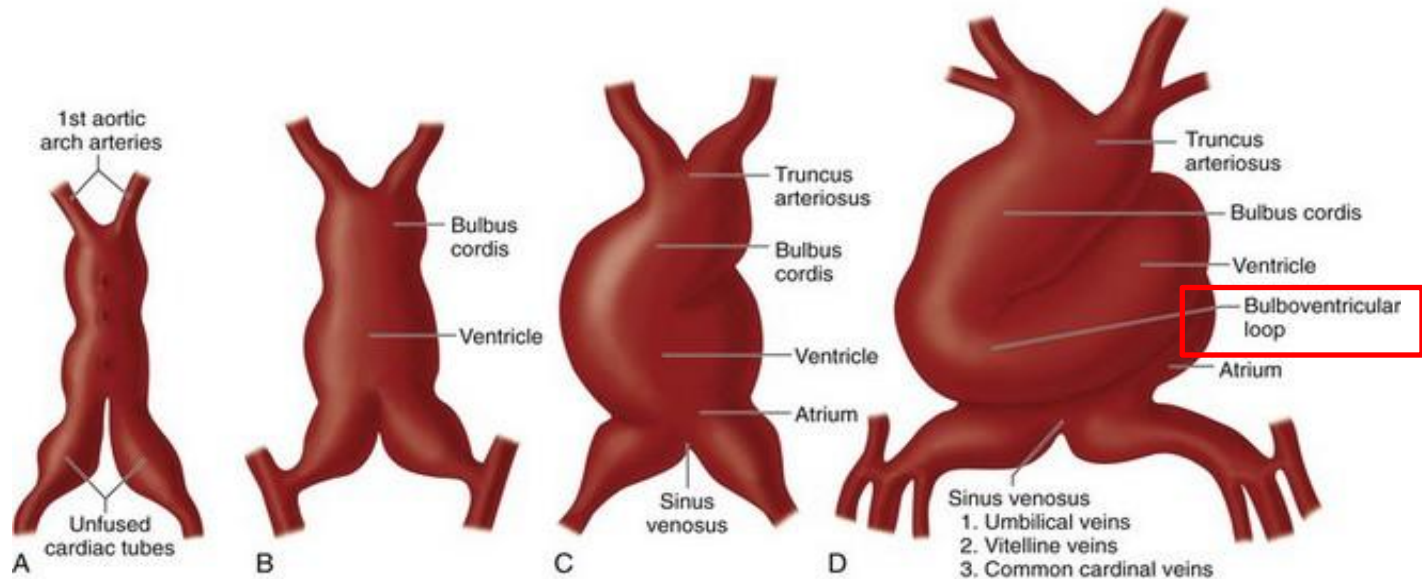
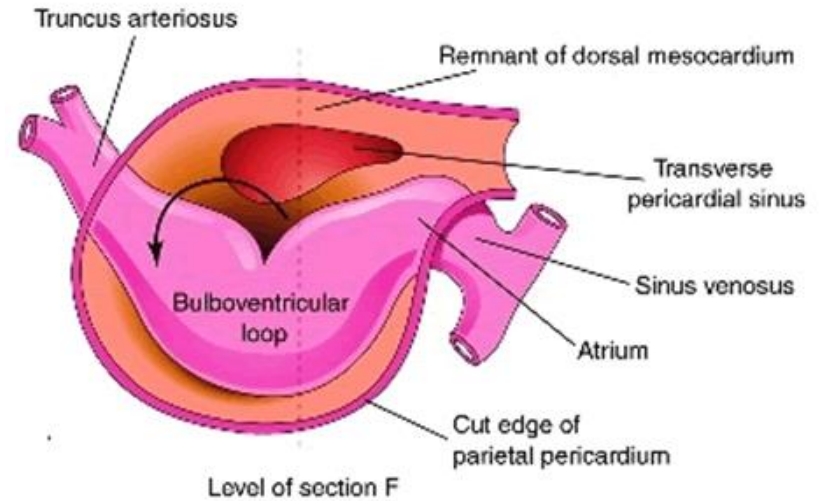
- formed in that part of the endothelial tube that comprises the bulbus and the primitive ventricle
- a. the closed end of the loop directed to the right and ventrally
- b. the truncus and the sinoatrial areas remain near the midline – they are attached to the developing aortic arch and venous system
- c. the cranial part of the loop is the bulbus cordis
- d. the caudal part of the loop is the primitive ventricle



# PRIMITIVE FOUR CHAMBERED HEART

FIRST CHANGE OF THE SIMPLE HEART TUBE:

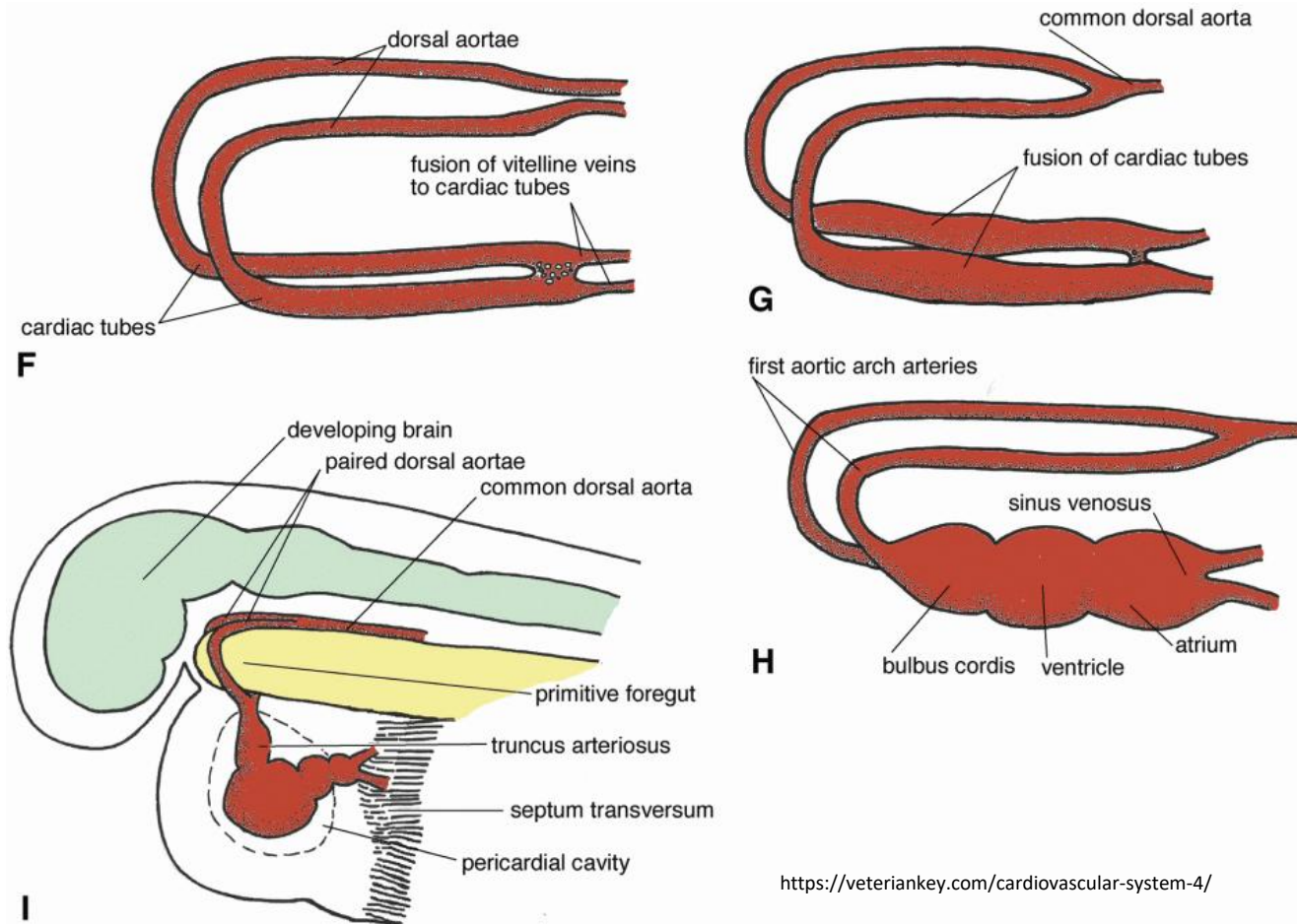
BULBOVENTRICULAR LOOP:



# PRIMITIVE FOUR CHAMBERED HEART

## CHANGE OF THE SIMPLE HEART TUBE:

- the heart in the shape of a spiraled „S”



# PRIMITIVE FOUR CHAMBERED HEART

## CHANGE OF THE SIMPLE HEART TUBE:

2. the bulbus and ventricular areas expand - by means of divetriculation
3. the atrial area expands also

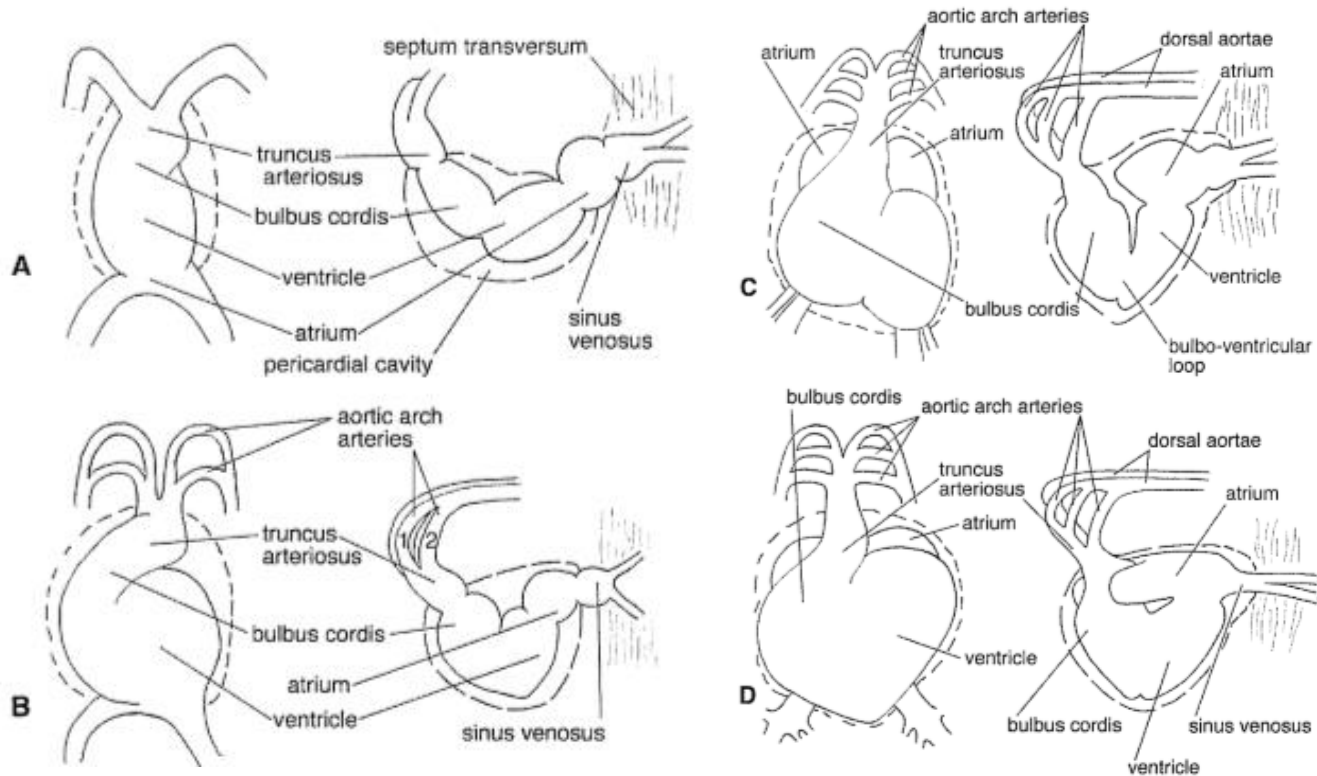


Figure 11.8 Dorso-ventral and left lateral views of sequential stages in the differentiation of the cardiac tube, from the bulbo-ventricular loop stage to the expansion of the bulbo-ventricular loop ventrally, and the common atrium dorsally.

# PRIMITIVE FOUR CHAMBERED HEART

## CHANGE OF THE SIMPLE HEART TUBE EXTERNALLY:

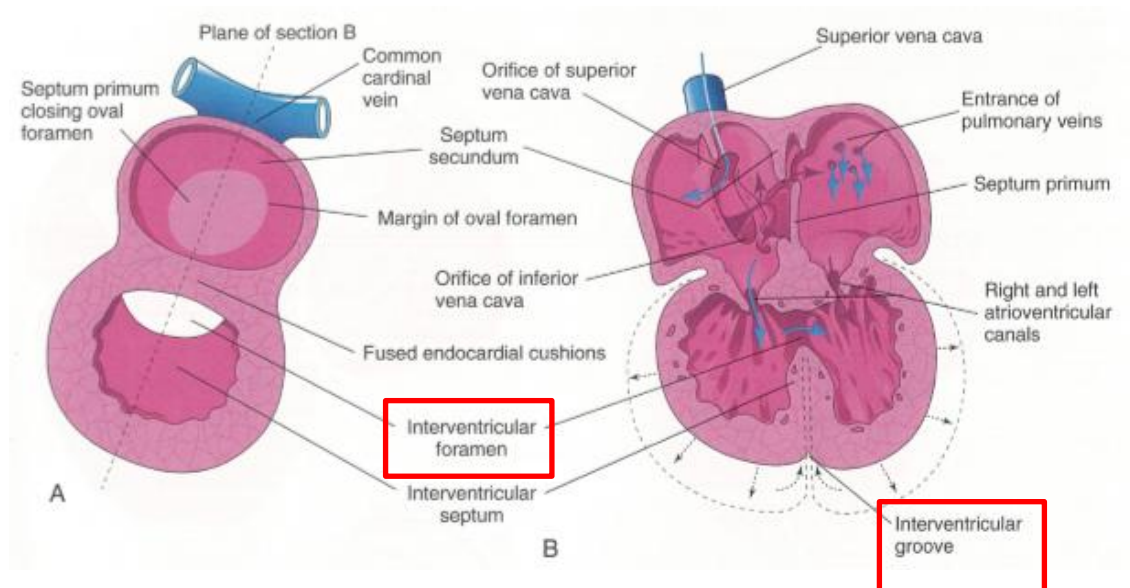
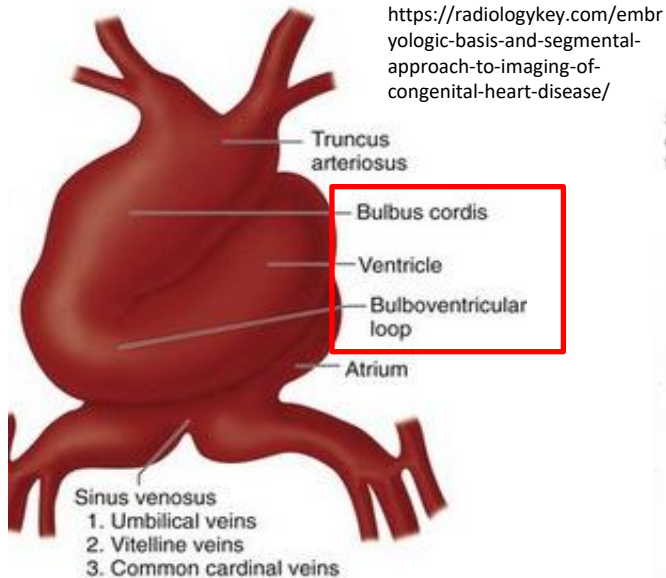
- there are sulci in the developing epimyocardium

a. interventricular sulcus – demarcating the constriction in the bulboventricular loop

b. internally the constricted part of the tube is the primarily interventricular foramen

c. antioventricular sulcus – the sulcus at the atrioventricular boundary

d. the corresponding constriction in the heart tube transformed into the atrioventricular ostia in the adult



# POSITIONING AND INTERNAL STRUCTURE

- after the „S” – shaped loop is formed the heart undergoes further changes in position

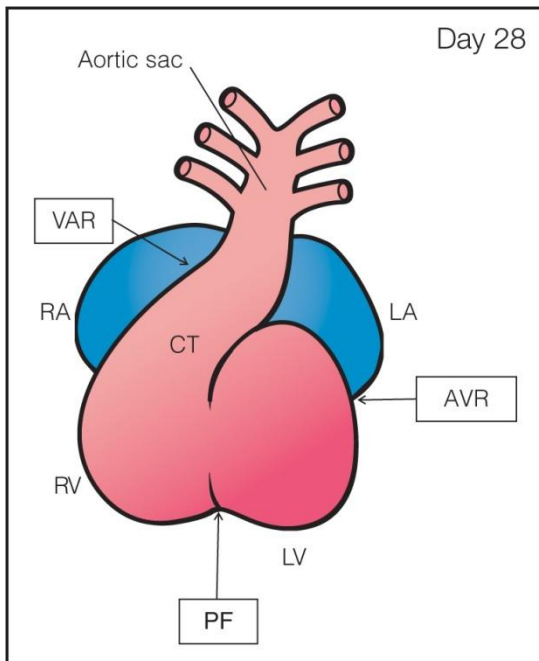
a. the bulbus shifts to more ventral and caudal position

b. the atrium and the sinus venosus move more cranial

## THE RESULT:

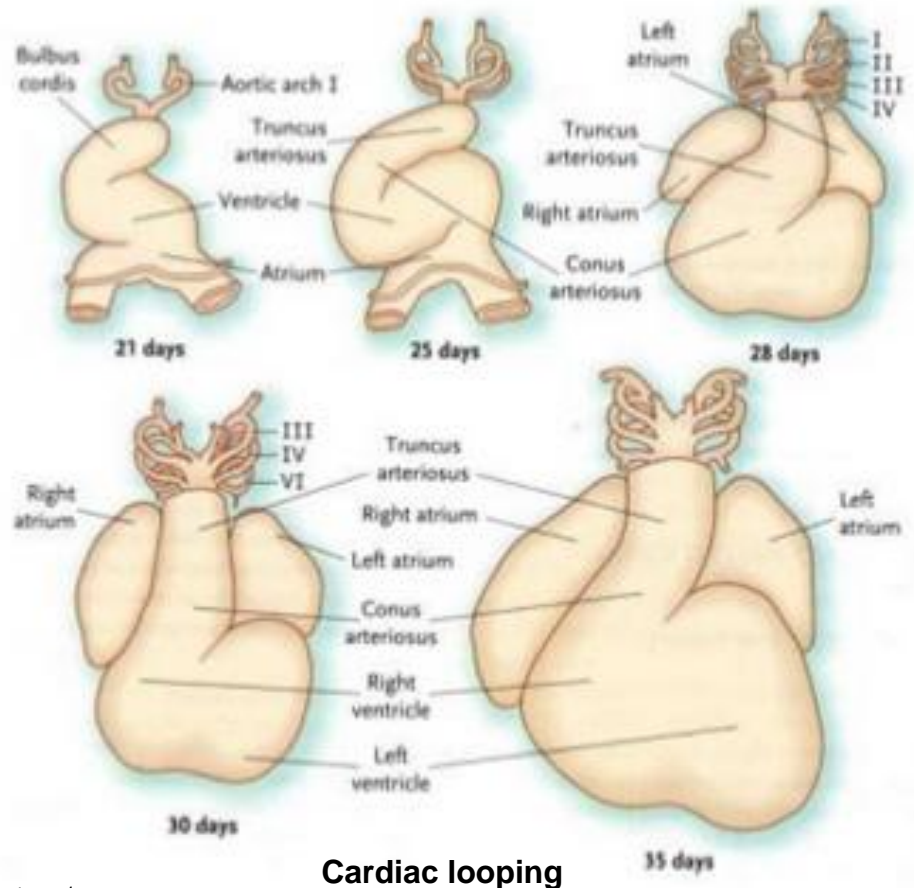
- the atrium is dorsal to the bulbus and ventricle

- the sinus venosus is dorsal to the atrium



the atrioventricular ring (AVR) between the common atrium and common ventricle, the primary fold (PF) between the primitive left (LV) and right (RV) ventricles, and the ventriculoarterial ring (VAR) in the conotruncus (CT) region of the outflow tract of the heart. At this stage, the septation of atria, ventricles, and great vessels occurs. RA, right atrium; LA, left atrium.

<https://obgynkey.com/embryology-of-the-heart/>

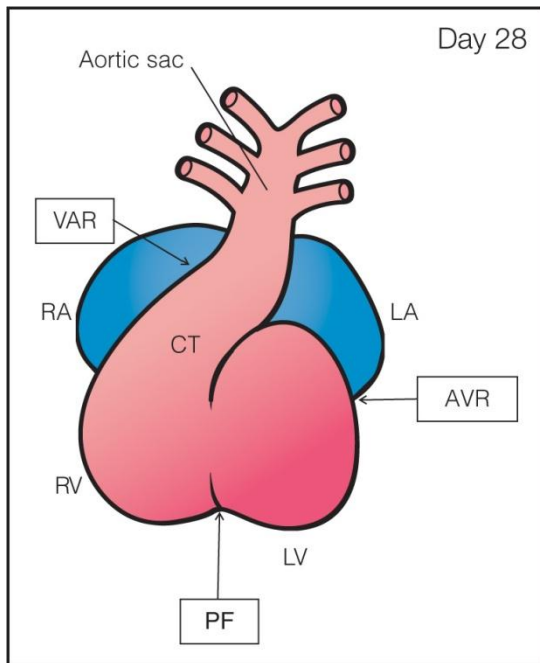


# POSITIONING AND INTERNAL STRUCTURE

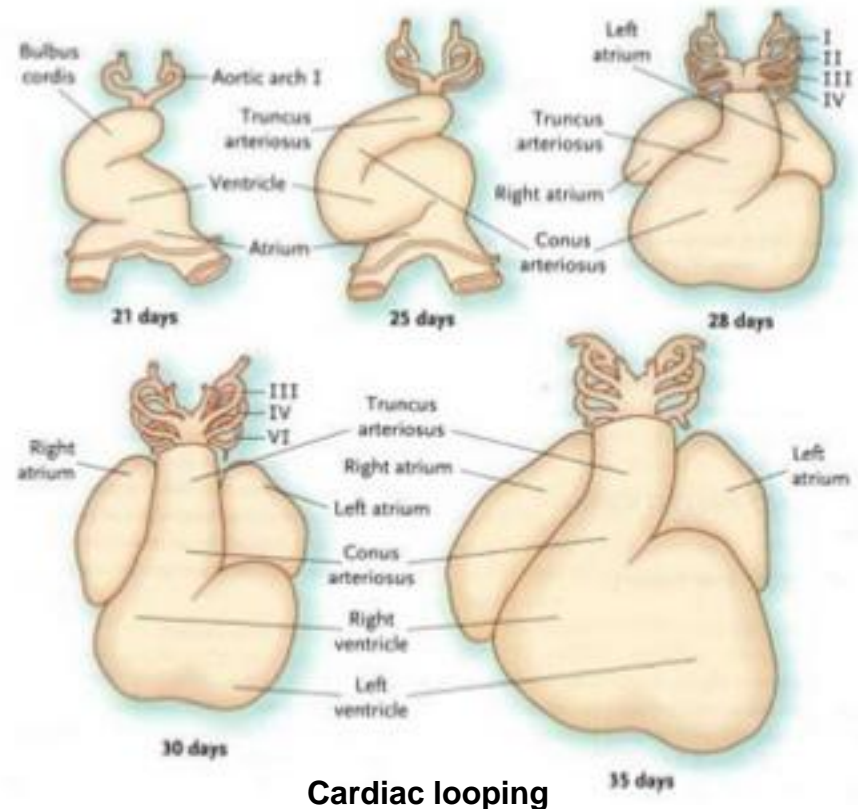
c. the cardiac loop shifts caudally, and moves toward the left

d. the caudal limb (future the left ventricle) and the cranial limb (bulk of the right ventricle) of the loop lie parallel to each other in the left caudal and right cranial positions

e. during the position changes the atrium rapidly dilates and assumes a bilobed appearance



the atrioventricular ring (AVR) between the common atrium and common ventricle, the primary fold (PF) between the primitive left (LV) and right (RV) ventricles, and the ventriculoarterial ring (VAR) in the conotruncus (CT) region of the outflow tract of the heart. At this stage, the septation of atria, ventricles, and great vessels occurs. RA, right atrium; LA, left atrium.



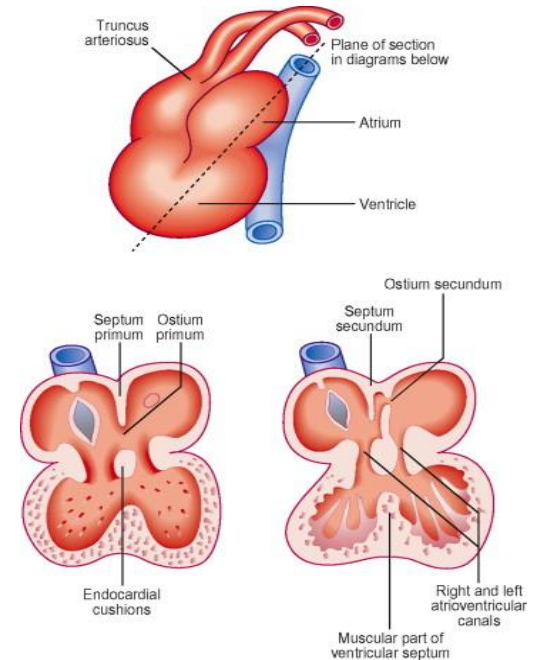
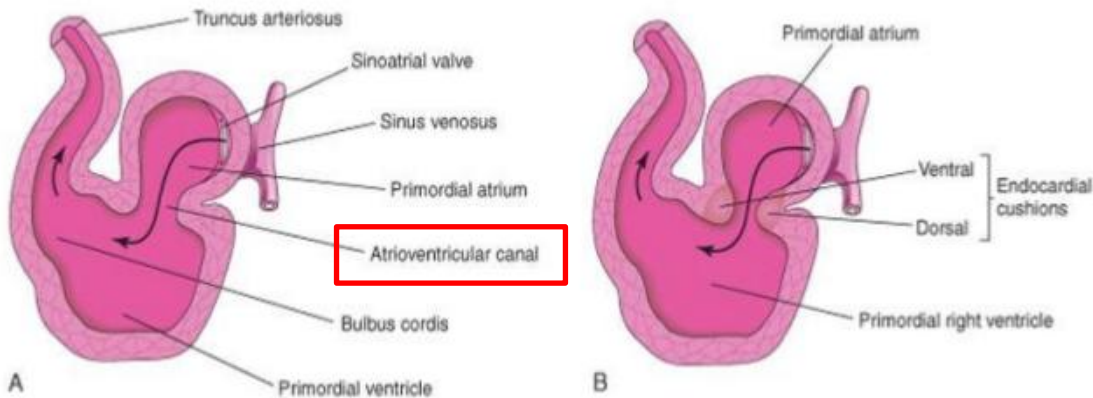
# POSITIONING AND INTERNAL STRUCTURE

## THE INTERNAL PARTITIONING:

- occur simultaneously

include:

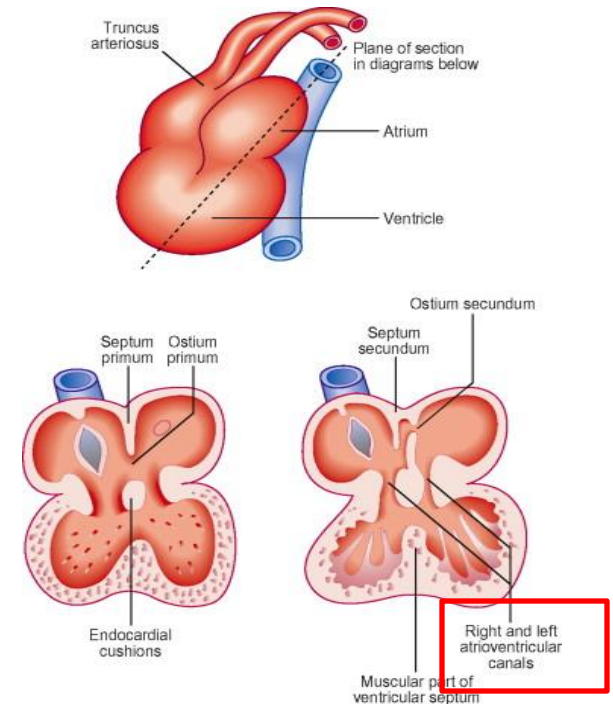
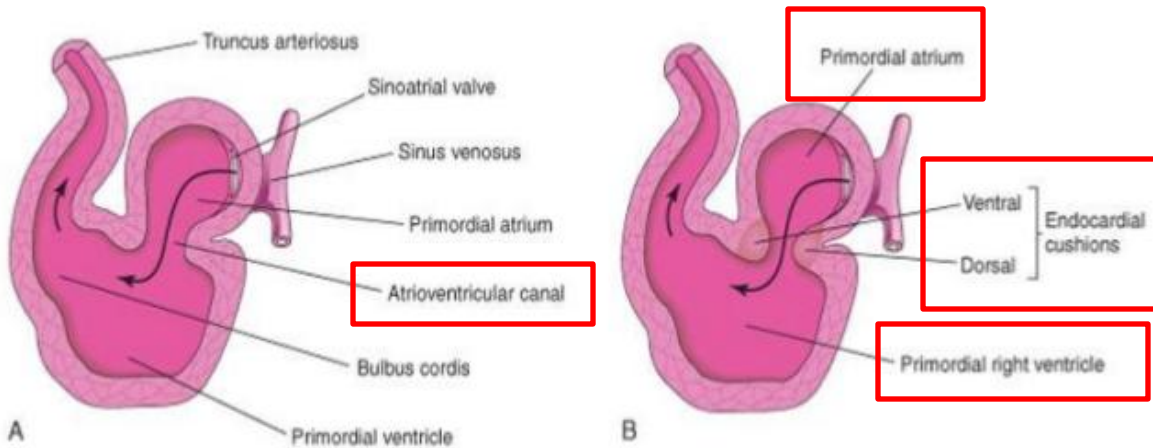
- separation of the primitive atrioventricular ostium into right and left atrioventricular ostia
- formation of the interatrial septum – separating the primitive atrium into right and left atria
- formation of the intraventricular septum – divides the bulboventricular area into right and left ventricles
- partitioning of the truncus arteriosus into aorta and pulmonary trunk



# POSITIONING AND INTERNAL STRUCTURE

## PARTITIONING OF THE ATROVENTRICULAR OSTIA:

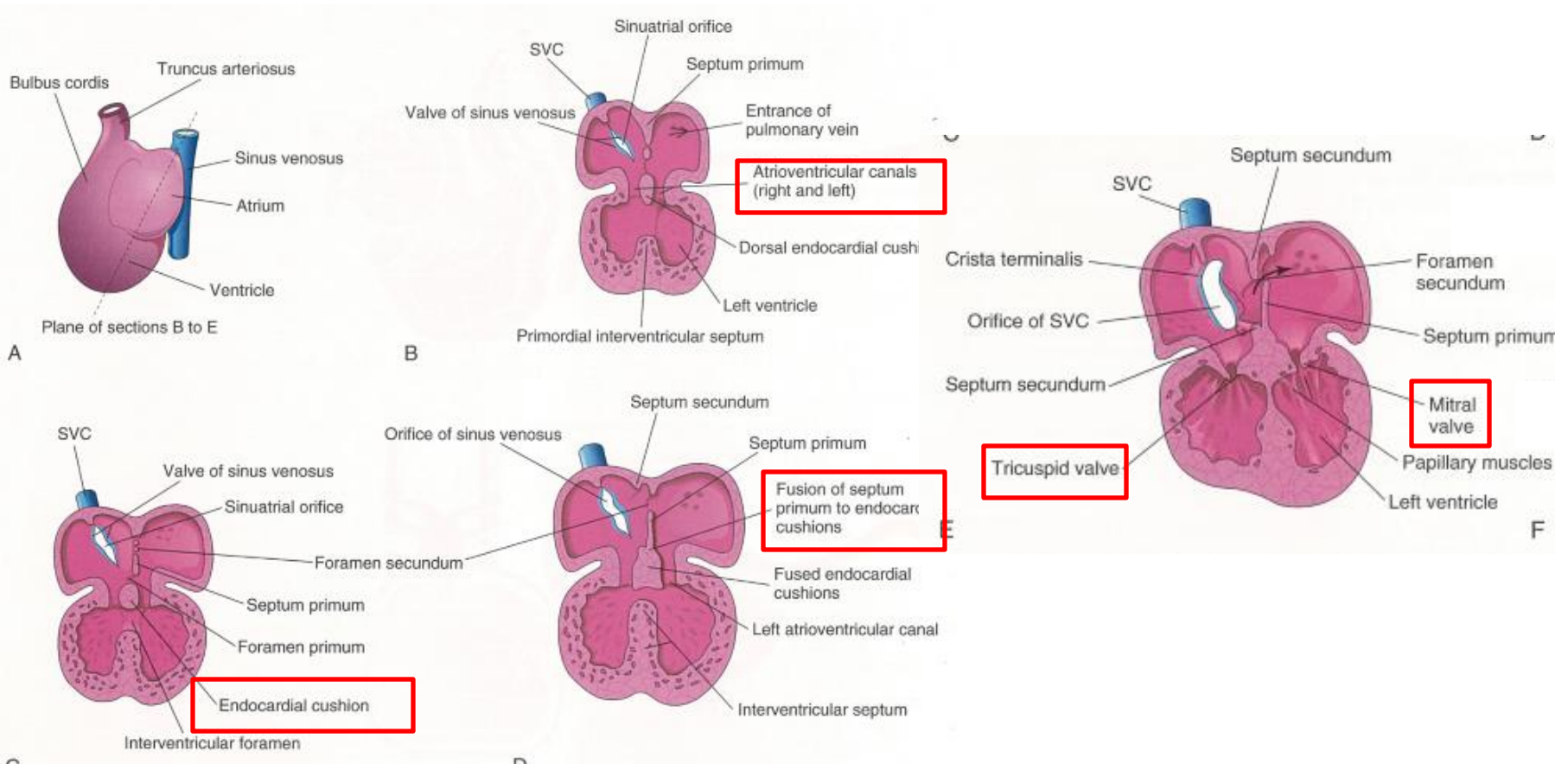
- because of the ventro – caudal shift of the bulboventricular loop, the narrow communication between the atrium and the primitive ventricle lies a vertical position
- endocardial thickenings appear on the dorsal and ventral edges of the primitive atrioventricular ostium
- the endocardial thickening are the forerunners of the atrioventricular endocardial cushions (endocardial swellings)



# POSITIONING AND INTERNAL STRUCTURE

## PARTITIONING OF THE ATROVENTRICULAR OSTIA:

- d. the endocardial cushions enlarge - than they fuse with one another to separate the primitive canal into right and the left atrioventricular ostia



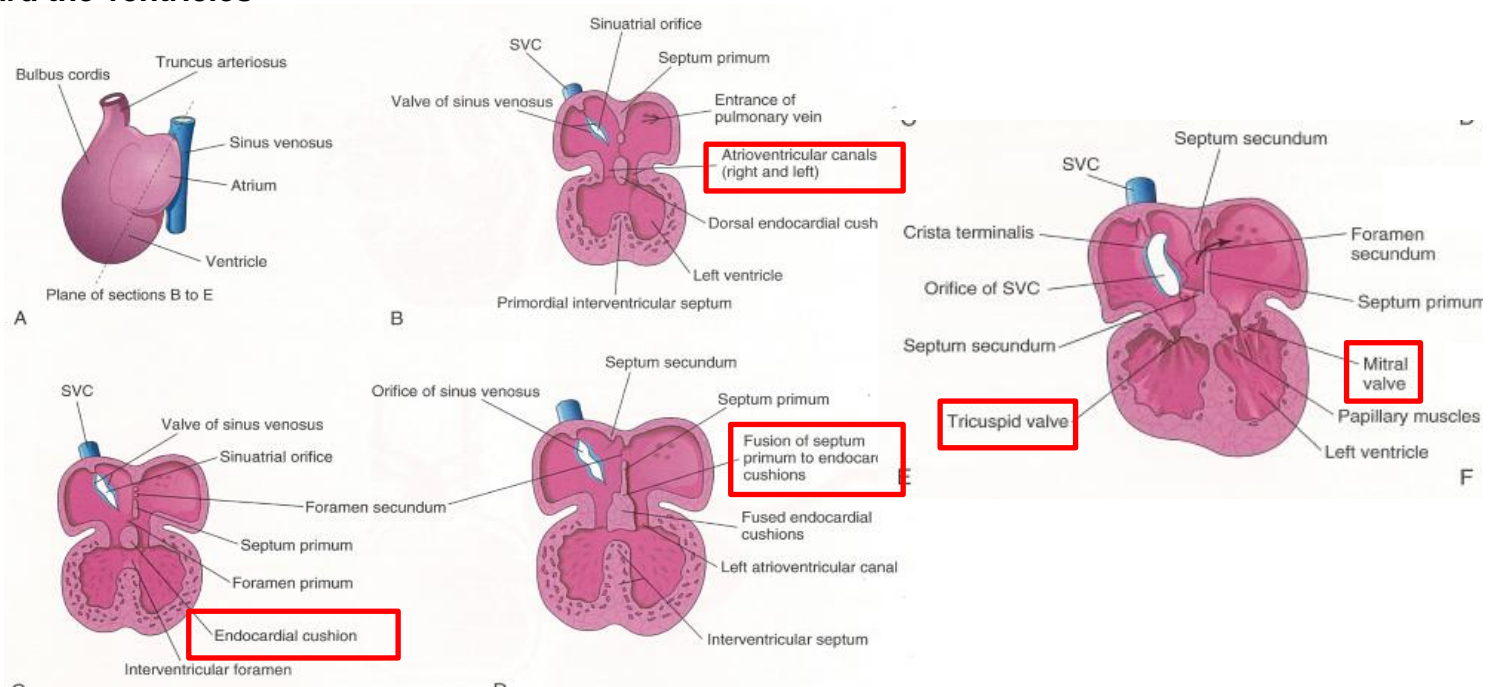
# POSITIONING AND INTERNAL STRUCTURE

## PARTITIONING OF THE ATROVENTRICULAR OSTIA:

e. lateral endocardial cushions seen on the lateral edges of the atrioventricular ostia

they from:

1. an arch toward the atria – this arch contributes to the closure of the interatrial communication, formation of the interatrial septum
2. an arch toward the ventricles



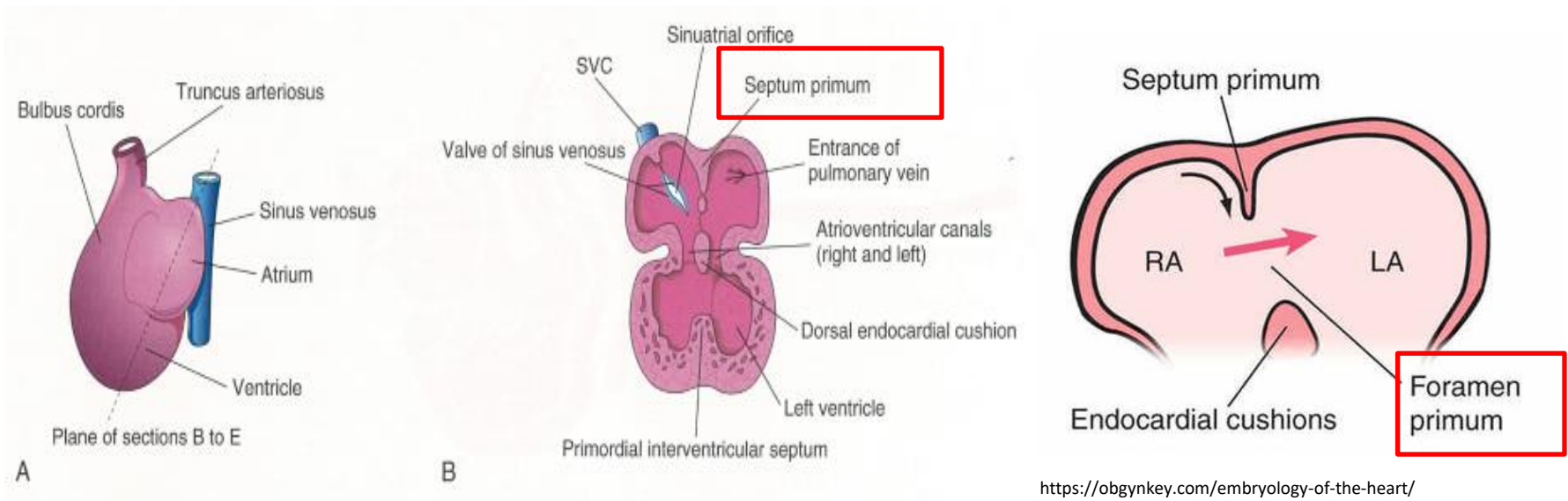
# POSITIONING AND INTERNAL STRUCTURE

## PARTITIONING OF THE ATRIA:

- separation of the primitive atrium into the right and left atria involves several steps

## FIRST STEP:

1. the first is the formation of a membrane that originates from the cranial wall of the atrium
2. the membrane referred to as the primary interatrial septum (septum primum)
3. the circular opening in the membrane is the primary interatrial foramen (foramen primum)

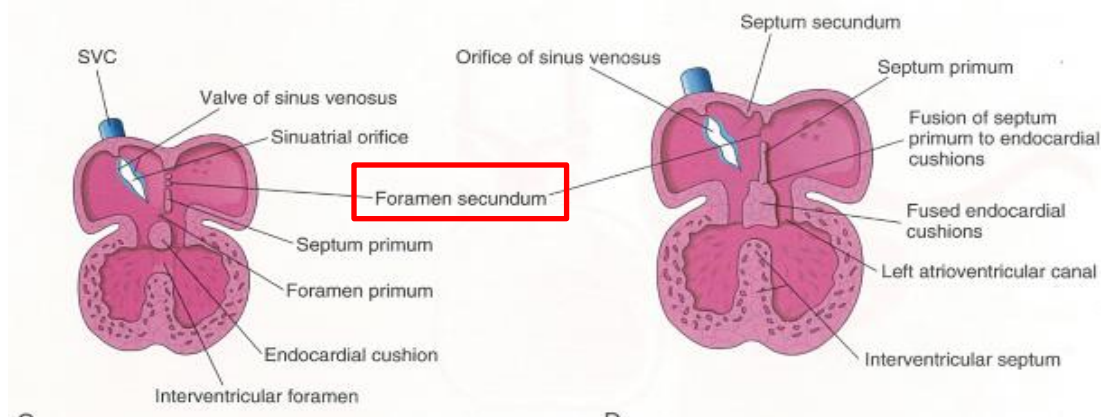


# POSITIONING AND INTERNAL STRUCTURE

## PARTITIONING OF THE ATRIA:

### SEPTUM PRIMUM:

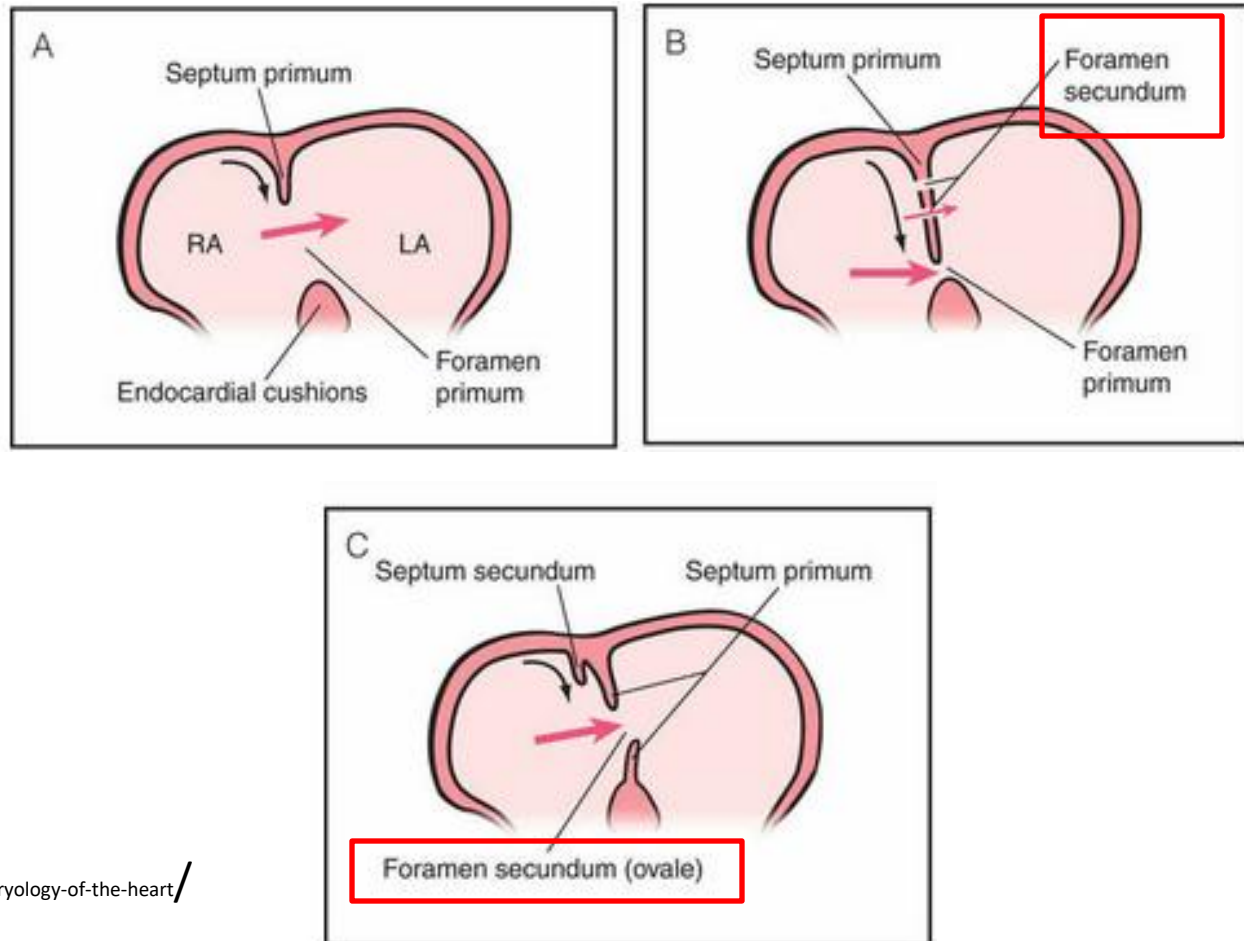
- a. the edges of the septum primum grow toward the atrioventricular opening
- b. the foramen primum diminishes in size
- c. the septum primum joins the dorsal and ventral endocardial cushions – and fuses with the apex of the arched portion of the endocardial cushions – this completely obliterates the foramen primum
- d. before the obliteration of the foramen primum – one secondary opening forms in the cranial part of the septum primum – this opening coalesces to form the secondary interatrial foramen (foramen secundum)



# POSITIONING AND INTERNAL STRUCTURE

PARTITIONING OF THE ATRIA:

FORAMEN SECUNDUM :

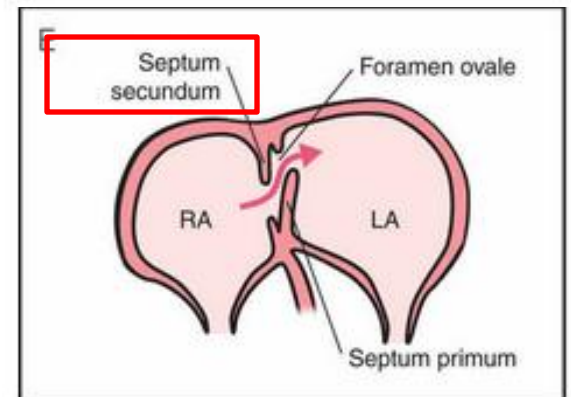
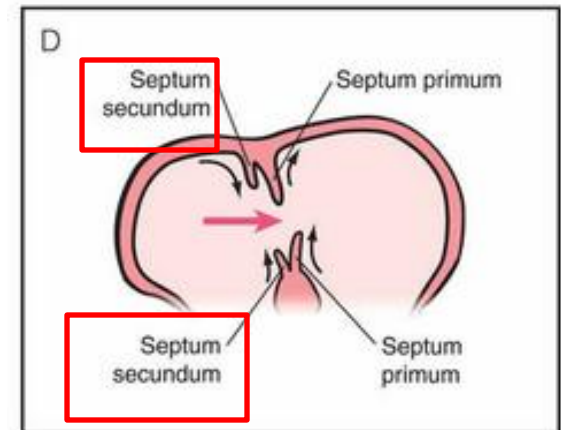
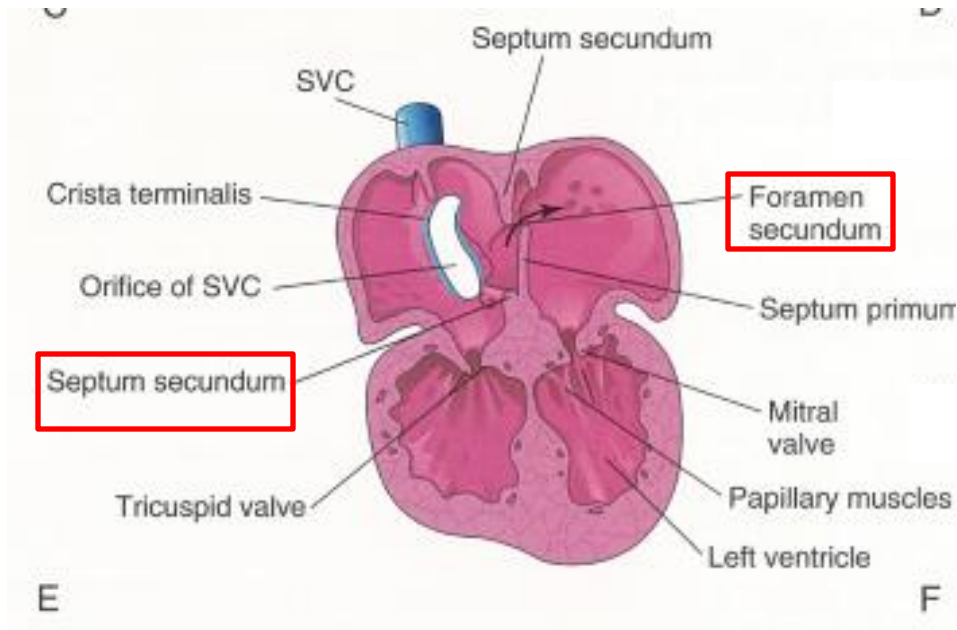


# POSITIONING AND INTERNAL STRUCTURE

## PARTITIONING OF THE ATRIA:

### SECOND STEP:

- the formation of the second membrane – secondary interatrial septum (septum secundum)



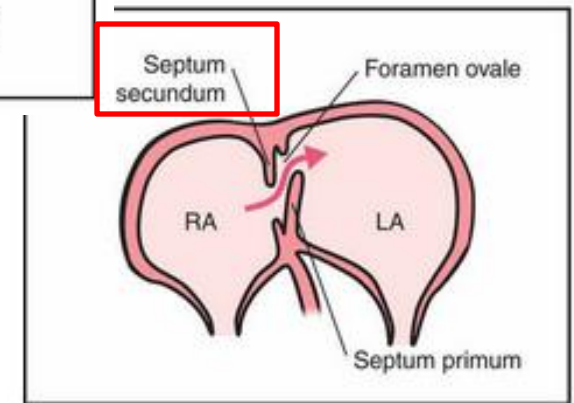
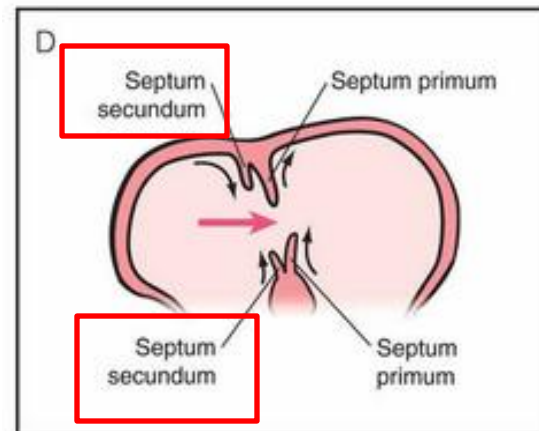
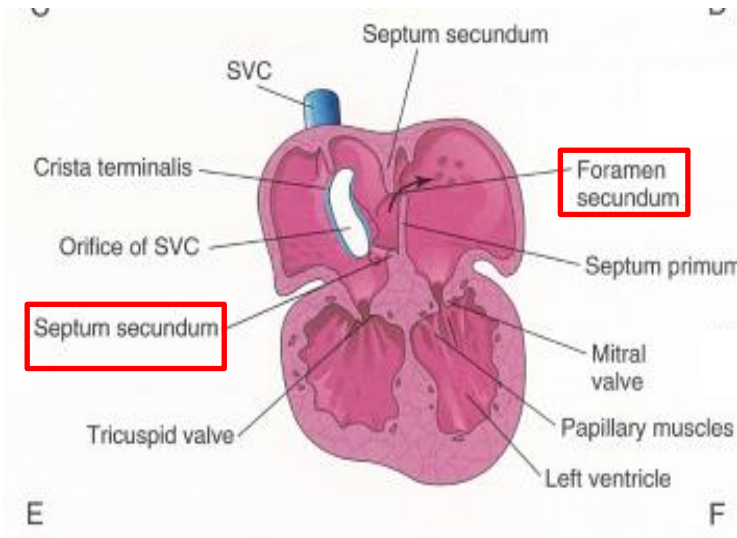
# POSITIONING AND INTERNAL STRUCTURE

## PARTITIONING OF THE ATRIA:

### SEPTUM SECUNDUM:

originates from:

- the muscular ridge on the dorsalcranial wall of the atrium to the right of the primary septum
- the ridge on the atrial surface of the fused endocardial cushions right of the primary septum



# POSITIONING AND INTERNAL STRUCTURE

## PARTITIONING OF THE ATRIA:

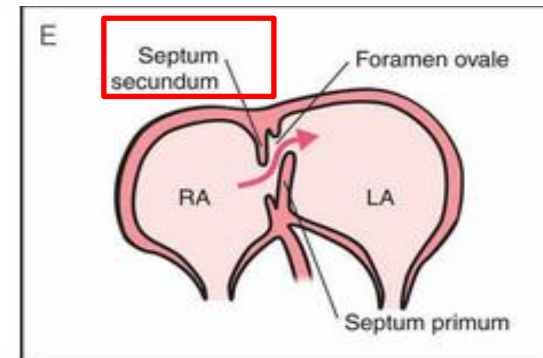
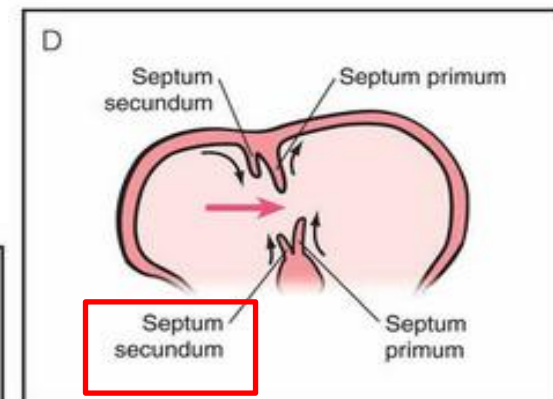
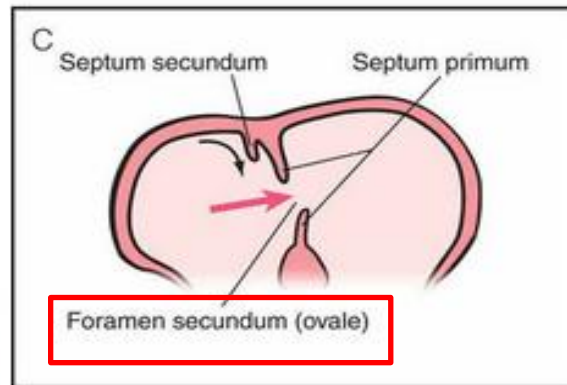
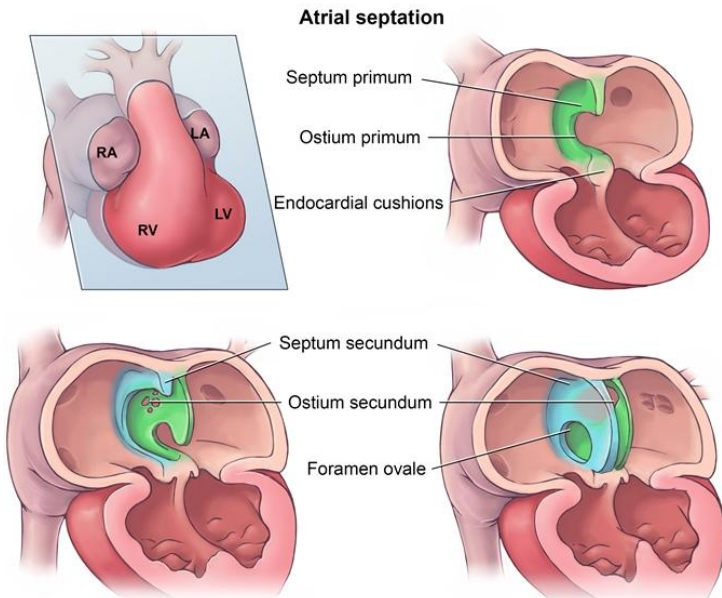
### SEPTUM SECUNDUM:

d. the septum secundum extends ventrally from the dorsal wall of the atrium to the right of the septum primum

e. the septum secundum is notched – the notch is called the foramen ovale

f. the cranial part of the septum secundum covers the foramen secundum

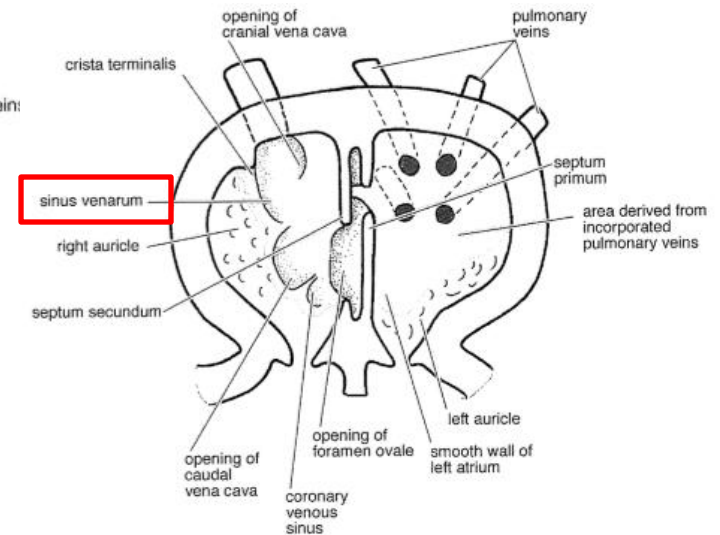
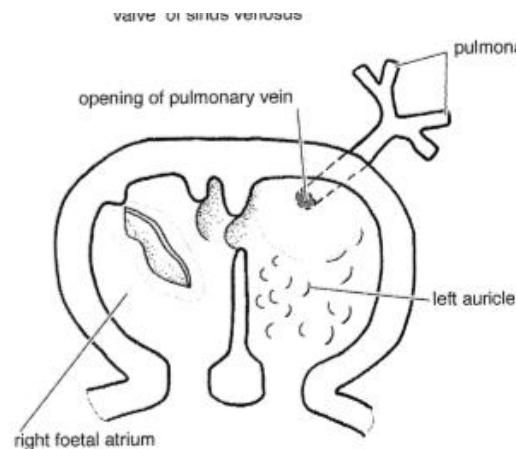
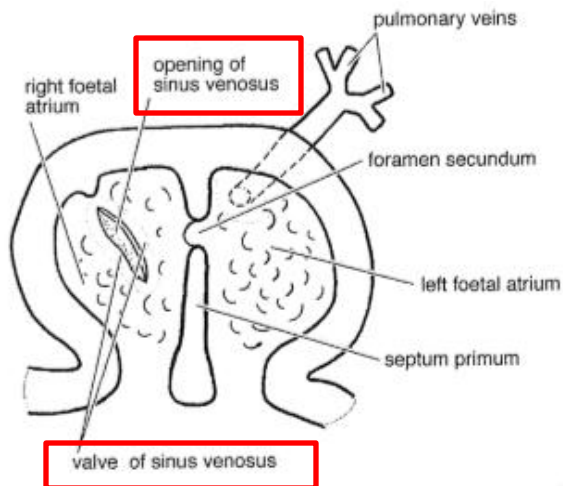
- the blood flows from the right atrium to the left one via the foramen ovale



# POSITIONING AND INTERNAL STRUCTURE

## SINUS VENOSUS AND RIGHT ATRIUM:

- related to the formation of the interatrial septum
- a. the valves , which surround the sinoatrial opening – formed by a folding of the margins of the opening
- b. these folds are the valves of the sinus venosus
- c. these folds form two ridges on the inner surface of the dorso – caudal wall of the right atrium
- d. the right and the left ridges are the right and the left valves of the sinus venosus
- e. the opening between the ridges is the sinoatrial orifice

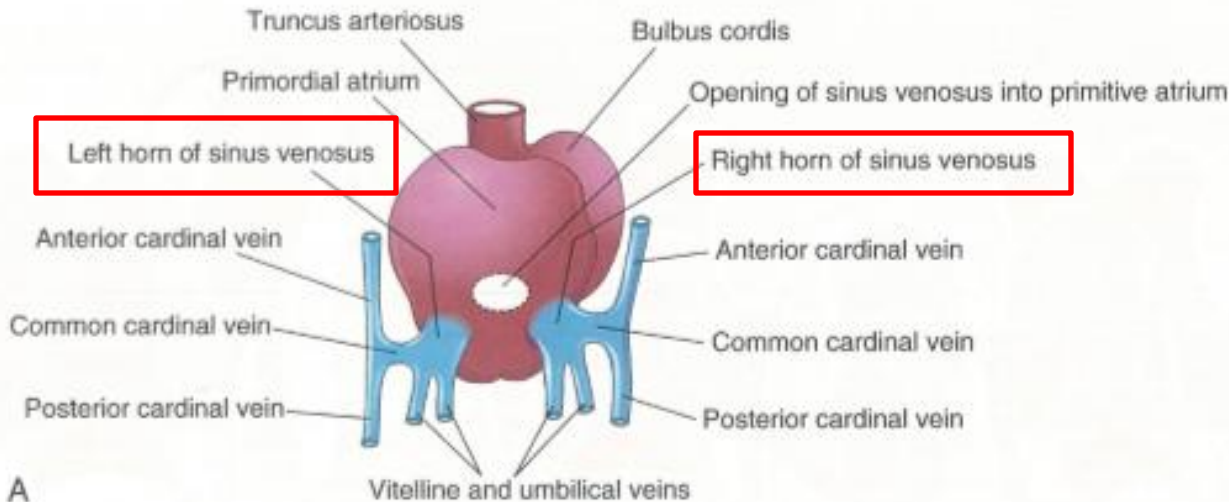
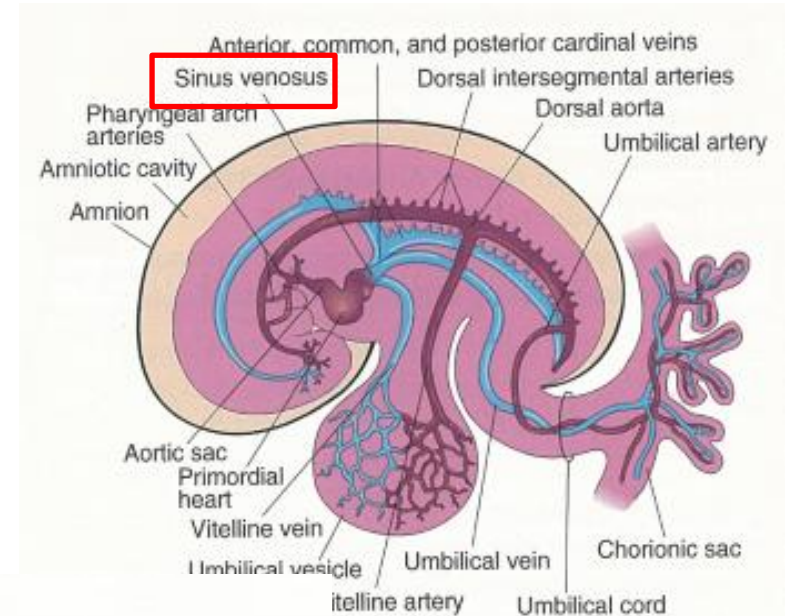


# POSITIONING AND INTERNAL STRUCTURE

## SINUS VENOSUS AND RIGHT ATRIUM:

### PARTS OF THE SINUS VENOSUS:

- a. right sinus horn
- b. isthmus
- c. left sinus horn

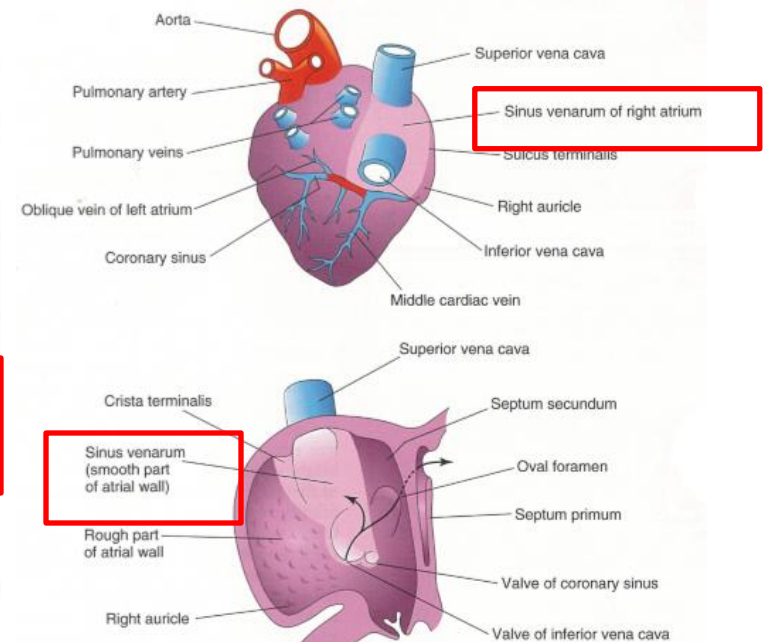
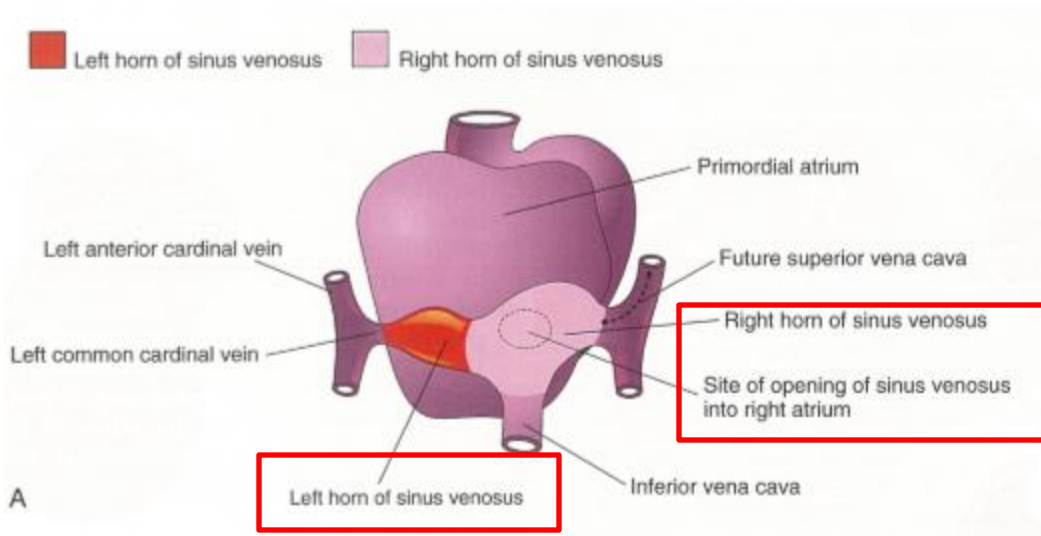


A

# POSITIONING AND INTERNAL STRUCTURE

## SINUS VENOSUS AND RIGHT ATRIUM:

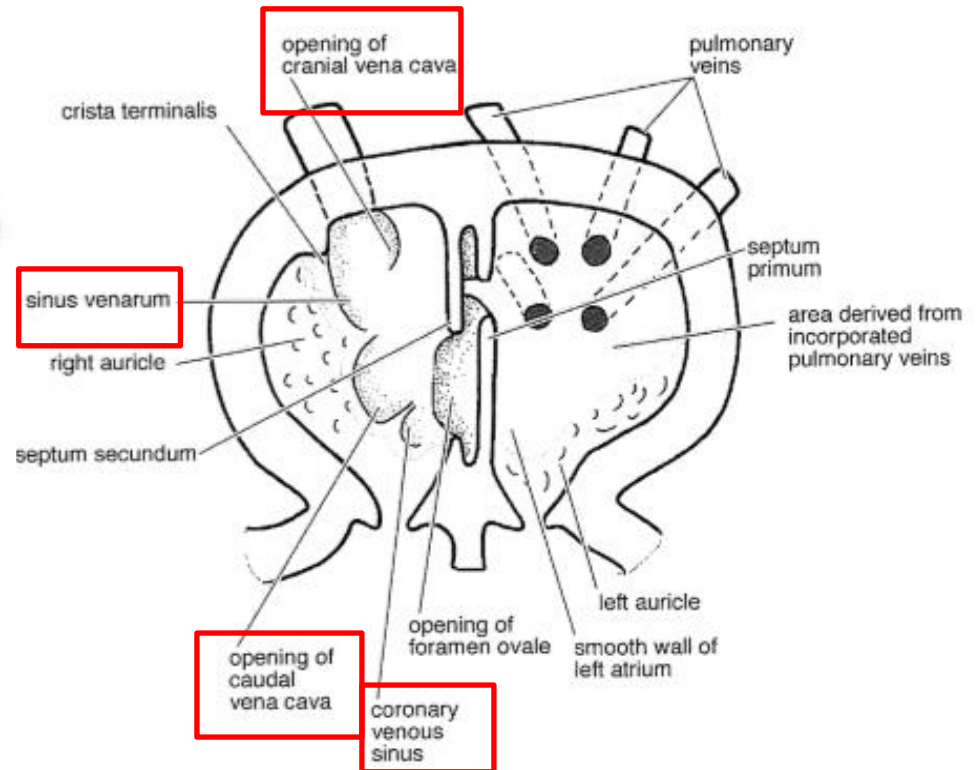
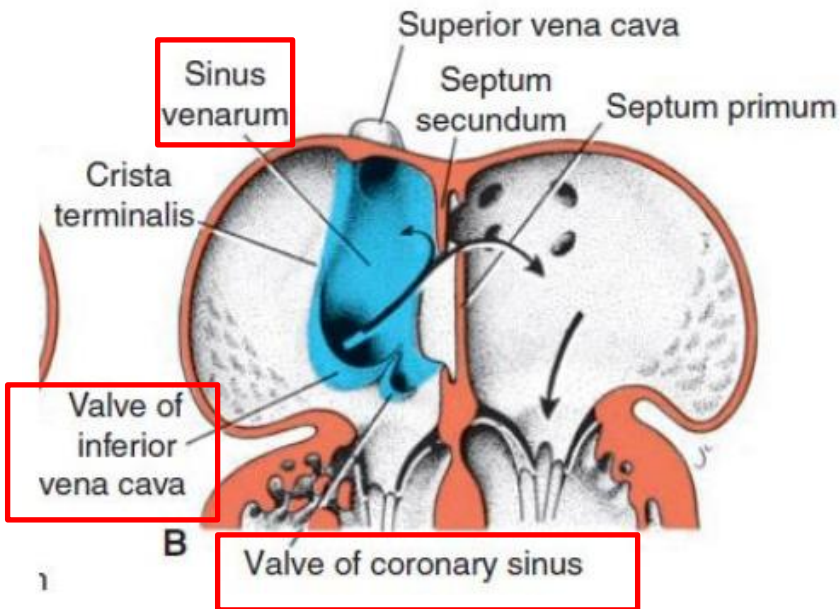
- f. the entire sinus venosus absorbed into the dorsal wall of the right atrium – and becomes part of the right atrium
1. the right sinus horn of the sinus venosus forms most of the smooth walled portion of the adult right atrium - sinus venarum cavarum
  2. the left sinus horn and the isthmus of the sinus venosus form the coronary sinus
  3. the auricles are derivatives of the primitiv atrium



# POSITIONING AND INTERNAL STRUCTURE

## SINUS VENOSUS AND RIGHT ATRIUM:

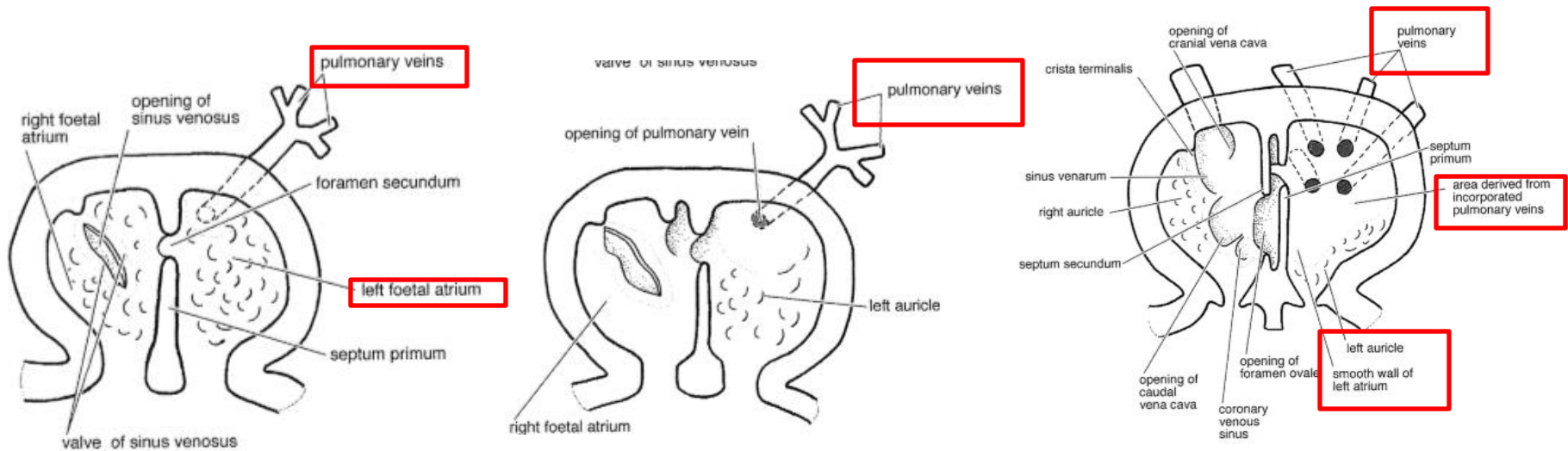
- the caudal and cranial vena cava and the coronary sinus have separate, direct openings into the right atrium
- the openings of the caudal vena cava and coronary sinus are guarded by remnants of the right valve of the sinus venosus – these remnants persist as the valves of the caudal vena cava and coronary sinus in young domestic animals



# POSITIONING AND INTERNAL STRUCTURE

## LEFT ATRIUM:

- the part of the left primitive atrium to the left of the primary interatrial septum forms the left auricle
- the smooth walled portion of the left atrium arises mostly from the pulmonary veins

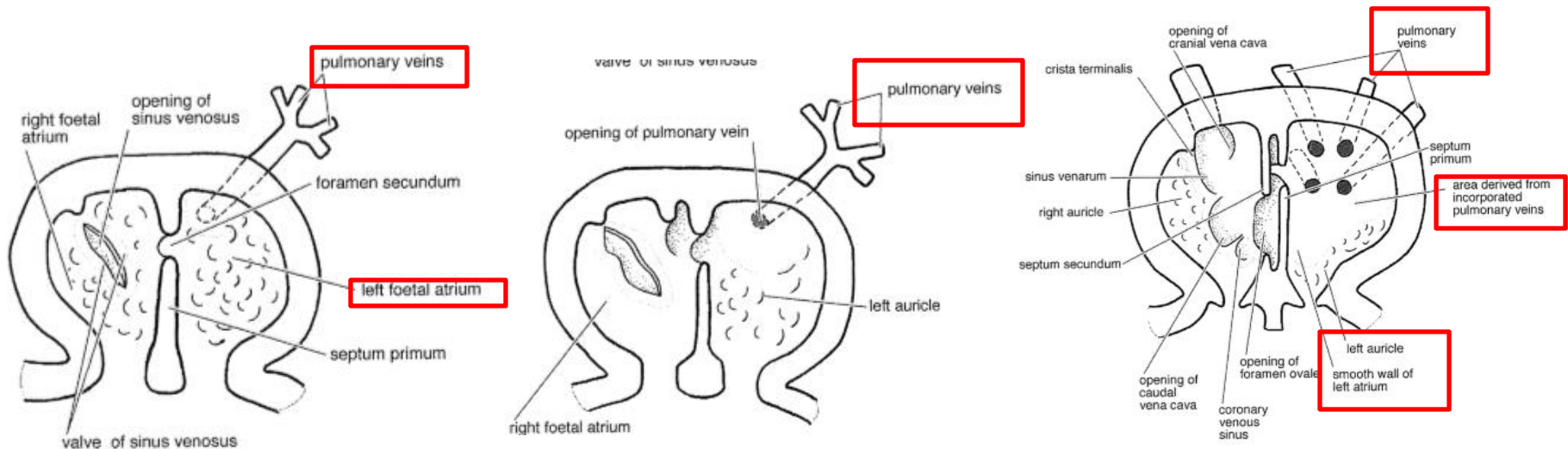


# POSITIONING AND INTERNAL STRUCTURE

## LEFT ATRIUM:

### PULMONARY VEIN:

- is a single vessel, that enters the left atrium
- develops a branch to each of the lobes of the developing lungs
- the absorption of the vein and its branches by the left atrium results in each lobar branches entering the atrium independently
- in adult there are 4 – to 8 pulmonary veins entering the left atrium

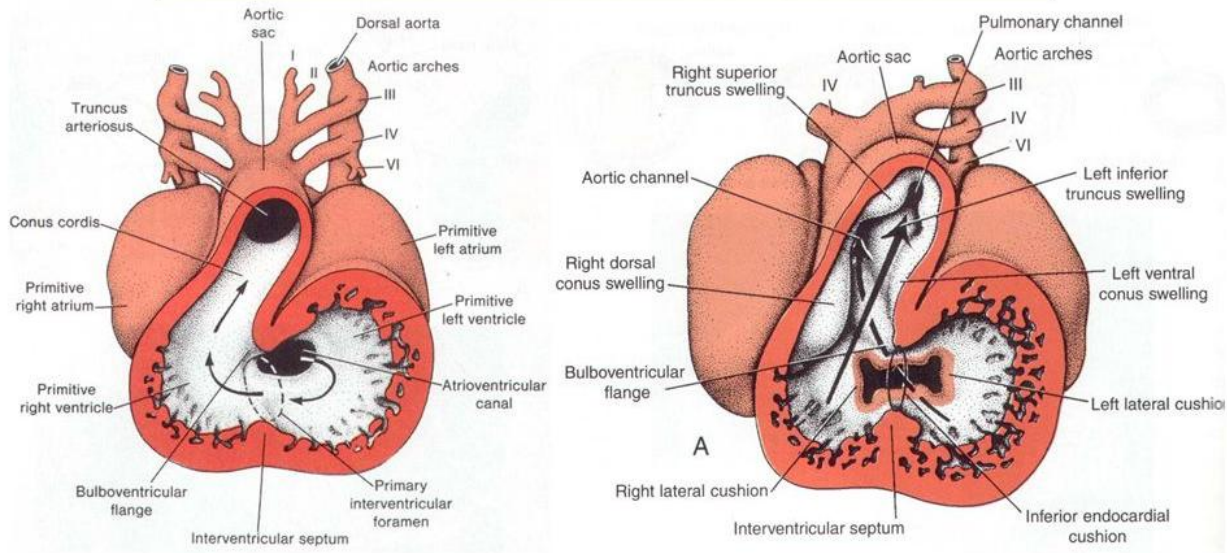
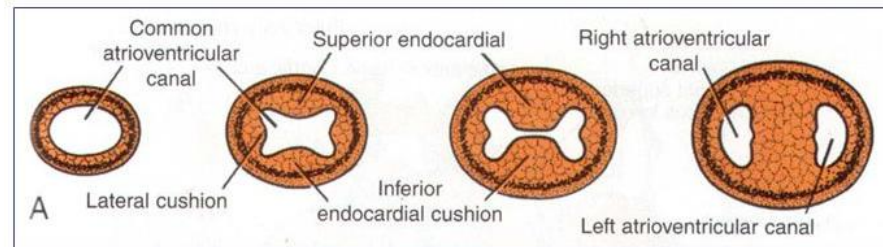


# POSITIONING AND INTERNAL STRUCTURE

## VENTRICLES:

### I. INTERNAL TOPOGRAPHY AND INITIAL PARTITIONING:

1. the bulbus and the ventricular parts of the cardiac loop begin to enlarge – this results in an irregular internal topography of ridges and depressions – which are the forerunners of the trabecula carnea

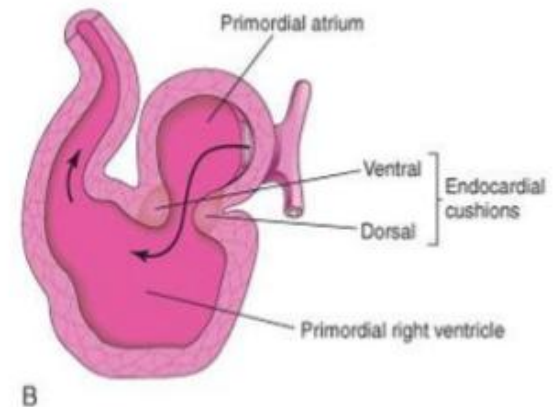
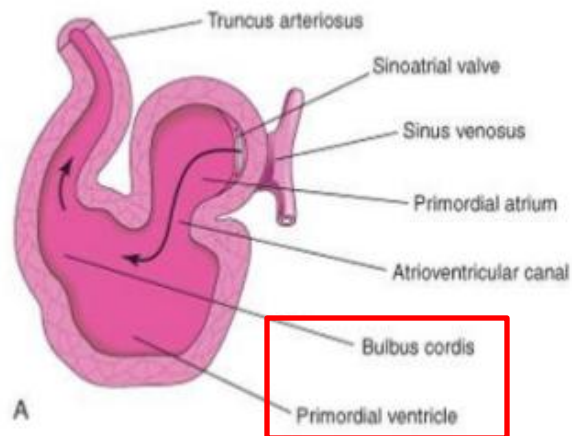
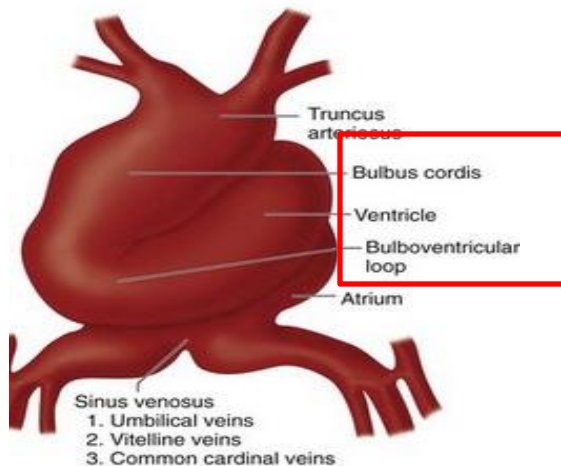


# POSITIONING AND INTERNAL STRUCTURE

## VENTRICLES:

### II. INITIAL PARTITIONING BY MUSCULAR SEPTUM:

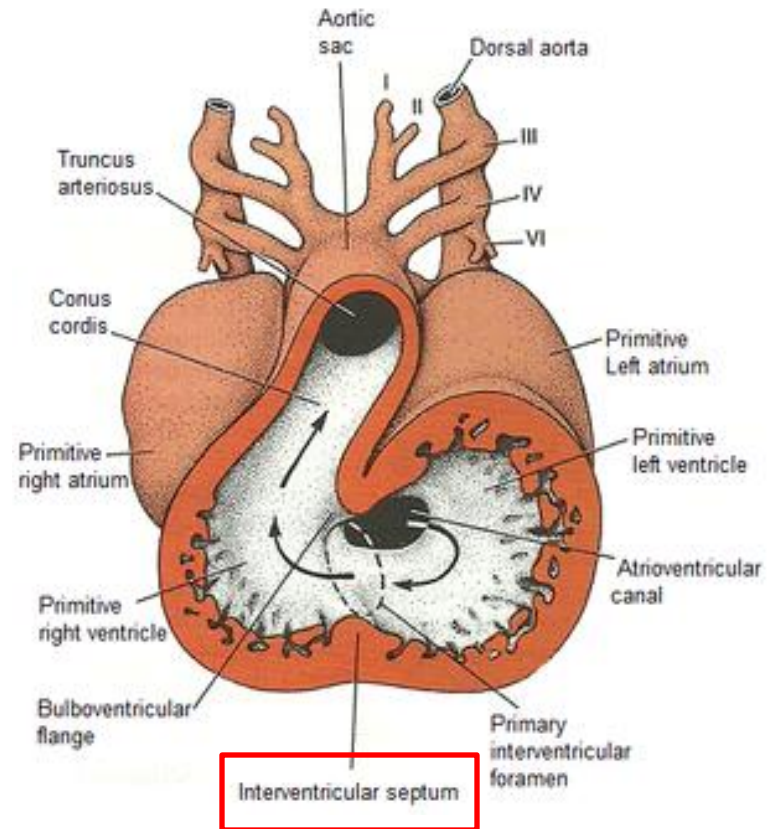
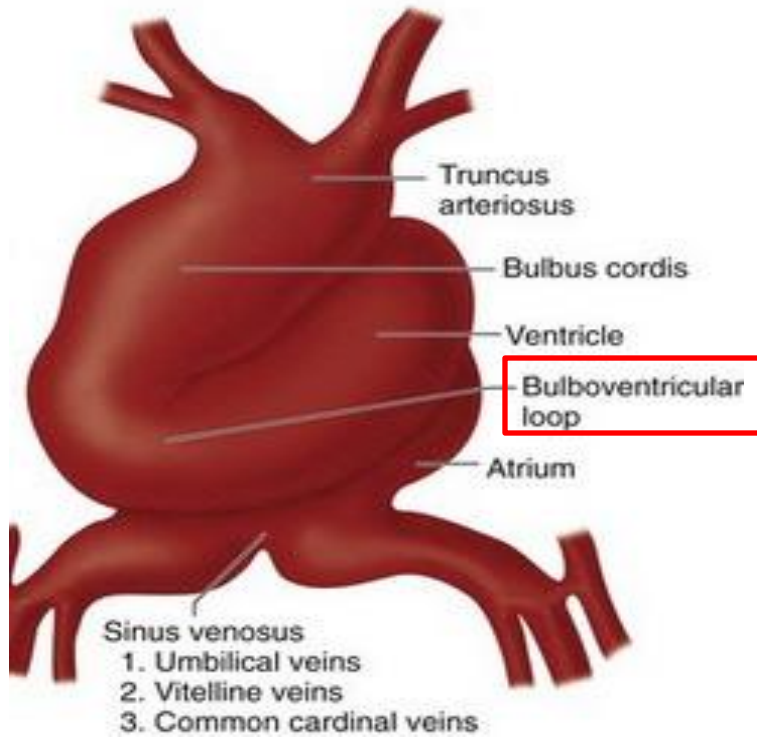
- the constricted area at the apex of the bulboventricular loop represents the general boundary between the future ventricle
  - a. at the apex of the loop a muscular ridge develops ventrally – it is located between the areas derived from the limbs of the loop
  - b. the muscular ridge joins another that develops more caudodorsally on the wall of the ventricle – the ridges fused – representing the forerunner of the muscular part of the interventricular septum



# POSITIONING AND INTERNAL STRUCTURE

## VENTRICLES:

### II. INITIAL PARTITIONING BY MUSCULAR SEPTUM:



Frontal section through the heart

Arrows: direction of blood flow

# POSITIONING AND INTERNAL STRUCTURE

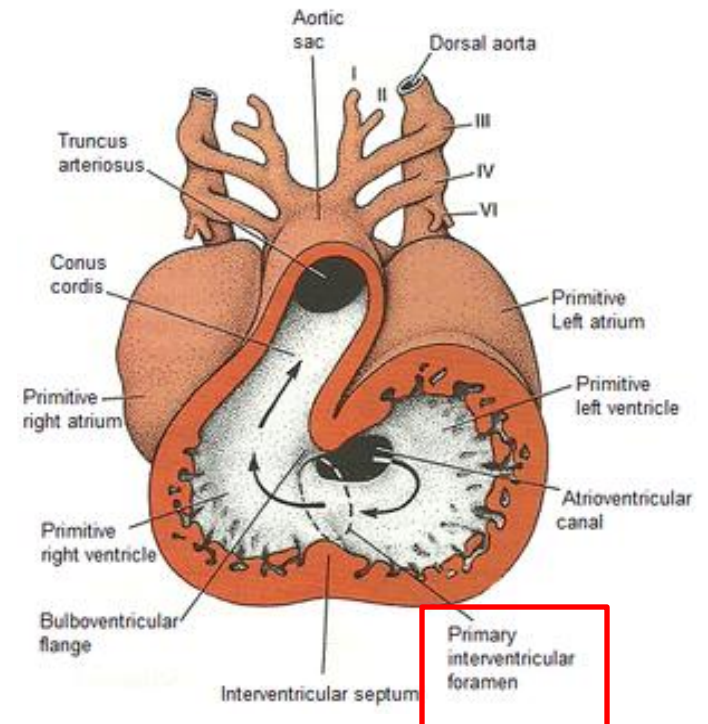
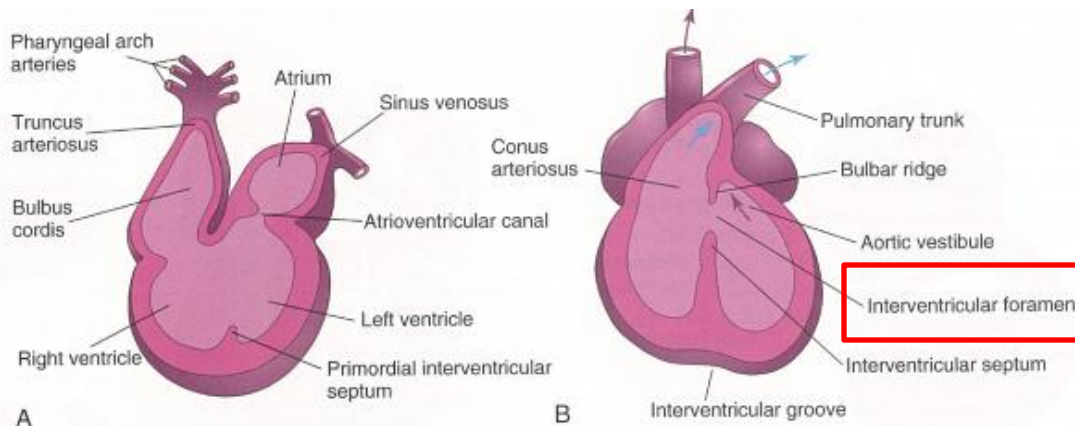
## VENTRICLES:

### II. INITIAL PARTITIONING BY MUSCULAR SEPTUM:

c. the opening between the right and the left ventricles (primary interventricular foramen, foramen interventriculare primum)

PRIMARY INTERVENTRICULAR FORAMEN is bounded by two structures

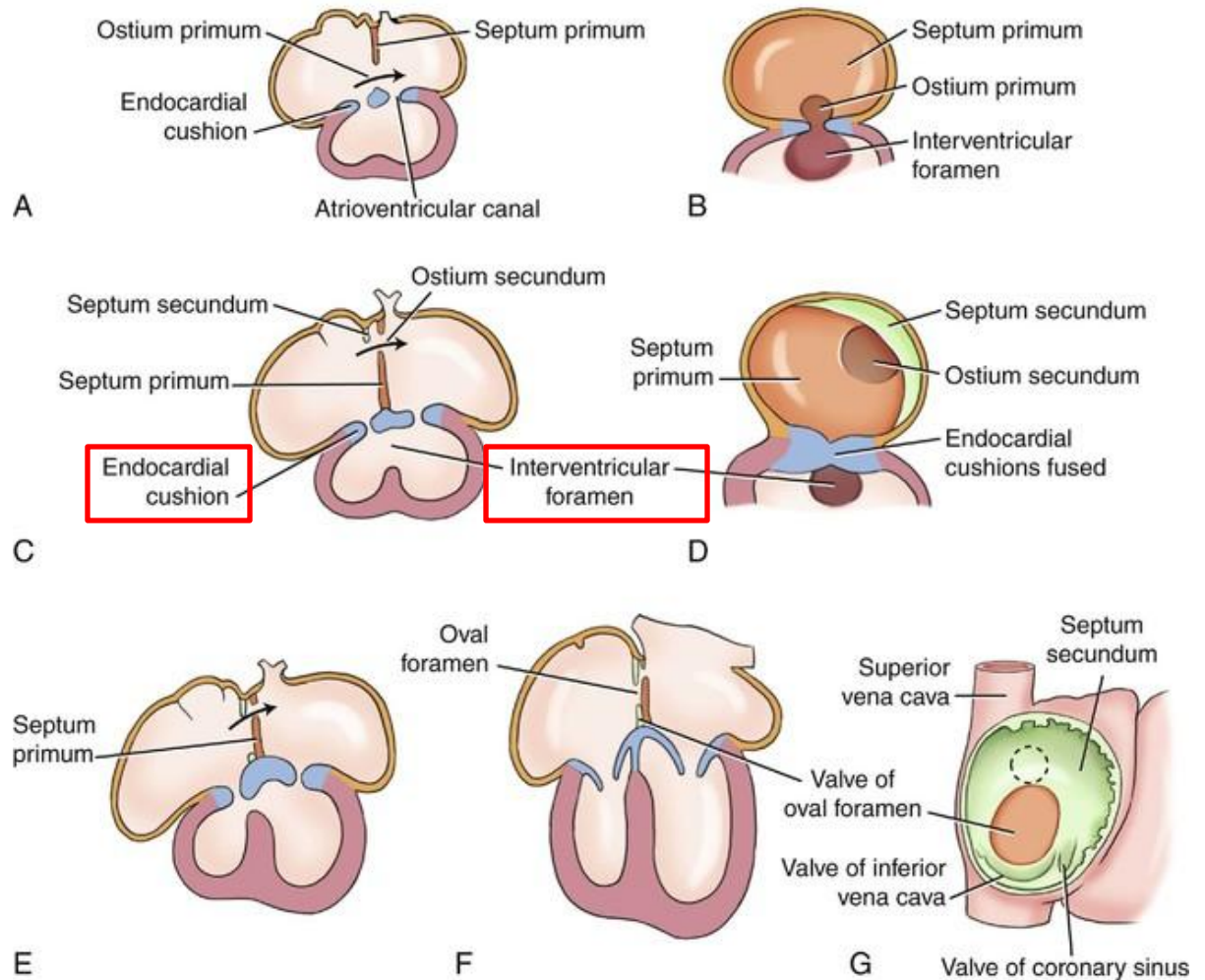
1. its dorsal boundary is the fused endocardial cushions
  2. ventrally is bounded by the muscular interventricular septum
- its corresponds to the apex of the original bulboventricular loop



# POSITIONING AND INTERNAL STRUCTURE

## VENTRICLES:

### PRIMARY INTERVENTRICULAR FORAMEN



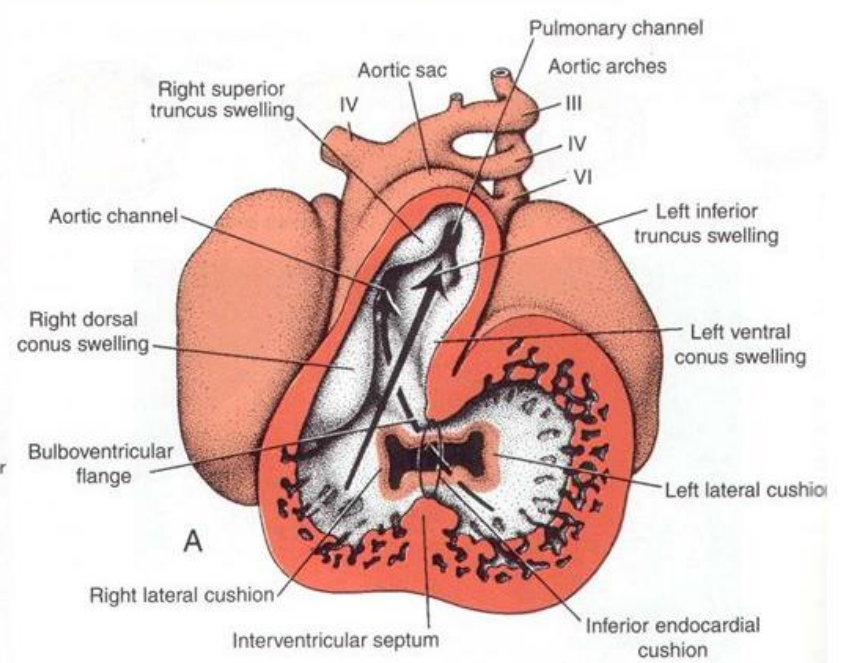
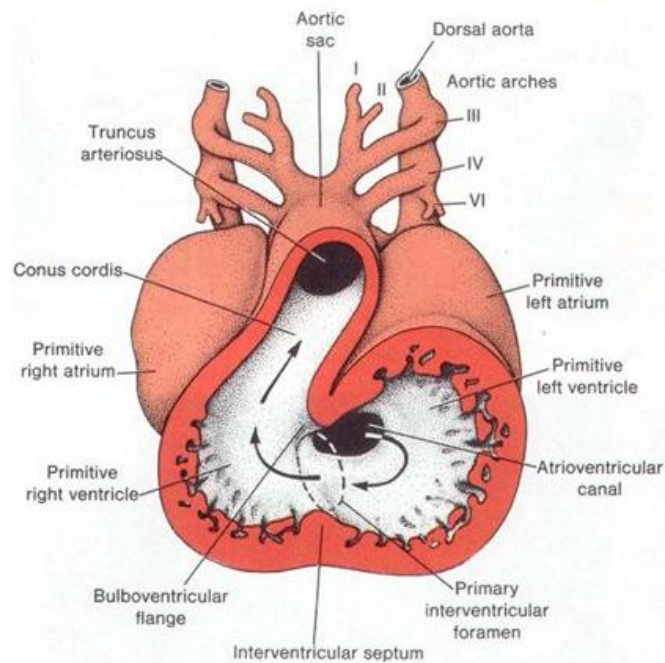
# POSITIONING AND INTERNAL STRUCTURE

VENTRICLES:

II. INITIAL PARTITIONING BY MUSCULAR SEPTUM:

d. the ventricles elongate

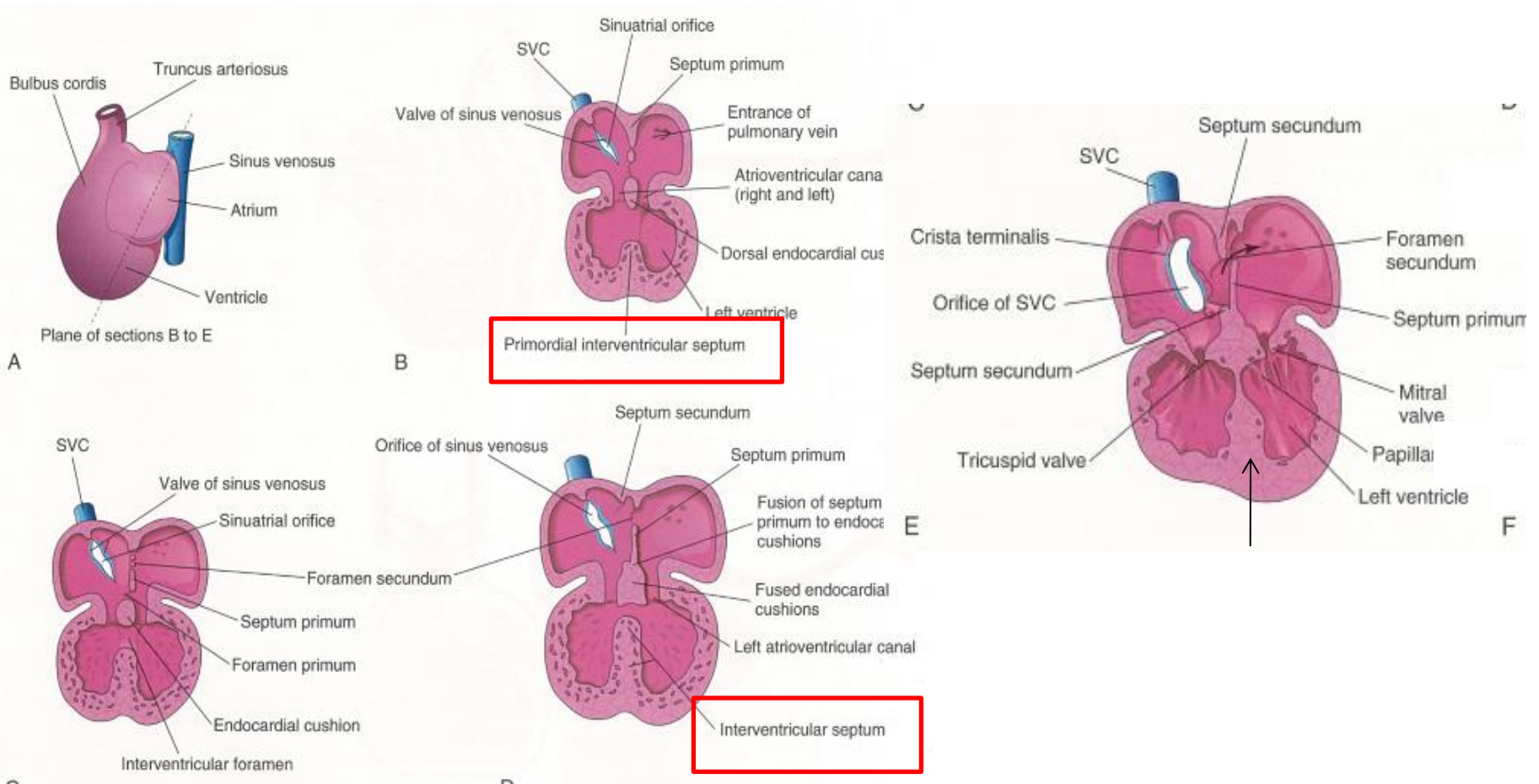
e. the interventricular septum increases in height



# POSITIONING AND INTERNAL STRUCTURE

## VENTRICLES:

### II. INITIAL PARTITIONING BY MUSCULAR SEPTUM:



# POSITIONING AND INTERNAL STRUCTURE

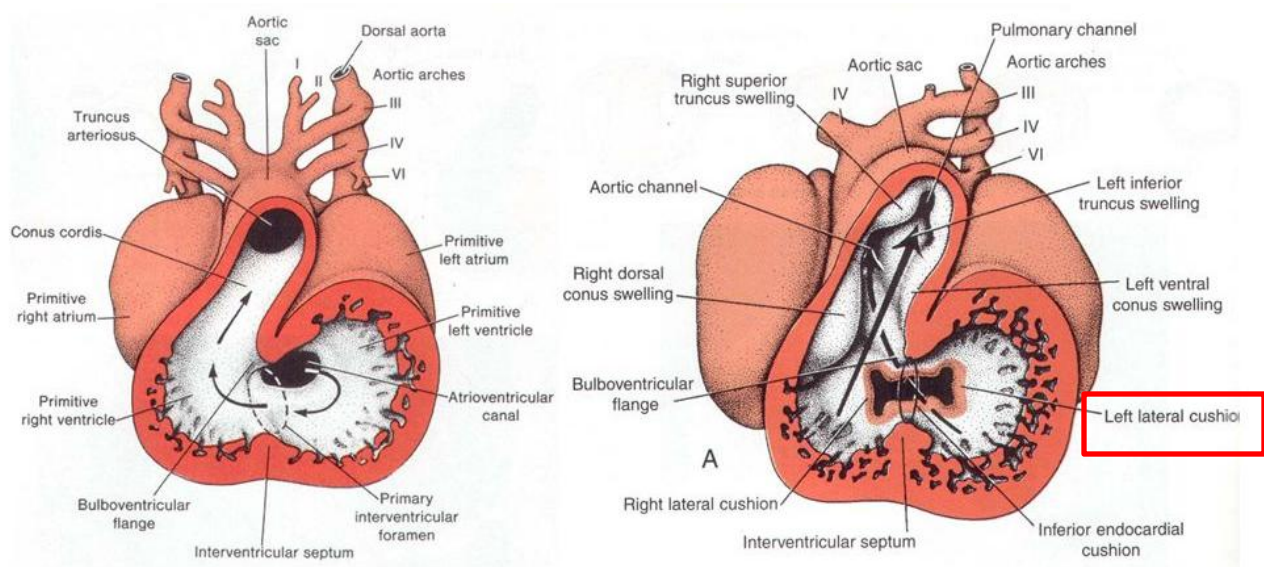
## VENTRICLES:

### III. INTERNAL TOPOGRAPHY:

- the areas that form the right and the left ventricles are well defined internally by the muscular interventricular septum

## LEFT VENTRICLE:

- the area to the left of the septum forms the left ventricle
- this area derived from the major portion of the caudal limb of the bulboventricular loop



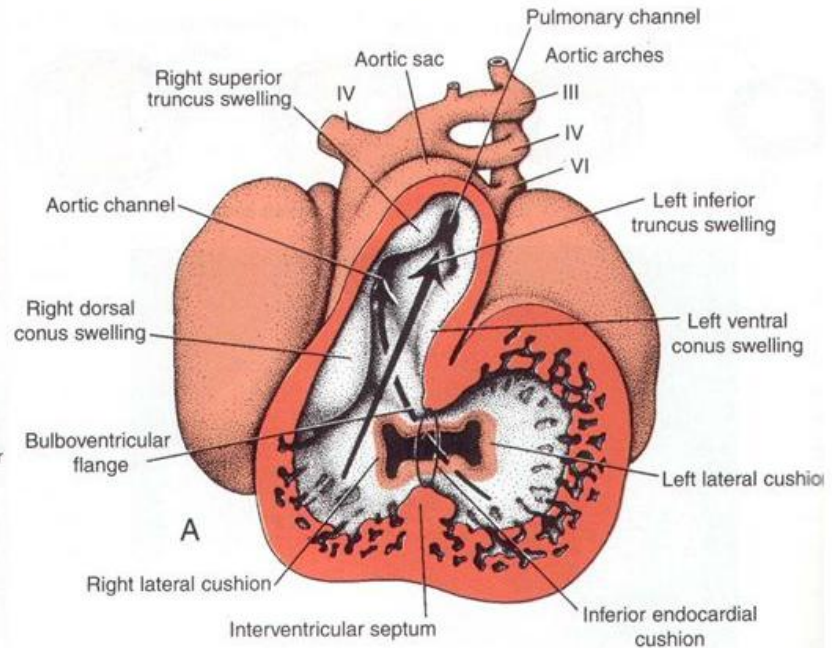
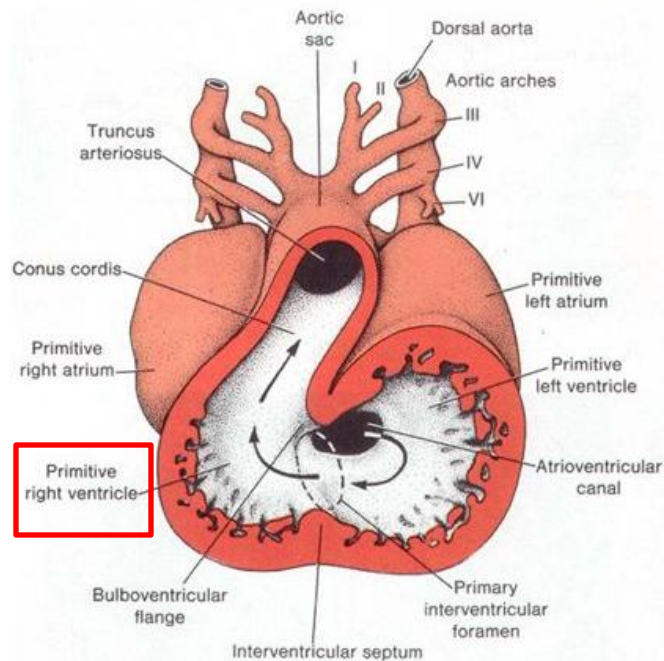
# POSITIONING AND INTERNAL STRUCTURE

VENTRICLES:

III. INTERNAL TOPOGRAPHY:

RIGHT VENTRICLE:

- a. the area to the right of the septum forms the right ventricle
- b. this area arises from the cranial limb, and small portion of the caudal limb of the bulboventricular loop



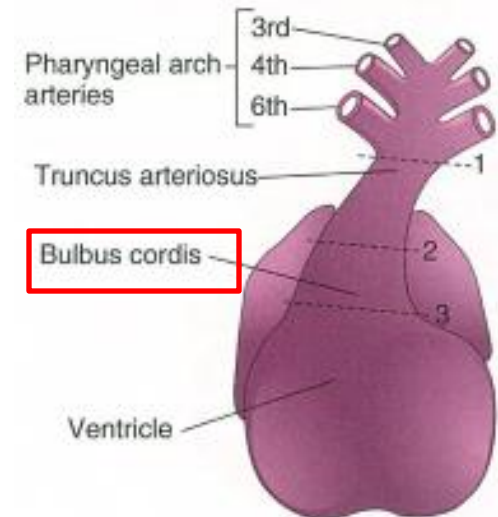
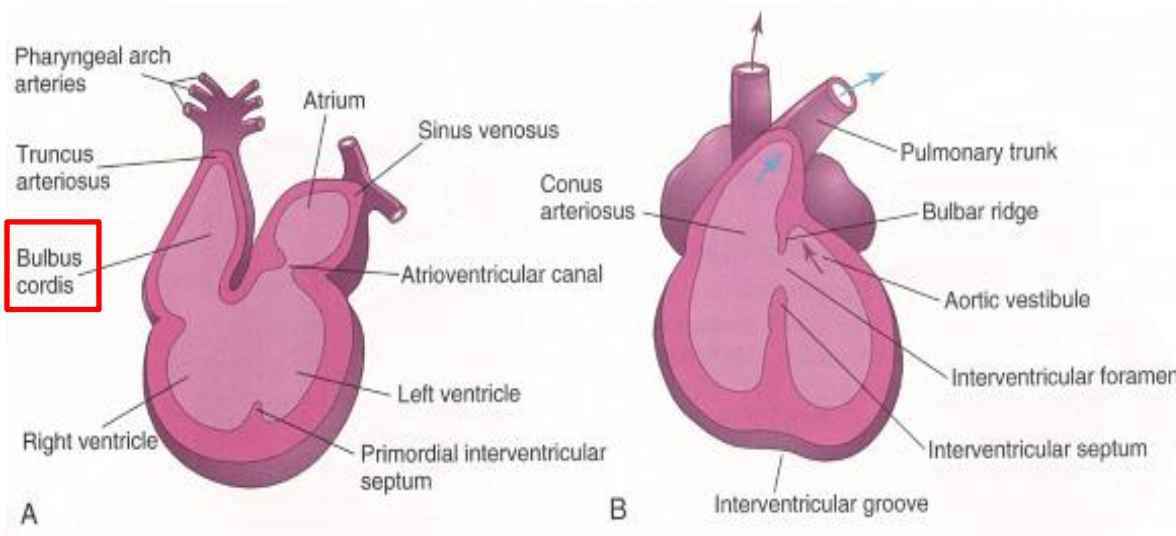
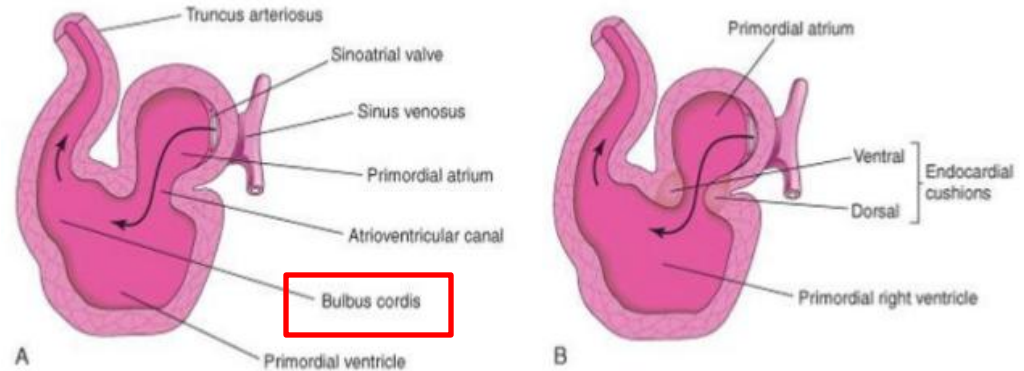
# POSITIONING AND INTERNAL STRUCTURE

## VENTRICLES:

### III. INTERNAL TOPOGRAPHY:

#### BULBUS CORDIS:

- the major part of the cranial limb of the bulboventricular loop
- the portion of the loop, which communicates with the truncus arteriosus
- forms the outflow tracts of the ventricles



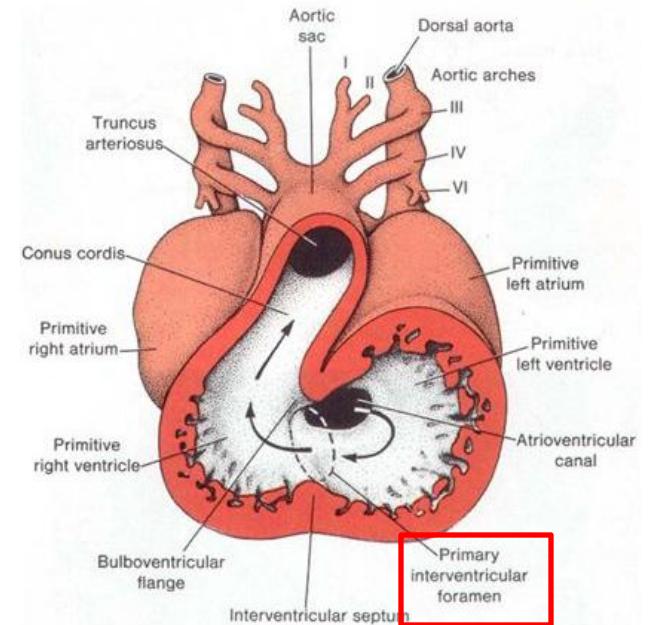
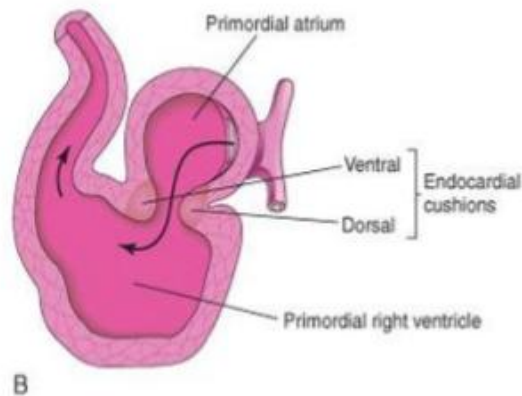
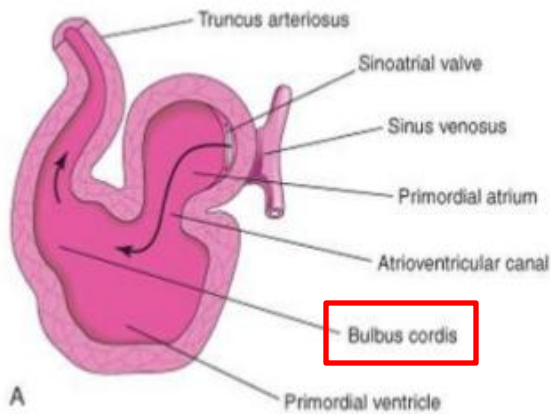
# POSITIONING AND INTERNAL STRUCTURE

VENTRICLES:

III. INTERNAL TOPOGRAPHY:

BULBUS CORDIS:

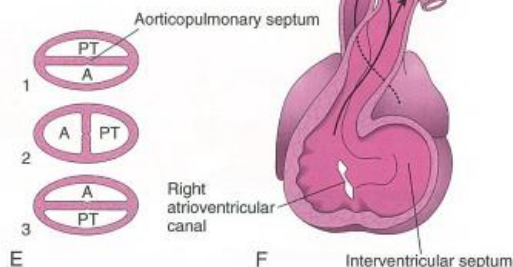
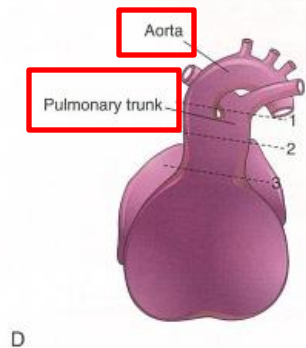
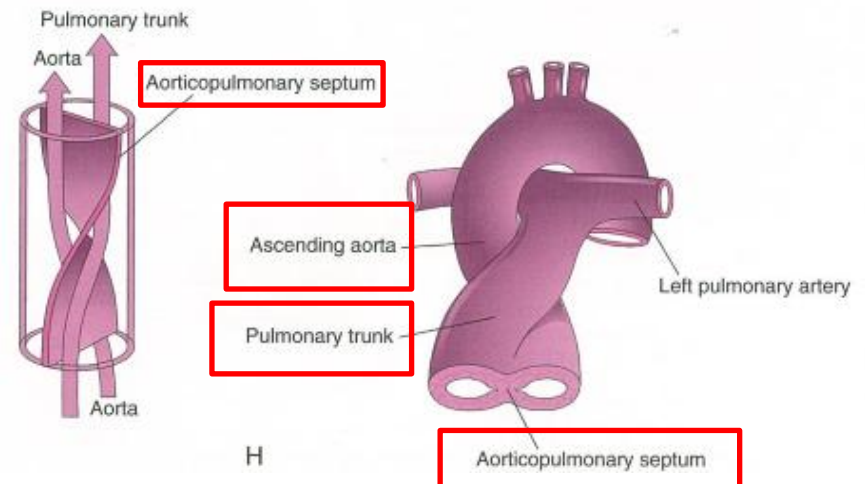
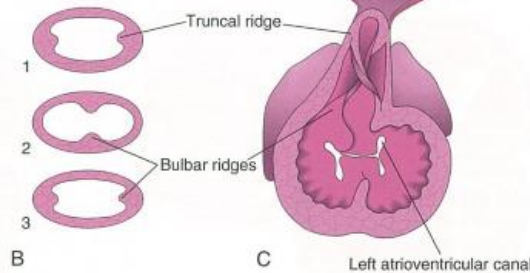
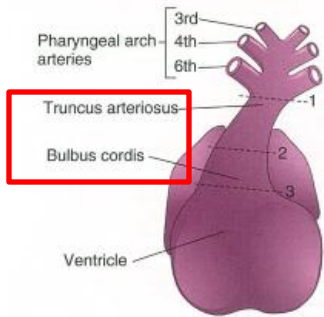
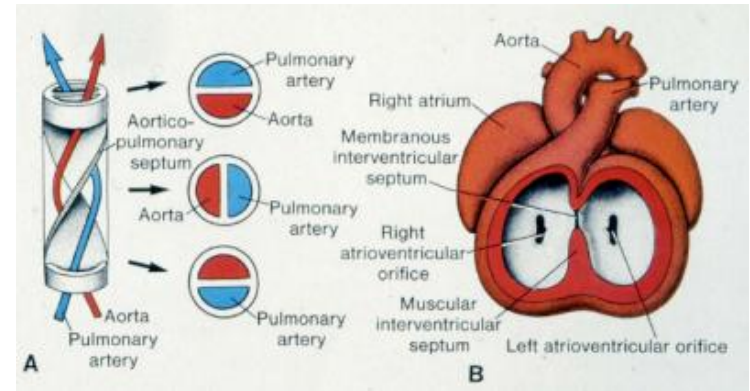
1. the outflow from the heart is entirely from the right ventricle at this stage
2. the right ventricle communicates with the truncus arteriosus via bulbus cordis
3. the left ventricle communicates with the bulbus cordis through the primary interventricular foramen



# POSITIONING AND INTERNAL STRUCTURE

## PARTITIONING OF THE VENTRICULAR OUTFLOW TRACT:

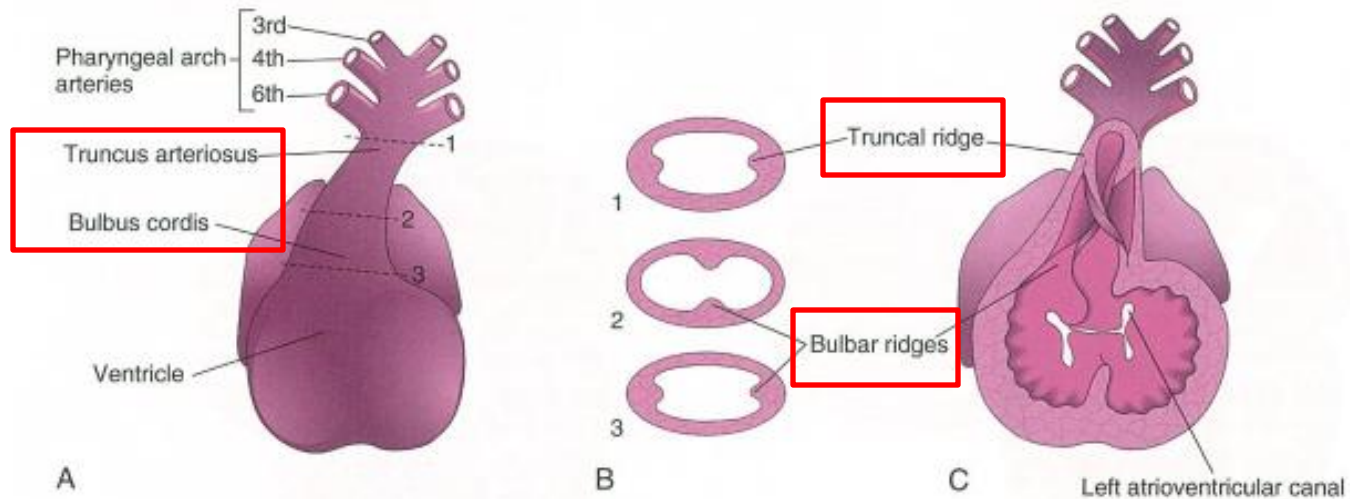
- the truncus arteriosus and the bulbus cordis are being partitioned into:
  - a. pulmonary part
  - b. aortic part
  - c. the partitioning of the ventricles also completed during this time



# POSITIONING AND INTERNAL STRUCTURE

## PARTITIONING OF TRUNCUS ARTERIOSUS AND BULBUS CORDIS:

1. active proliferation of the mesenchymal cells in the wall of the bulbus cordis results in the formation of the bulbar ridges
2. similar ridges form in the truncus arteriosus – truncal ridges
3. the truncal ridges continuous with the bulbar ridges
4. the bulbar and the truncal ridges derivated from the neural crest mesenchyme



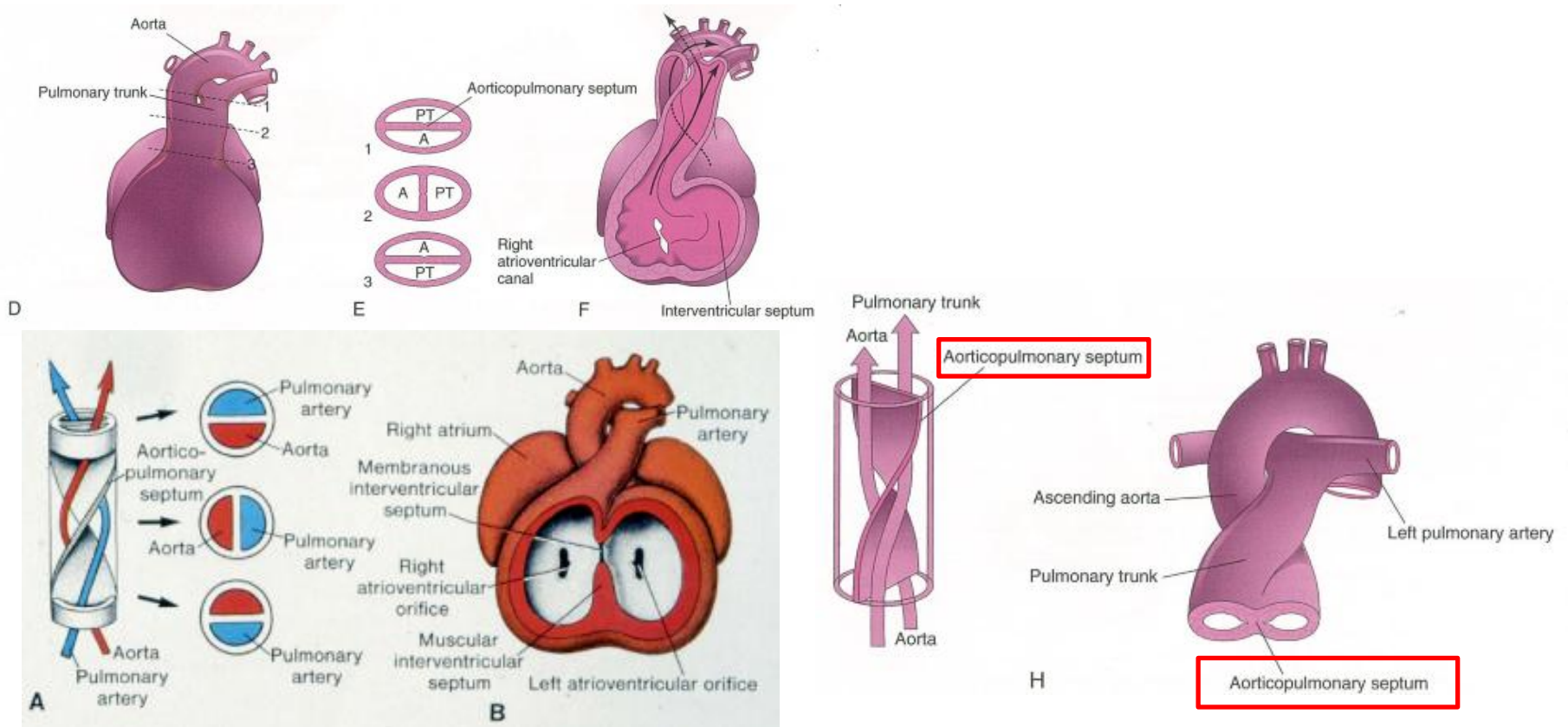
# POSITIONING AND INTERNAL STRUCTURE

## PARTITIONING OF TRUNCUS ARTERIOSUS AND BULBUS CORDIS:

### 4. the bulbar and the truncal ridges undergo 180-degree spiraling

- the spiral orientation of the bulbar and the truncal ridges caused by the streaming of blood from the ventricles

- resulting in formation of a spiral aortopulmonary septum, when the ridges fuse



# POSITIONING AND INTERNAL STRUCTURE

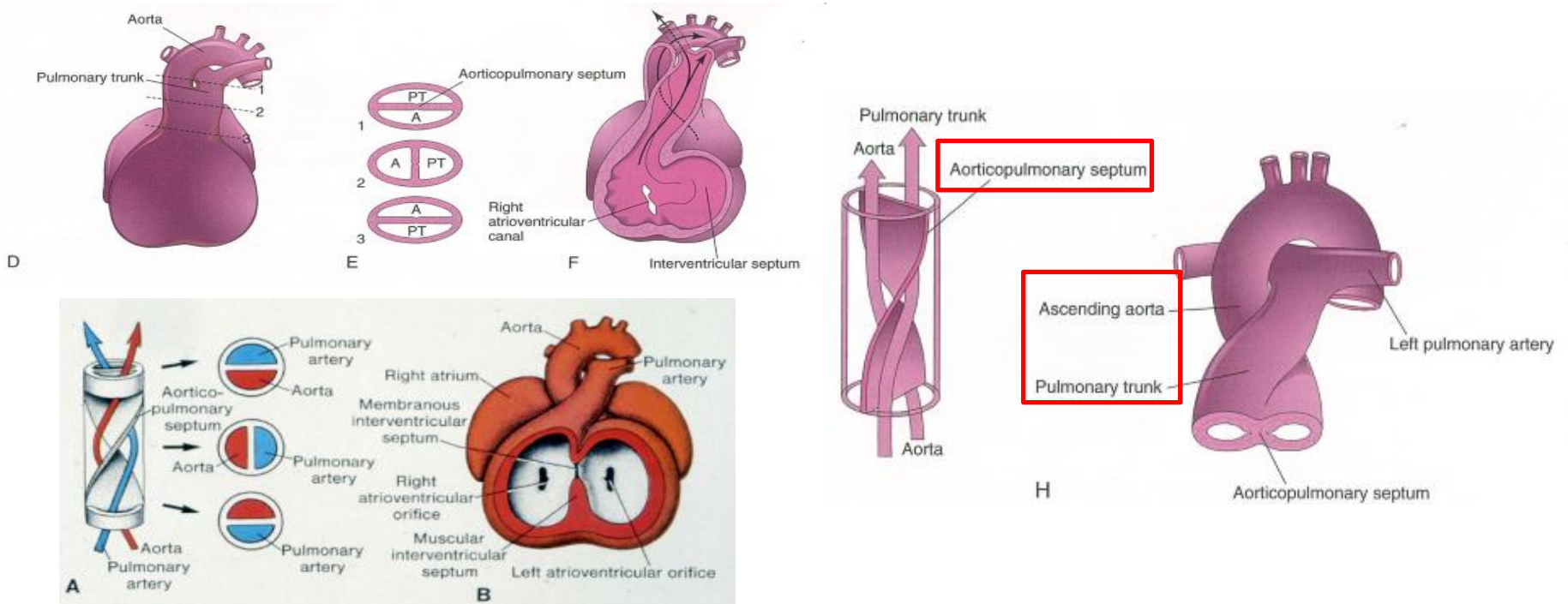
## PARTITIONING OF TRUNCUS ARTERIOSUS AND BULBUS CORDIS:

5. the aortopulmonary septum divides the bulbus cordis and the truncus arteriosus into two arterial channels:

a. aorta

b. pulmonary trunk

- because of the spiraling of the aortopulmonary septum, the pulmonary trunk twists around the ascending aorta

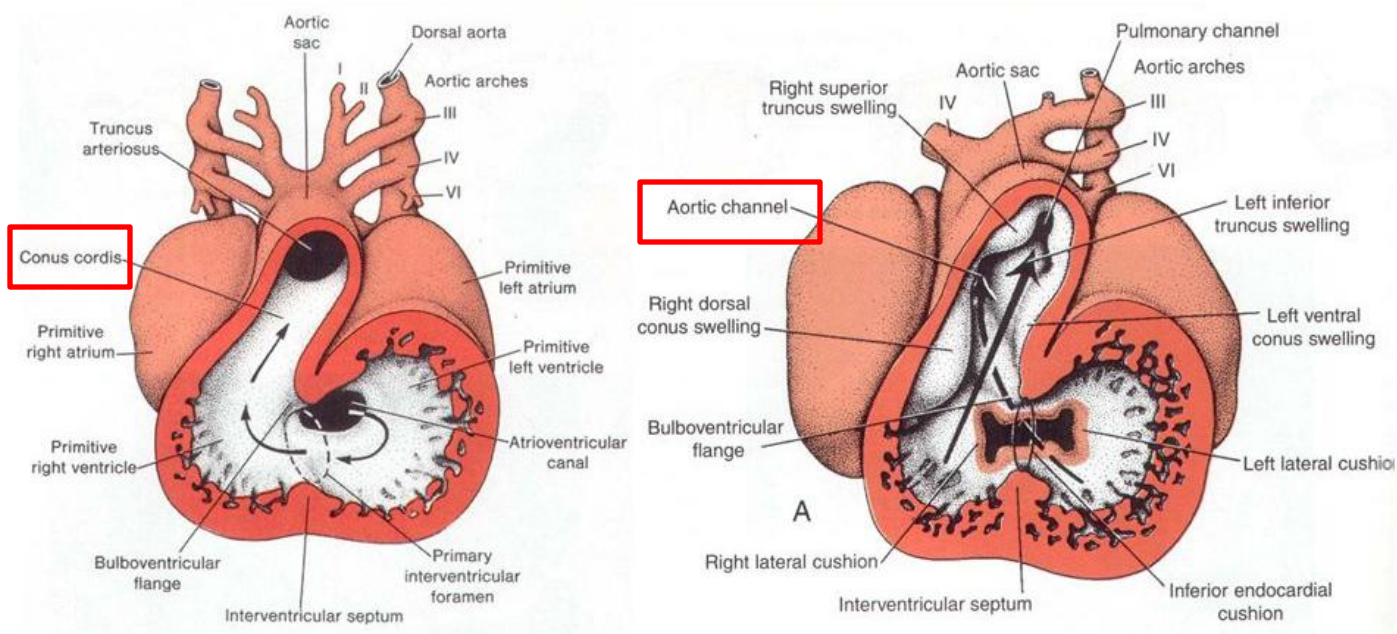


# POSITIONING AND INTERNAL STRUCTURE

## BULBUS CORDIS:

is incorporated into the walls of the definitive ventricles in several ways:

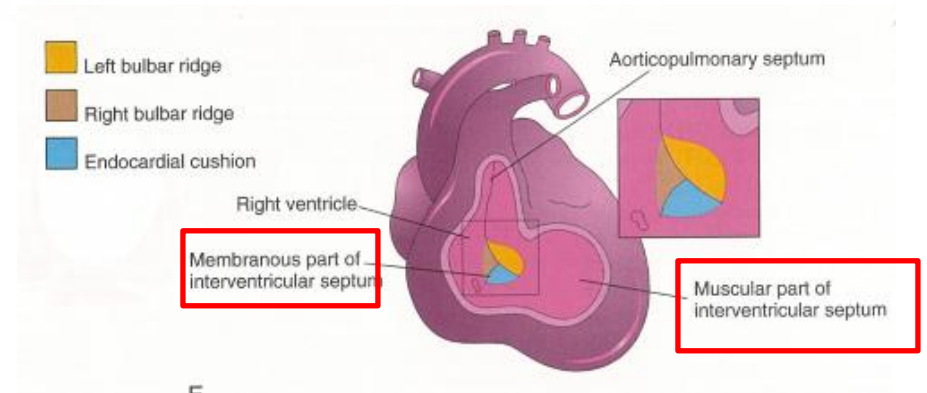
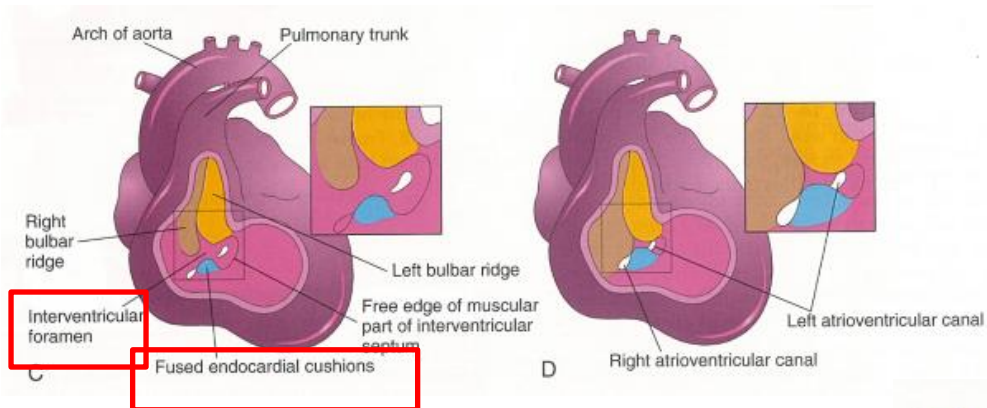
- in the right ventricle, the **bulbus cordis is represented by the conus arteriosus (infundibulum), which gives origin to the pulmonary trunk**
- in the left ventricle, the **bulbus cordis forms the walls of the aortic vestibule aortic outflow - the part of the ventricular cavity just inferior to the aortic valve**



# POSITIONING AND INTERNAL STRUCTURE

## COMPLETION OF THE PARTITIONING:

- at this stage a small communication between the proximal part of the aortic vestibule and the right ventricle persists - secondary interventricular foramen
- the secondary interventricular foramen closed by the arch of fused endocardial cushions – this obliterates the secondary interventricular foramen and completes the interventricular septum

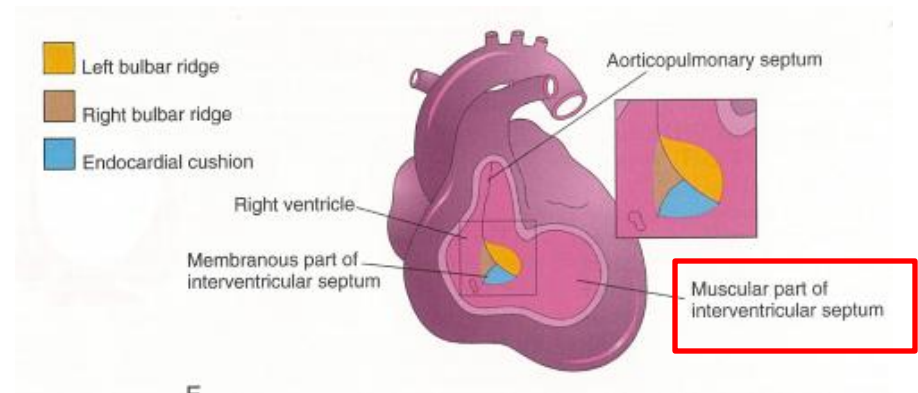
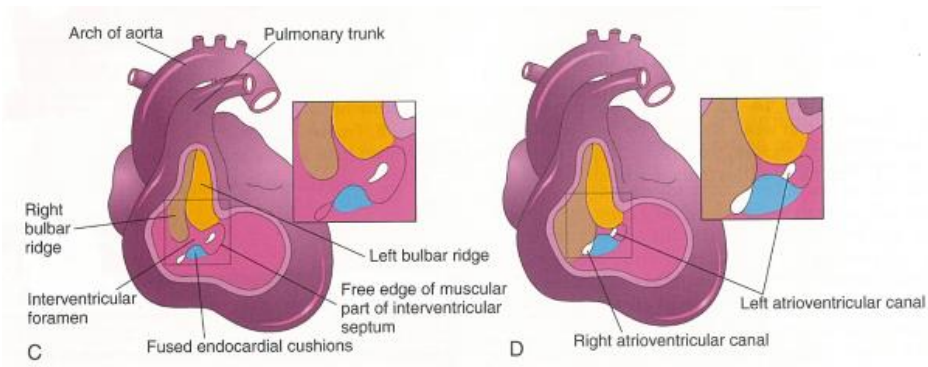


# POSITIONING AND INTERNAL STRUCTURE

## COMPLETION OF THE PARTITIONING:

### INTERVENTRICULAR SEPTUM formed by:

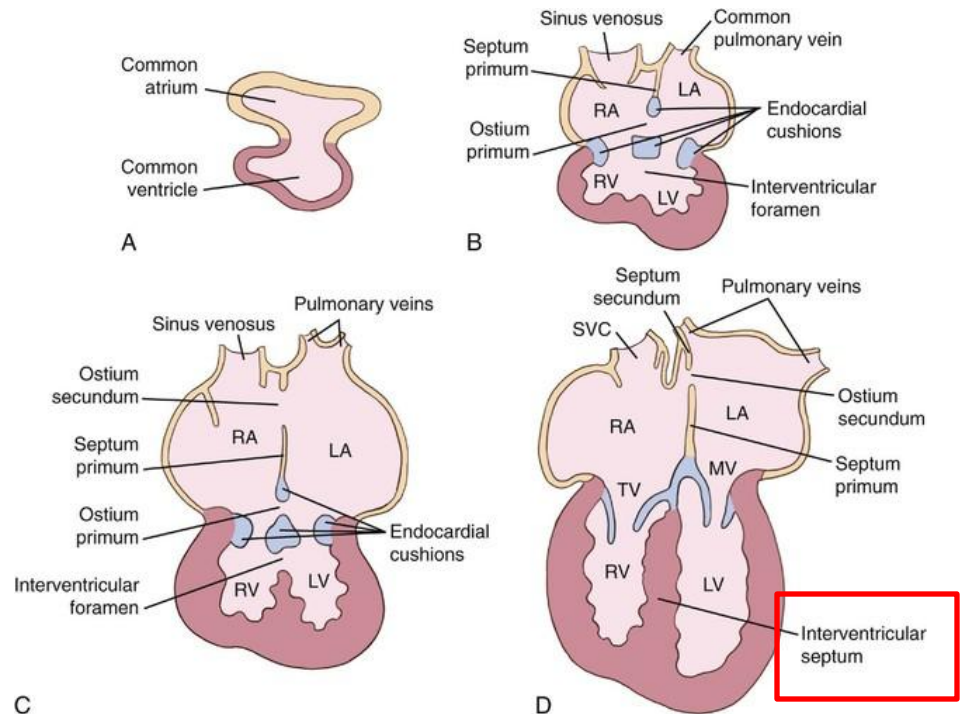
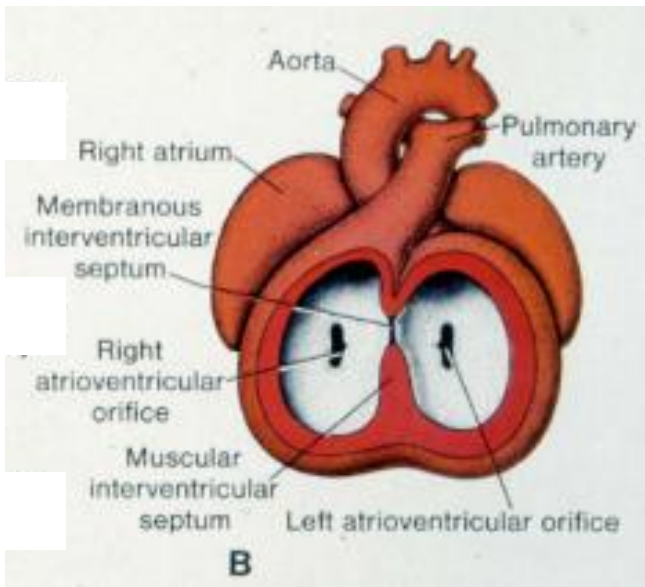
1. **muscular ridges** - muscular part of the septum, separates the ventricles
2. **part of the spiral septum (aorticopulmonary septum)** – separates the conus arteriosus and the aortic vestibule
3. **ventral growth from the endocardial cushions** – membranous part of the septum



# POSITIONING AND INTERNAL STRUCTURE

## ALIGNMENT OF AORTIC AND PULMONARY PARTS OF THE TRUNCUS:

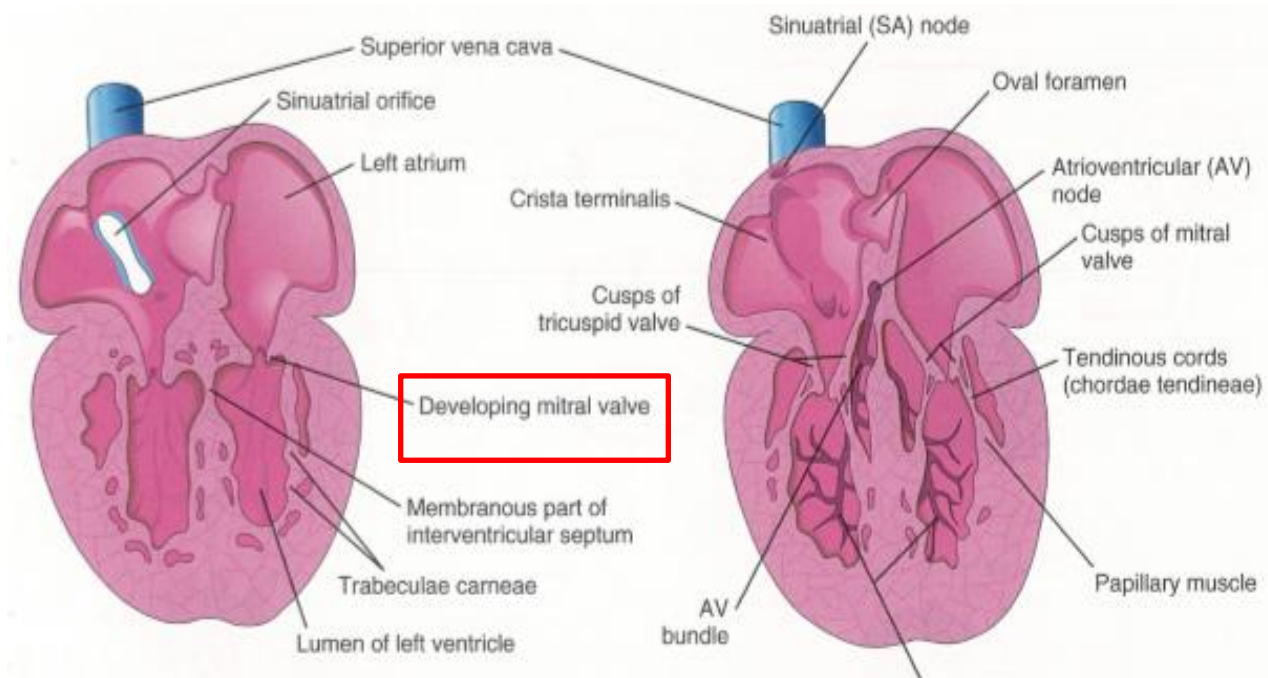
- the integrity of the outflow tracts within the heart is complete with the closure of the secondary interventricular foramen
- a. the right ventricle communicates with the pulmonary trunk via the pulmonary part of the bulbus cordis
- b. the left ventricle communicates with the aortic trunk via the aortic part of the bulbus cordis



# POSITIONING AND INTERNAL STRUCTURE

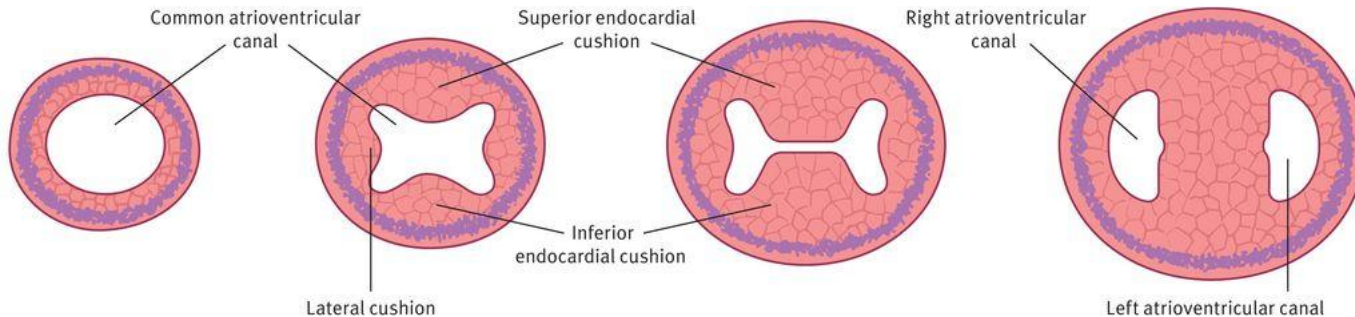
## ATRIOVENTRICULAR VALVES (AV valves):

- derivatives of the atrioventricular endocardial cushions around the atrioventricular openings
- a. three cusps are developed to form the right AV valve
- b. two cusps are developed to form the left atrioventricular (AV) valve



# POSITIONING AND INTERNAL STRUCTURE

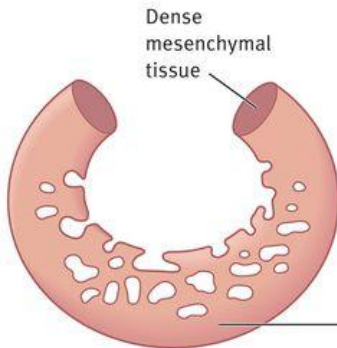
## ATRIOVENTRICULAR VALVES:



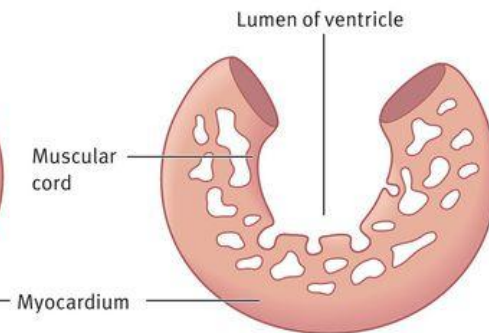
Endocardial cushions grow into the common atrioventricular canal (day 23) and result in the formation of the atrioventricular septum and the atrioventricular canals by day 35.

<https://obgynkey.com/development-of-the-heart-and-the-fetal-circulation/>

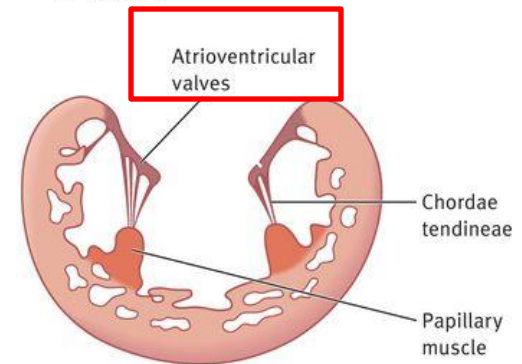
**A** End of week 5



**B** Week 7



**C** Week 20



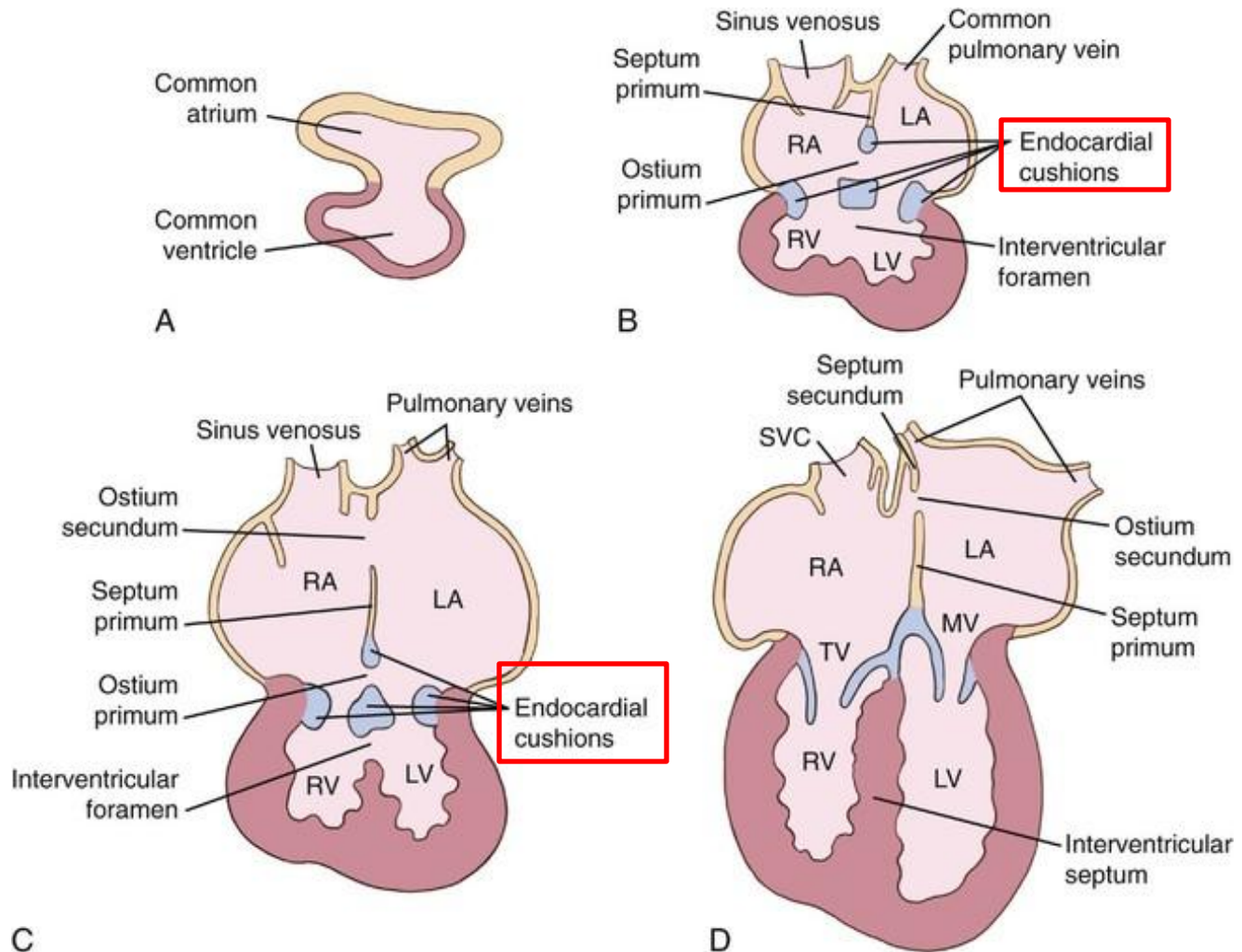
The atrioventricular orifice is surrounded by local proliferations of mesenchymal tissue. The tissue on the ventricular surface of these proliferations thins and forms valves, which remain attached to the ventricular

wall by muscular cords. The muscular tissue in the cords degenerates by week 20 and is replaced by dense connective tissue forming chordae tendineae, which now connect valves with the papillary muscles.

<https://obgynkey.com/development-of-the-heart-and-the-fetal-circulation/>

# POSITIONING AND INTERNAL STRUCTURE

## ATRIOVENTRICULAR VALVES:

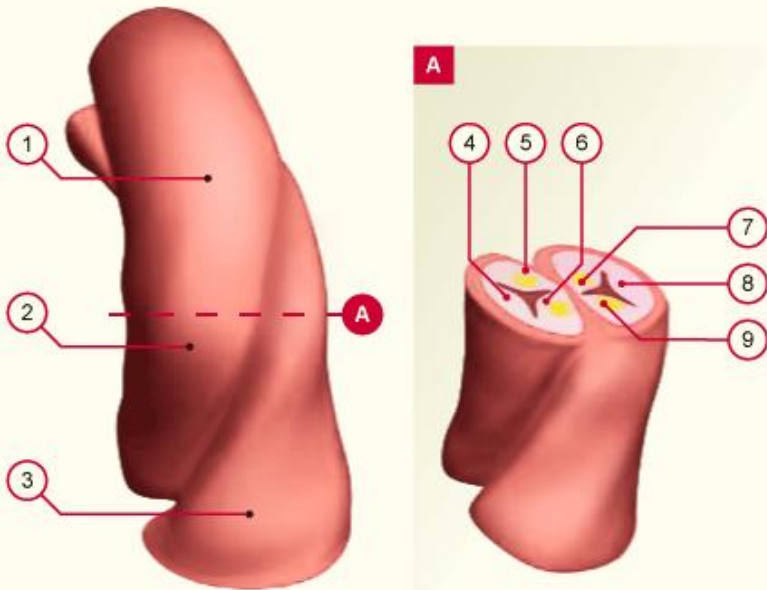


# POSITIONING AND INTERNAL STRUCTURE

## SEMILUNAR VALVES:

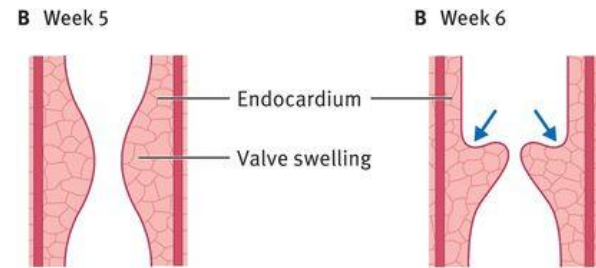
- derivatives of the endocardial cushions around the orifices of the aorta and the pulmonary trunk

<https://obgynkey.com/development-of-the-heart-and-the-fetal-circulation/>

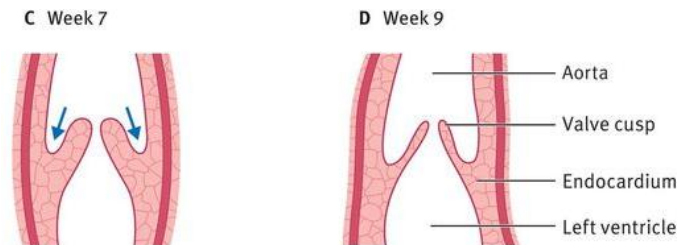


- 1 Aorta
- 2 Conotruncal crease
- 3 Truncus pulmonalis
- 4 Posterior aortic valve
- 5 Left aortic valve
- 6 Right aortic valve
- 7 Right truncus pulmonalis valve
- 8 Anterior truncus pulmonalis valve
- 9 Left truncus pulmonalis valve

<http://www.embryology.ch/anglais/pcardio/klappen02.html>



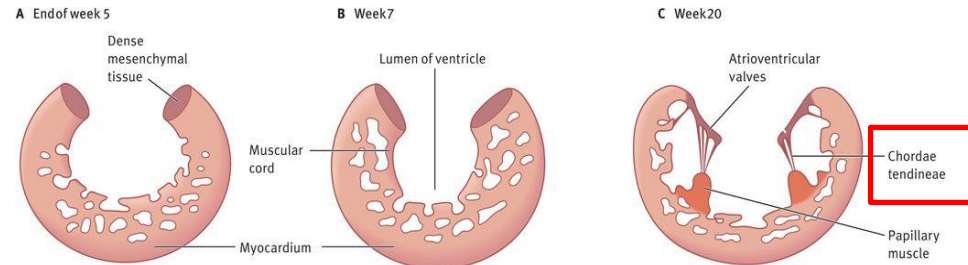
Longitudinal sections through the semilunar valves illustrate successive stages in the hollowing (shown by arrows) and thinning of the valve swellings to form valve cusps.



# POSITIONING AND INTERNAL STRUCTURE

## CHORDAE TENDINEAE AND PAPILLARY MUSCLE:

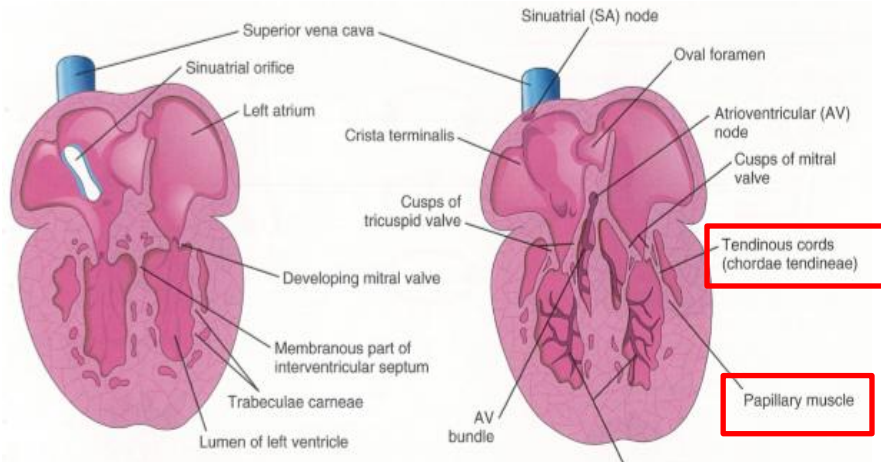
- process of cavitation in the ventricular walls forms a sponge – like mass of muscular bundles
- some bundles remain as the trabecula carnea
- other bundles become the papillary muscles and tendinous cords



The atrioventricular orifice is surrounded by local proliferations of mesenchymal tissue. The tissue on the ventricular surface of these proliferations thins and forms valves, which remain attached to the ventricular

wall by muscular cords. The muscular tissue in the cords degenerates by week 20 and is replaced by dense connective tissue forming chordae tendineae, which now connect valves with the papillary muscles.

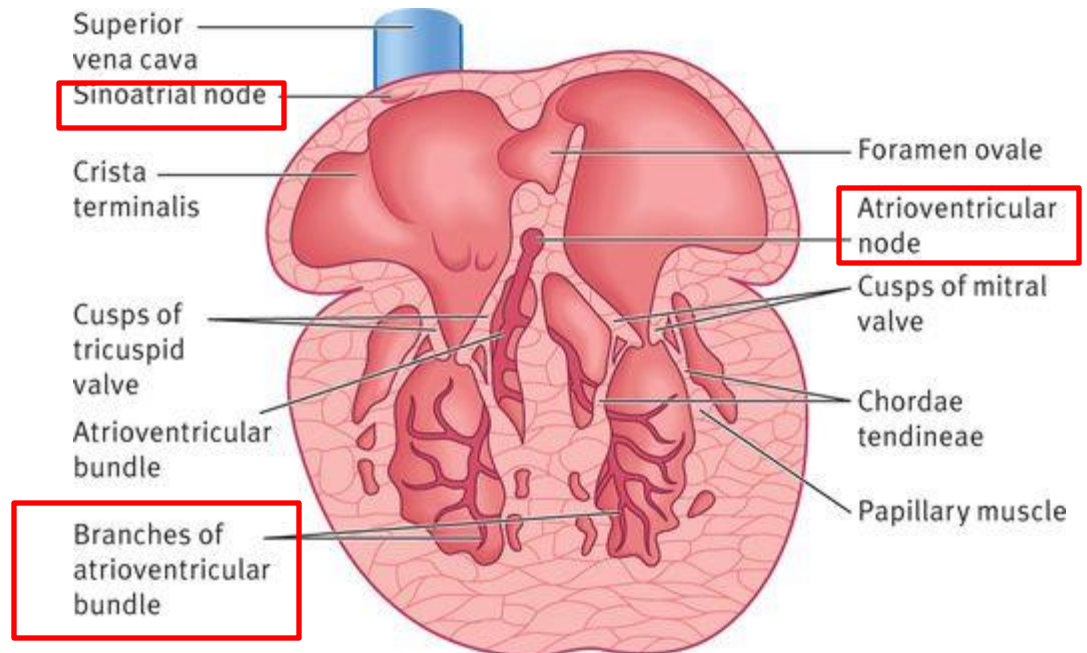
<https://obgynkey.com/development-of-the-heart-and-the-fetal-circulation/>



# POSITIONING AND INTERNAL STRUCTURE

## CONDUCTING SYSTEM OF THE HEART:

- the muscle layers of the atrium and the ventricle are continuous
- the primordial atrium acts as the interim pacemaker of the heart
- but the sinus venosus soon takes over this function

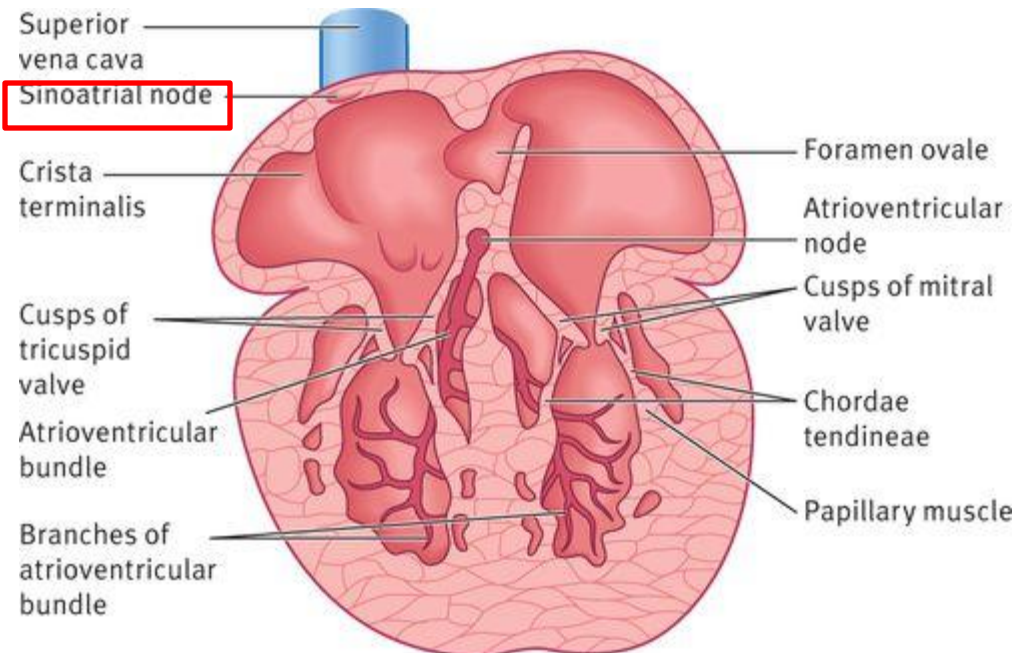


# POSITIONING AND INTERNAL STRUCTURE

## CONDUCTING SYSTEM OF THE HEART:

### a. the sinuatrial node:

- develops during the 5th week
- located near the entrance of the cranial vena cava

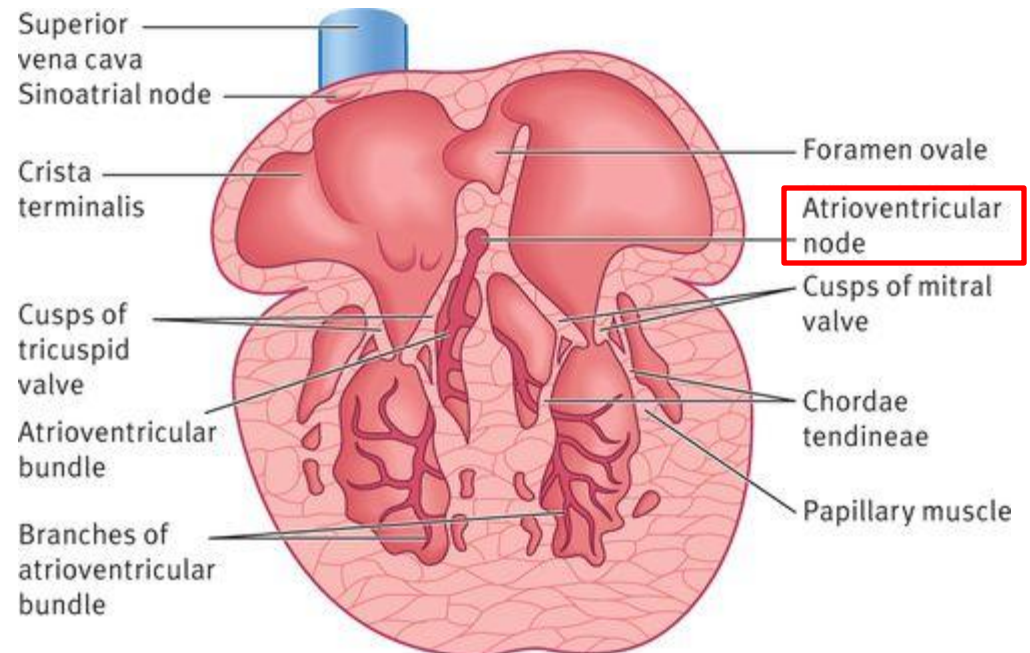


# POSITIONING AND INTERNAL STRUCTURE

## CONDUCTING SYSTEM OF THE HEART:

### b. atrioventricular (AV) node:

- after incorporation of the sinus venosus into the heart
- cells from the left wall of the sinus venosus found in the base of the interatrial septum, near the opening of the coronary sinus – form the AV node

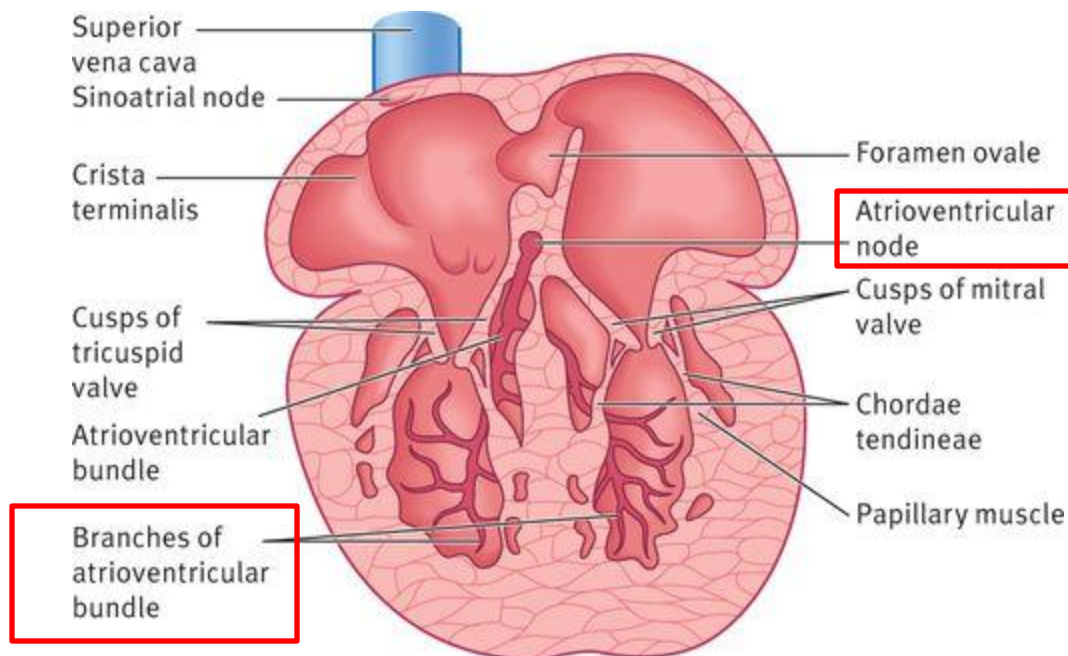


# POSITIONING AND INTERNAL STRUCTURE

## CONDUCTING SYSTEM OF THE HEART:

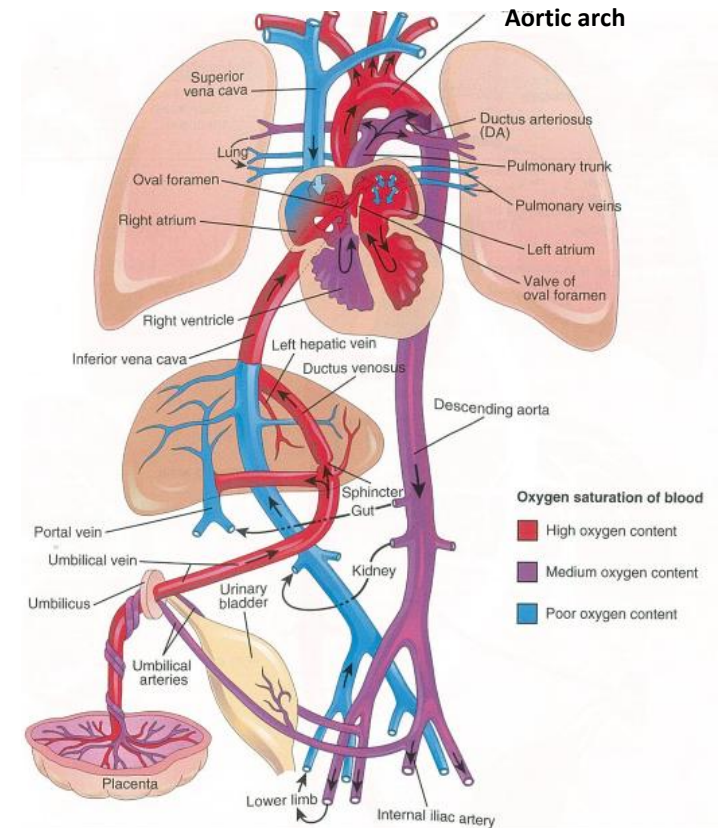
### b. atrioventricular (AV) node:

- the fibers arising from the AV node pass from the atrium into the ventricle and split into right and left bundle branches – Tawara - fibers
- the Tawara fibers distributed throughout the ventricular myocardium



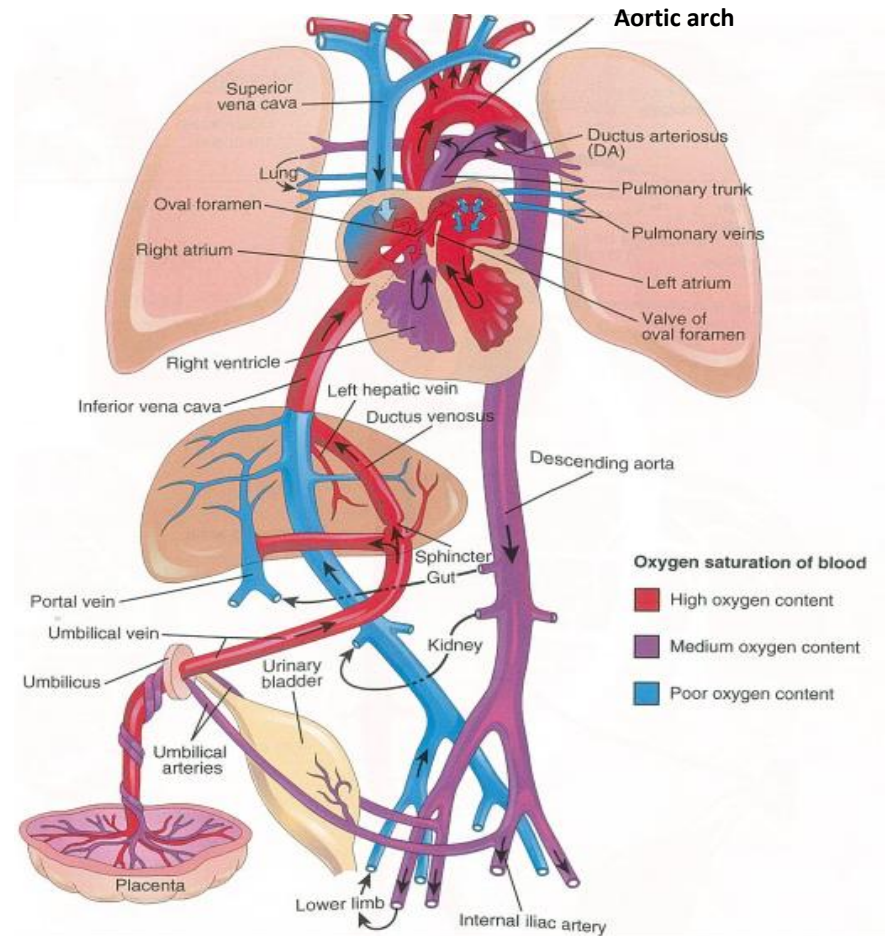
# FETAL CIRCULATION

1. **highly oxygenated, nutrient – rich blood** returns under high pressure from the placenta **in the umbilical vein**
2. on approaching the liver , approx. one half of the blood passes directly into the ductus venosus – a fetal vessel connecting the umbilical vein to the caudal vena cava – this blood bypasses the liver
3. the other half of the blood in the umbilical vein flows into the sinusoids of the liver and enters the caudal vena cava via the hepatic veins



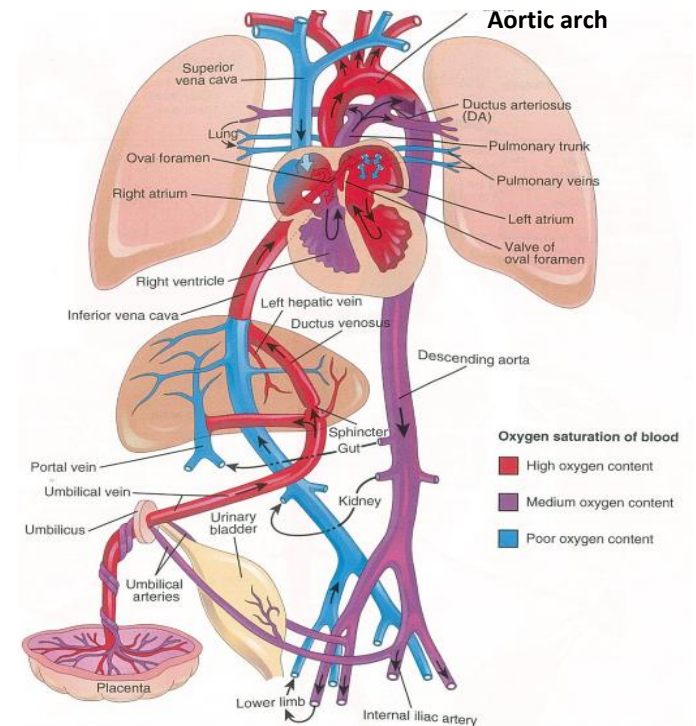
# FETAL CIRCULATION

1. blood in the caudal vena cava enters the right atrium
2. most blood from the caudal vena cava directed by the inferior border of the septum secundum (crista dividens) through the oval foramen into the left atrium



# FETAL CIRCULATION

6. In left atrium the blood mixes with the relatively small amount of poorly oxygenated blood returning from the lungs through the pulmonary veins
7. fetal lungs use the oxygen from the blood instead of replenishing it
8. from the left atrium the blood passes to the left ventricle and leaves through the ascending aorta
9. the arteries of the heart, head, neck and upper limbs receive well – oxygenated blood from the umbilical vein



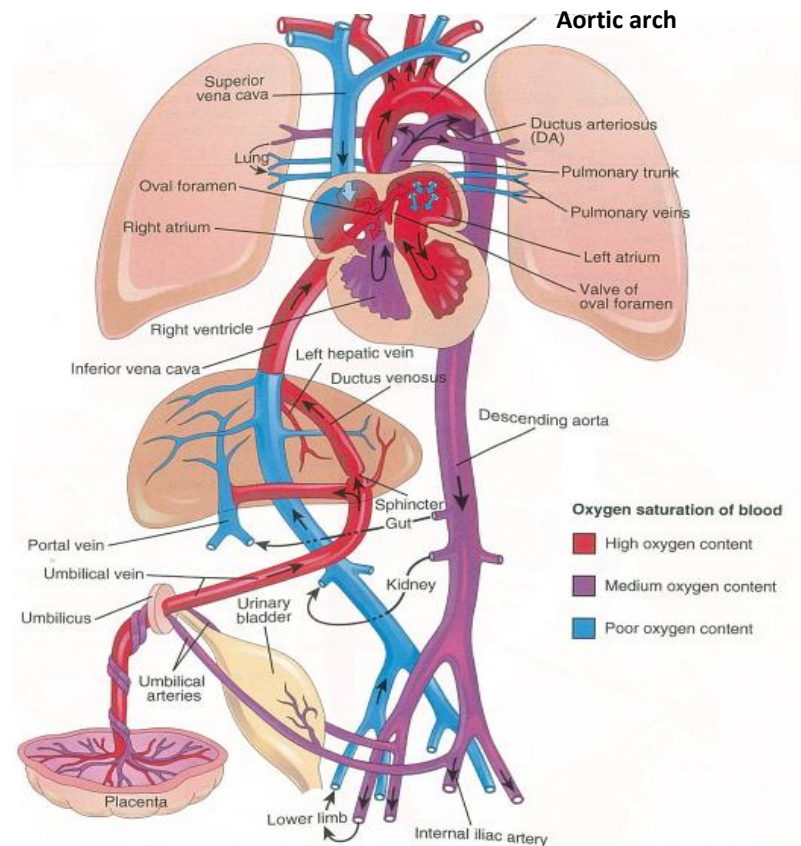
# FETAL CIRCULATION

10. the liver receives well – oxygenated blood from the umbilical vein

11. the small amount of well – oxygenated blood from the caudal vena cava that remains in the right atrium

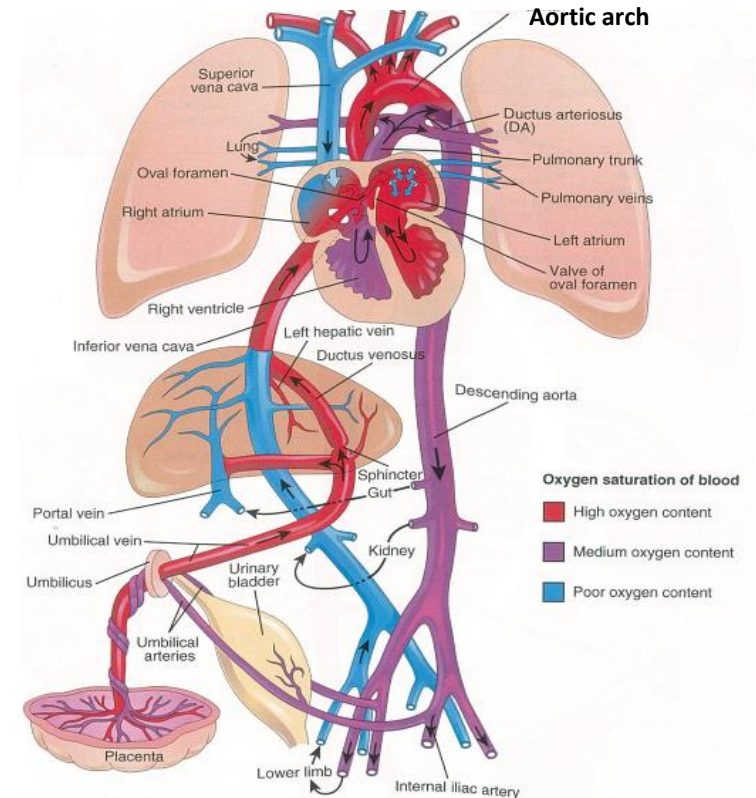
mixes with the poorly oxygenated blood from the cranial vena cava and the coronary sinus and passes into

the right ventricle



# FETAL CIRCULATION

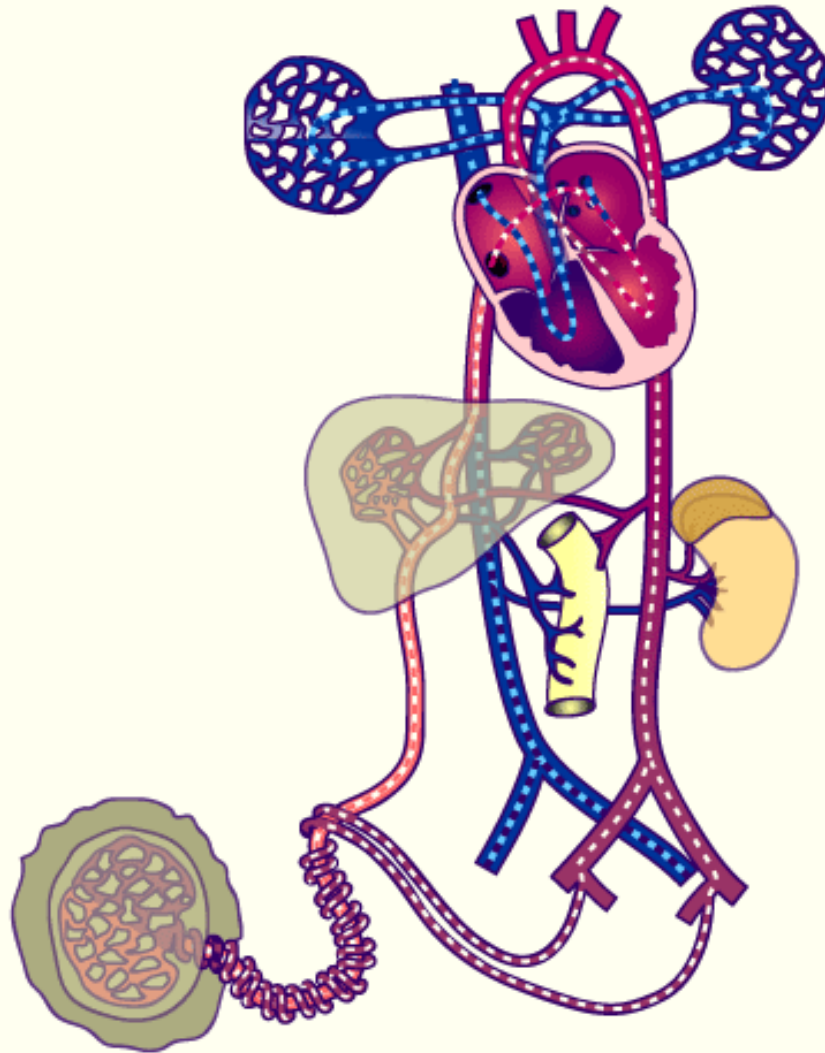
12. this blood with medium oxygen content leaves the right ventricle through the pulmonary trunk
13. because of the high pulmonary vascular resistance in fetal life, pulmonary blood flow is low
14. approx. 10% of the blood goes to the lungs
15. most of the blood passes through the ductus arteriosus into the aorta to the fetal body





# FETAL CIRCULATION

before birth

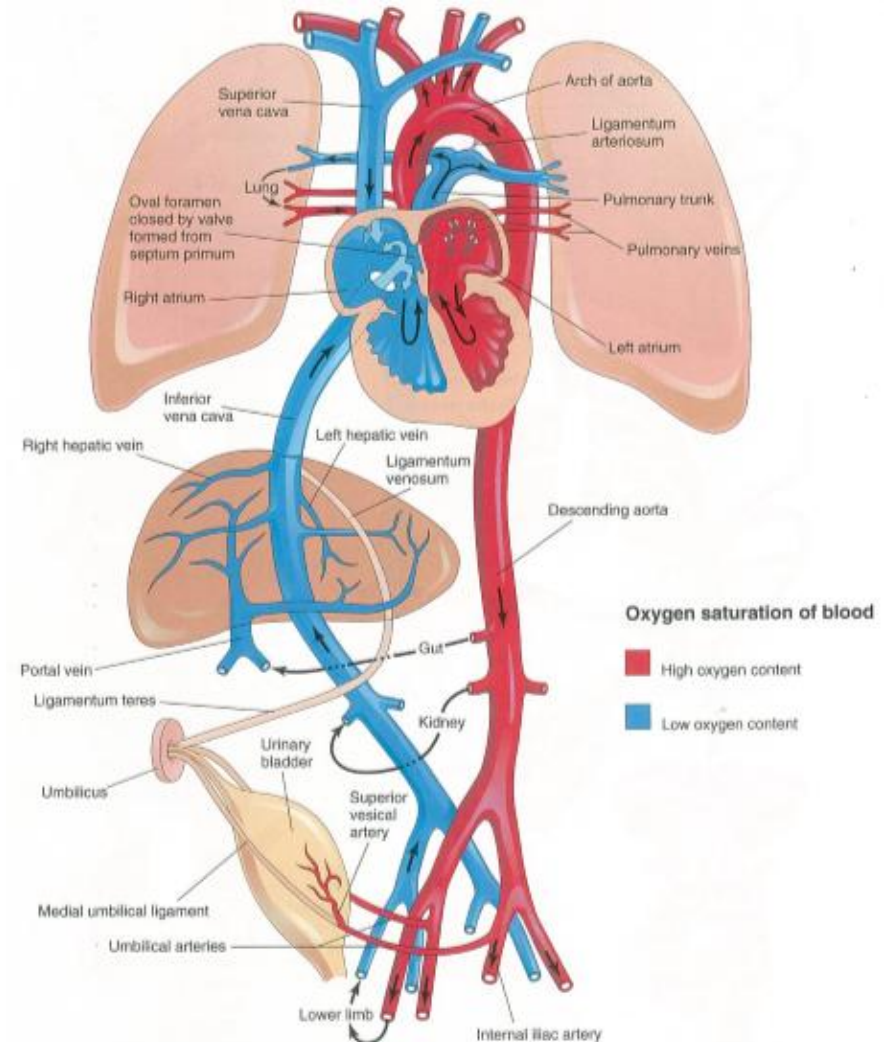


# CHANGES IN CIRCULATION AT BIRTH

- there are three essential changes that take place in the circulation at the time of birth

they involve circulation through:

- a. the lung
- b. the liver
- c. the placenta



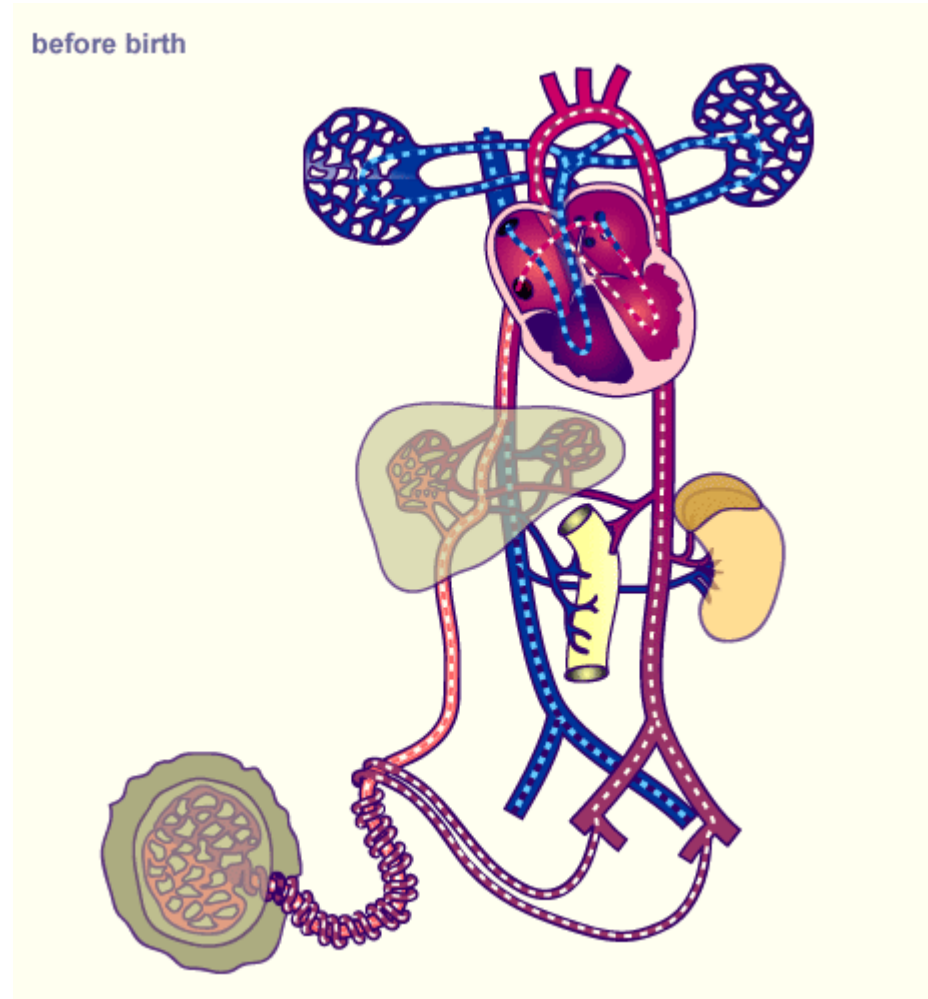
# CHANGES IN CIRCULATION AT BIRTH

important circulatory adjustments occur at birth:

1. the circulation of fetal blood through the placenta ceases
2. the infant's lungs expand and begin to function

as soon as the infant is born the:

- a. oval foramen
- b. ductus arteriosus
- c. ductus venosus
- d. umbilical vessels are no longer needed



# CHANGES IN CIRCULATION AT BIRTH

- a. the sphincter in the ductus venosus constricts – all blood entering the liver passes through the hepatic sinusoids
- b. the placental circulation occludes – that causes an immediate decrease in blood pressure in the caudal vena cava and the right atrium
- c. the pulmonary blood flow increases
- d. the pressure in the left atrium is higher than in the right atrium
- e. the increased left atrial pressure closes the oval foramen by pressing the valve of the foramen against the septum secundum
- f. the output from the right ventricle then flows entirely into the pulmonary circulation
- g. the pulmonary vascular resistance is lower than systemic vascular resistance , when the newborn begins to breathe
- h. blood flow in the ductus arteriosus reverses, passing from the aorta to the pulmonary trunk

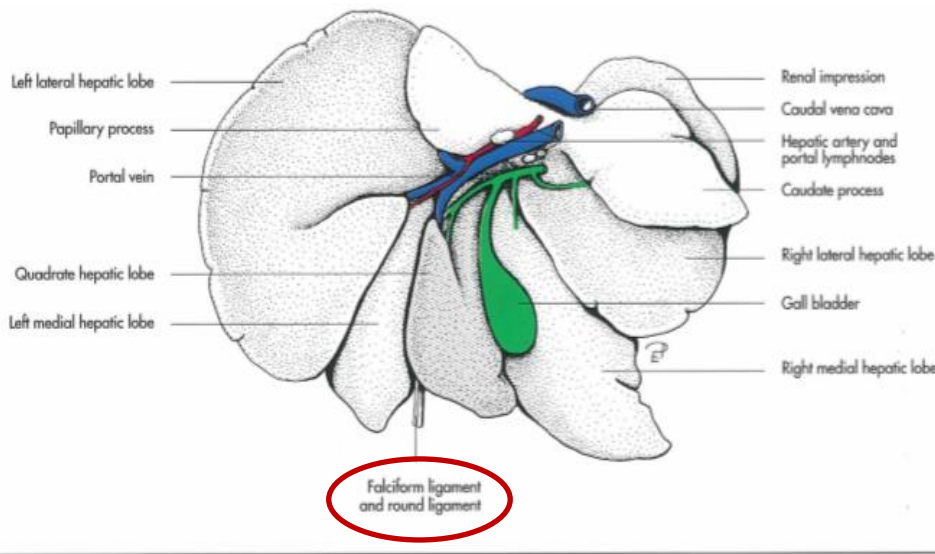
# CHANGES IN CIRCULATION AT BIRTH

- i. the ductus arteriosus begins to constrict at birth , but for a few days is often a small shunt of blood from the aorta to the pulmonary trunk in healthy, full – term infants
- j. the umbilical arteries constrict at birth preventing loss of the infant's blood
- k. the umbilical cord is not tied for a minute – so blood flow through the umbilical vein continues, transferring fetal blood from the placenta to the infant

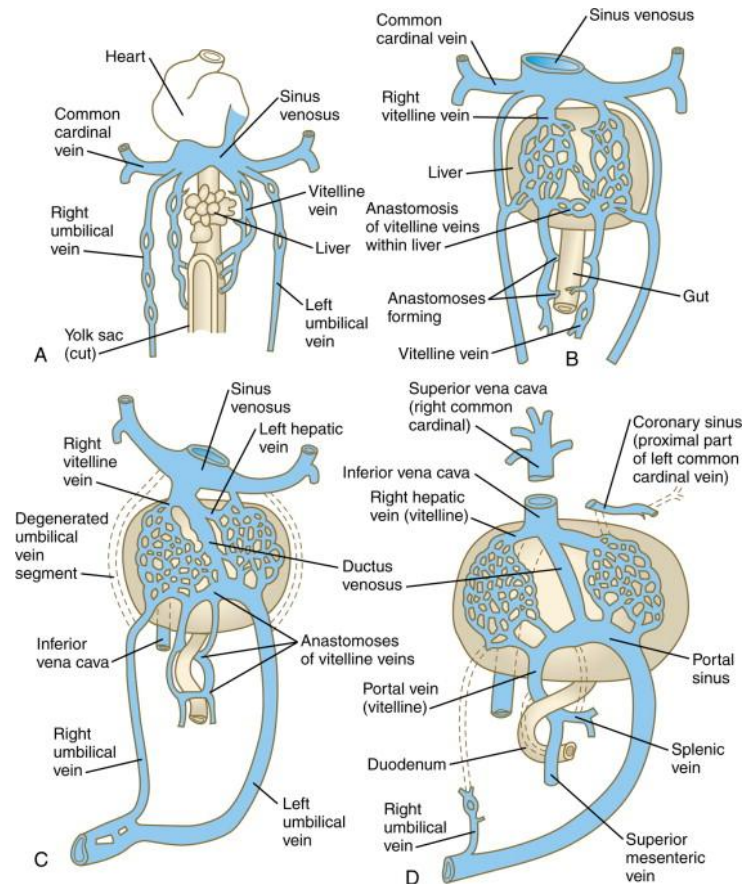
# DERIVATIVES OF FETAL VASCULAR STRUCTURES

## UMBILICAL VEIN AND ROUND LIGAMENT OF THE LIVER (ligamentum teres hepatis):

- the intra – abdominal part of the umbilical vein becomes the round ligament of the liver
- the umbilical vein remains patent for a considerable period and may be used for blood transfusions during early infancy



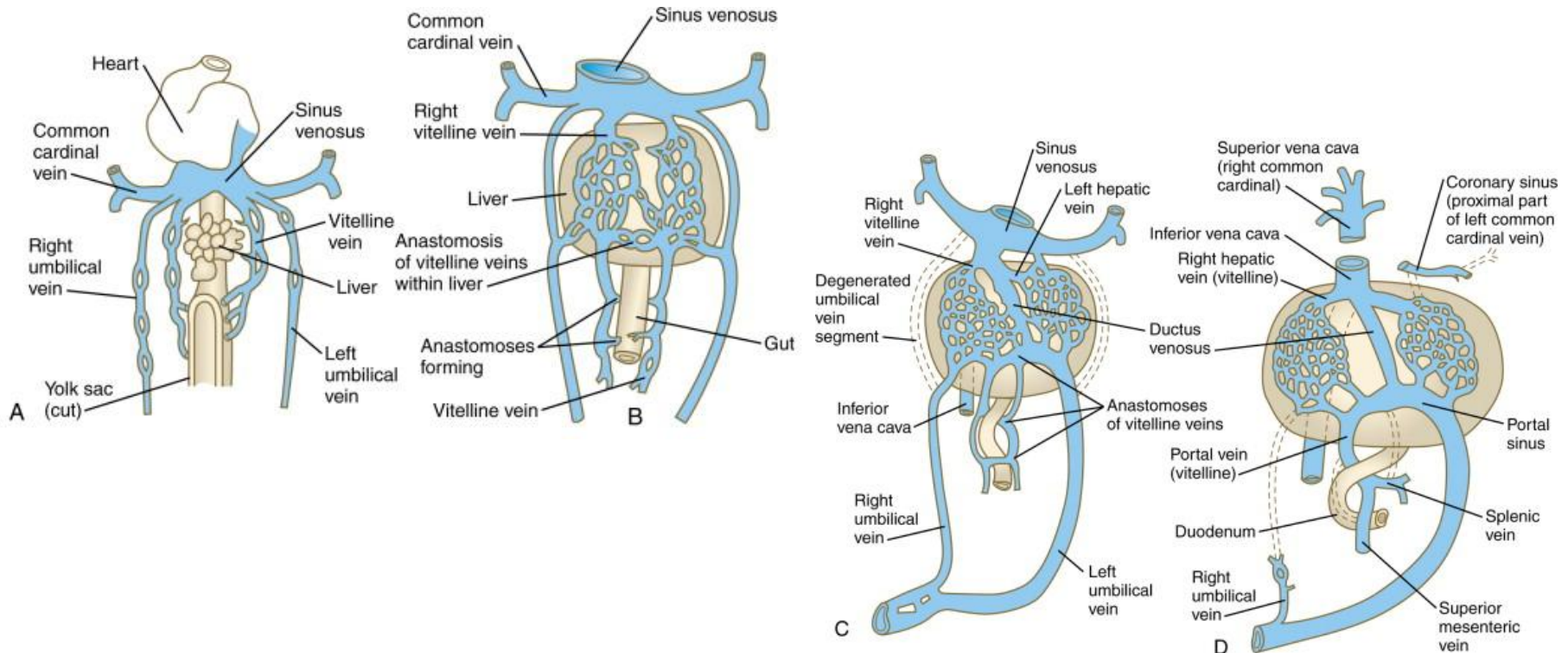
ig 7-97. Liver of the dog, schematic, visceral surface.



# DERIVATIVES OF FETAL VASCULAR STRUCTURES

## DUCTUS VENOSUS AND LIGAMENTUM VENOSUM :

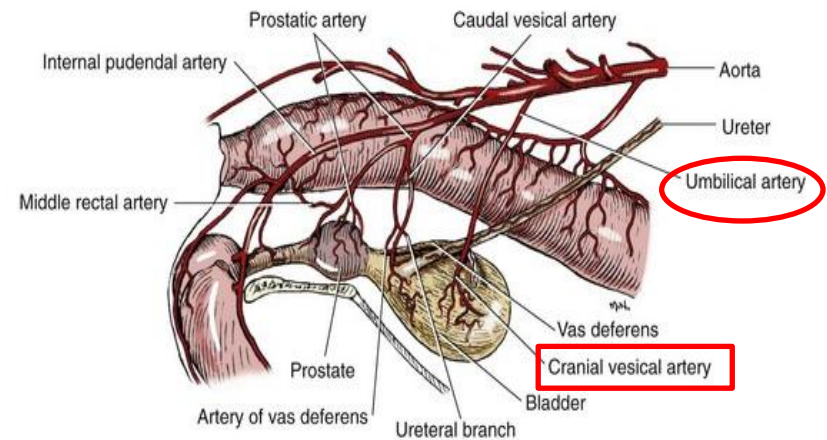
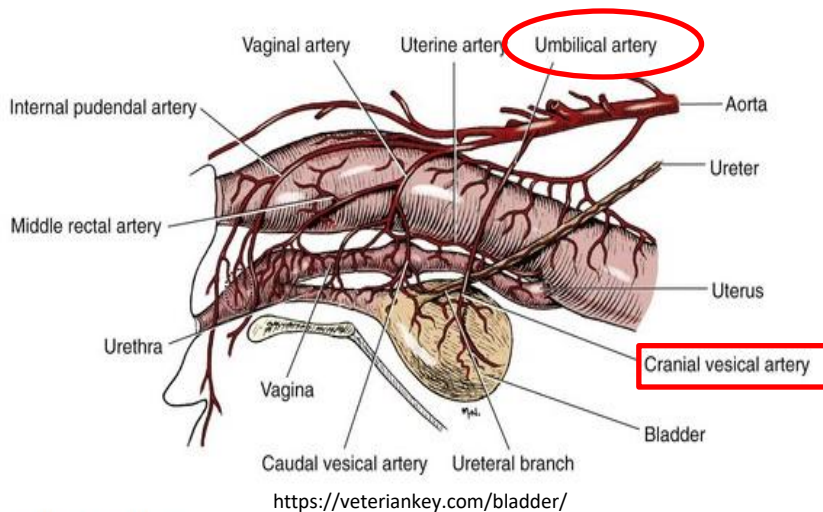
- the ductus venosus becomes the ligamentum venosum
- the ligamentum venosum passes through the liver from the left branch of the portal vein to the caudal vena cava to which is attached



# DERIVATIVES OF FETAL VASCULAR STRUCTURES

## UMBILICAL ARTERIES AND ABDOMINAL LIGAMENTS:

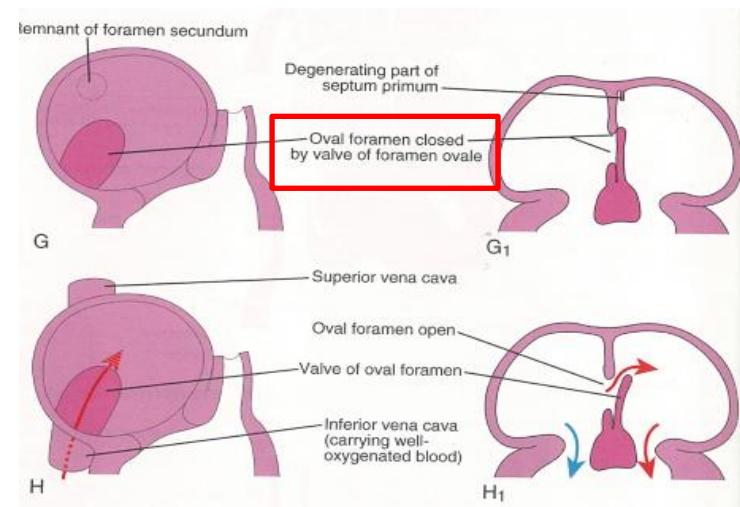
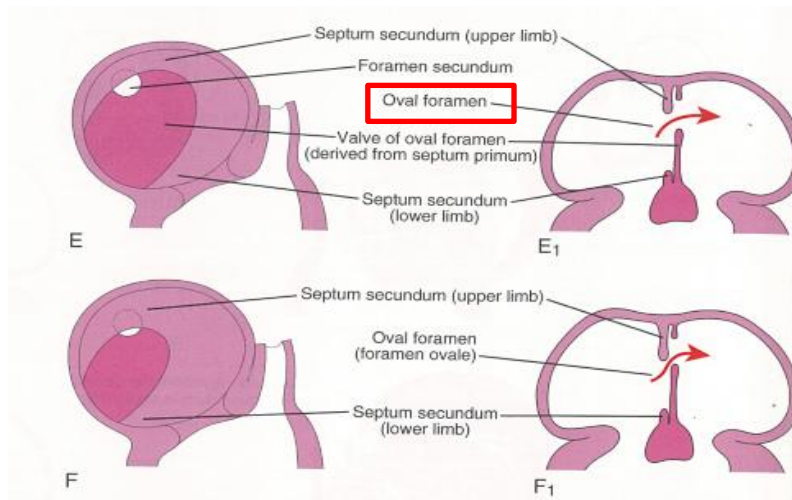
- remnants of the umbilical arteries are the round ligament of the bladder , which extend from the urinary bladder to the umbilicus
- the proximal parts of the arteries remain patent and are part of the blood supply to the bladder in the adult
- the patent part extends from the internal iliac arteries to the urinary bladder



# DERIVATIVES OF FETAL VASCULAR STRUCTURES

## OVAL FORAMEN AND OVAL FOSSA:

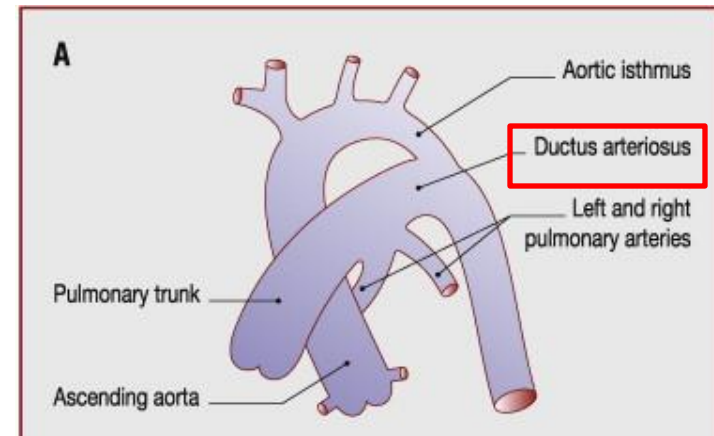
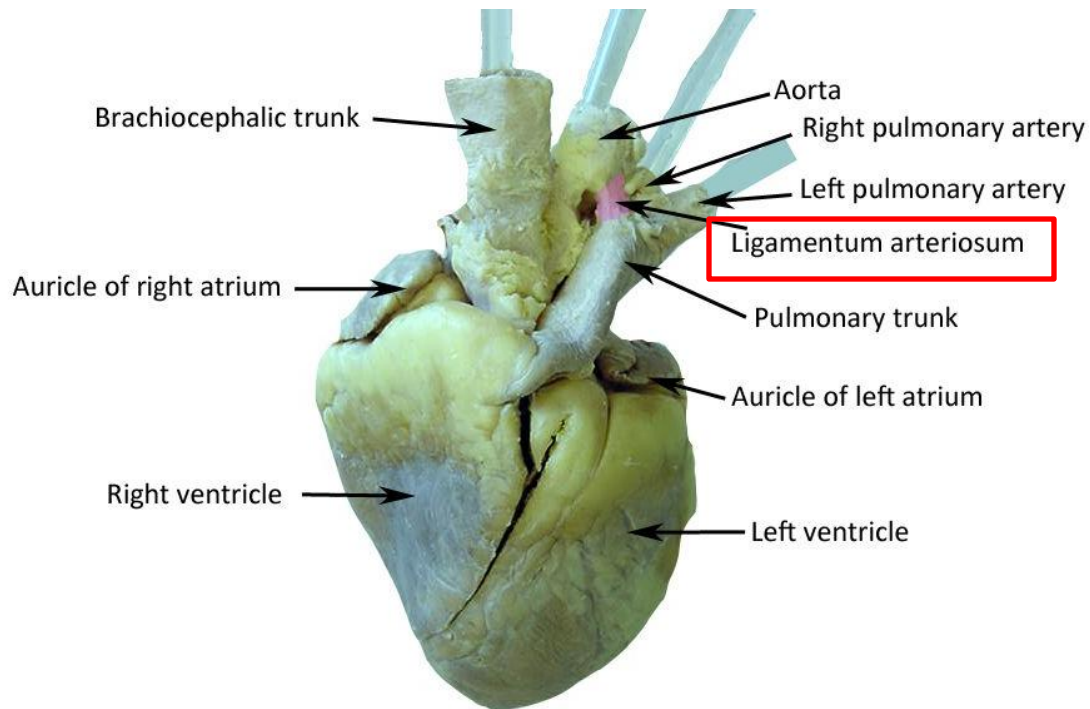
- the oval foramen closes functionally at birth
- the vestige of the foramen ovale is the fossa ovale
- the septum primum forms the floor of the oval fossa
- the inferior edge of the septum secundum forms a rounded fold – the border of the oval fossa (limbus foraminis ovalis)
- the closure results adhesion of the septum primum to the left margin of the septum secundum



# DERIVATIVES OF FETAL VASCULAR STRUCTURES

## DUCTUS ARTERIOSUS BOTALLI AND LIGAMENTUM ARTERIOSUM:

- functional closure of the ductus arteriosus is completed 10 to 15 hours after birth
- anatomical closure causes the formation of the ligamentum arteriosum



<https://www.sciencedirect.com/science/article/pii/S1875213610001555>

<https://hu.pinterest.com/pin/496592296404858352/>

# **BIBLIOGRAPHY**

**William K. Latshaw: Veterinary Developmental Anatomy, A Clinically Oriented Approach, 1987**

**T.A. Mcgeady, P.J. Quinn, E.S. FitzPatrick and M.Z. Ryan: Veterinary Embryology, Blackwell Publishing, 2006**

**Keith L. Morre, T.V.N. Persaud, Mark G. Torchia: before we were Born, Essentials of Embryology and Birth defects, 8th Edition, Elsevier**

**Langhman's Medical Embryology**