

ARTICULATIONES

SYNARTHROSIS

- Articulationes fibrosae
[Syndesmosis]
 - Sutura (*koponyavarratok*)
 - Sutura serrata
 - Sutura squamosa
 - Sutura foliata
 - Sutura plana
 - Gomphosis (*art. dentoalveolaris*)
 - Schindylesis (*vomer – kemény szájpad*)
- Articulationes cartilagineae
[Synchondrosis]
 - Symphysis (*pelvis, Ca, Ru: mandibula*)
- Synostosis (*Eq: radius-ulna*)
- Synsarcosis (*mellső végtag - mellkas*)

AMPHIARTHROSIS

(*art. sacroiliaca*)

DIARTHROSIS

[Articulationes synoviales]

Szám szerint

- **Articulatio simplex** (*art. humeri*)
- **Articulatio duplex** (*art. femorotibialis*)
- **Articulatio composita** (*art. cubiti*)

Alak- és tengely szerint

Egytengelyű

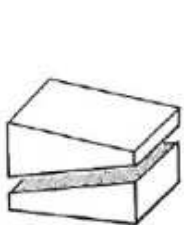
- **Articulatio trochoidea**
(*art. atlantoaxialis, art. radioulnaris prox.*)
- **Ginglymus**
(*art. cubiti, art. metacarpophalangea*)
 - **Articulatio cochlearis**
(*art. tarsocruralis*)
- **Articulatio plana**
(*art. proc. articularium vertebrarium*)
 - **Articulatio delabens**
(*art. femoropatellaris*)

Kéttengelyű

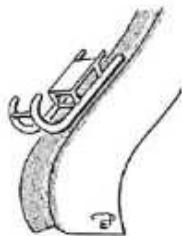- **Articulatio ellipsoidea**
(*art. atlantooccipitalis*)
- **Articulatio sellaris**
(*art. interphalangea prox./dist.*)
- **Articulatio condylaris**
(*art. femorotibialis, art. temporomandibularis*)

Soktengelyű

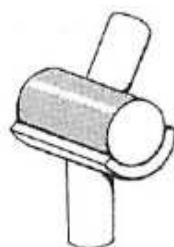- **Articulatio spherioidea**
(*art. humeri, art. coxae*)



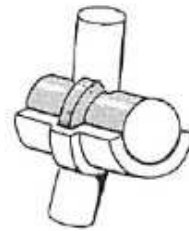
plana




delabens



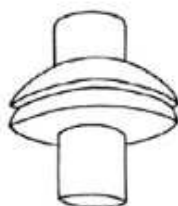ginglymus



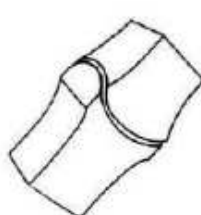
cochlearis



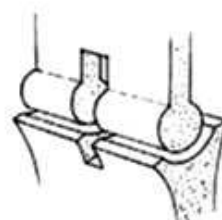
trochoidea



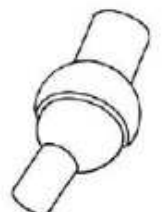ellipsoidea



sellaris



condylaris



spherioidea